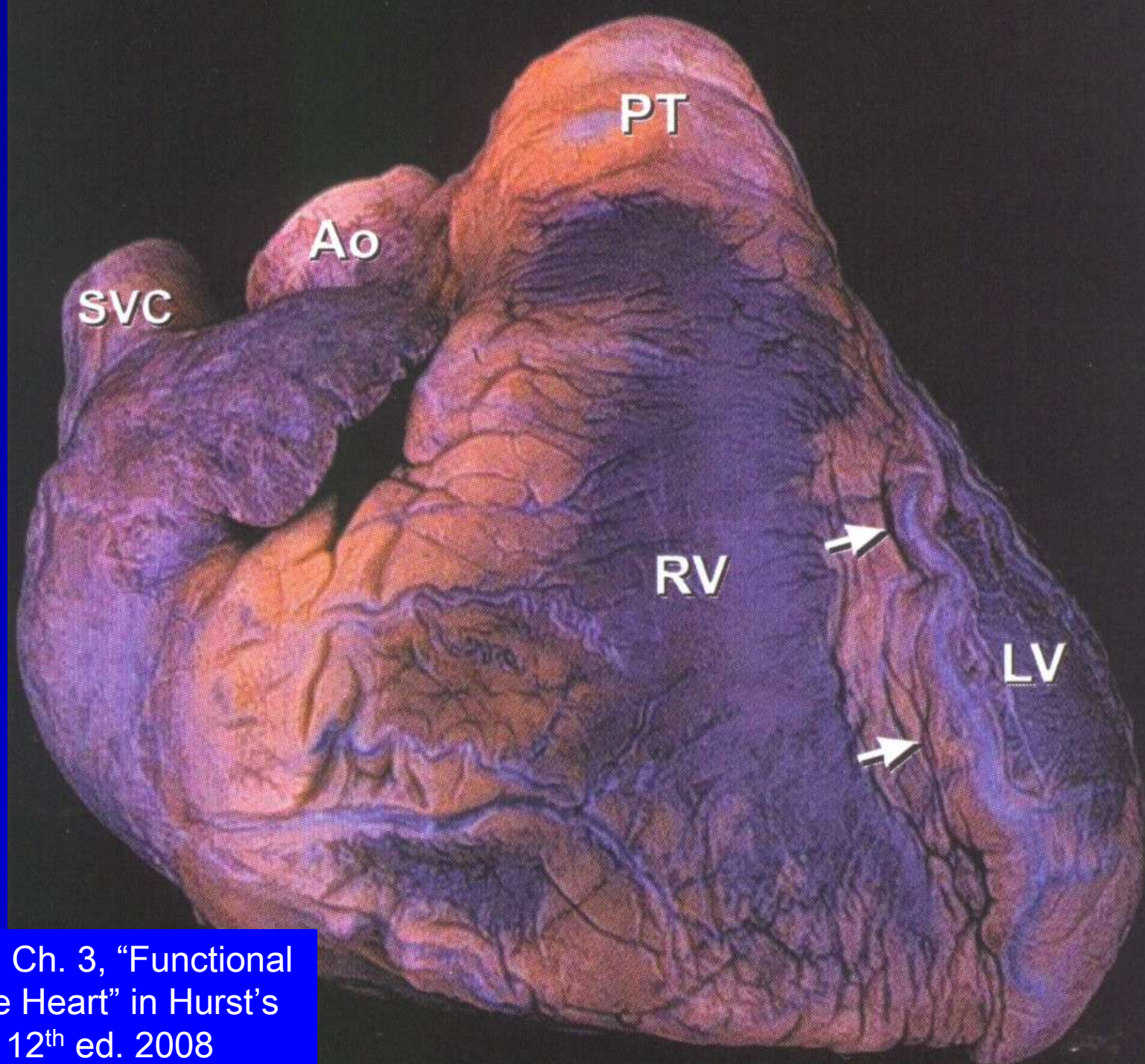


Cardiac Anatomy

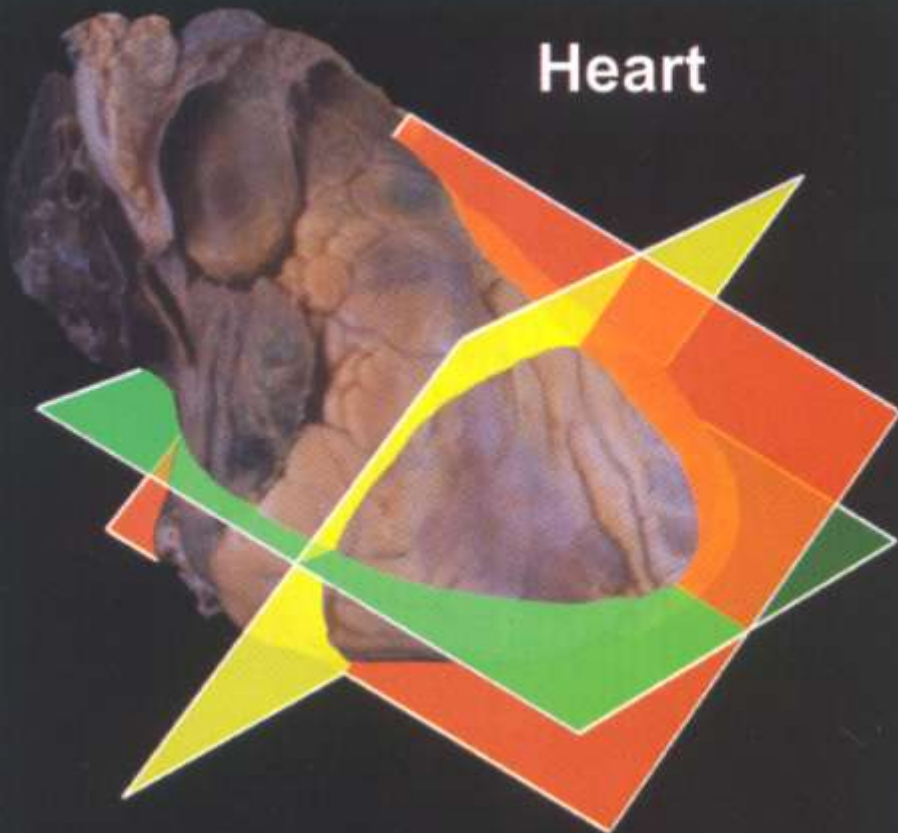2011

Joe M. Moody, Jr, MD
UTHSCSA and STVAHCS

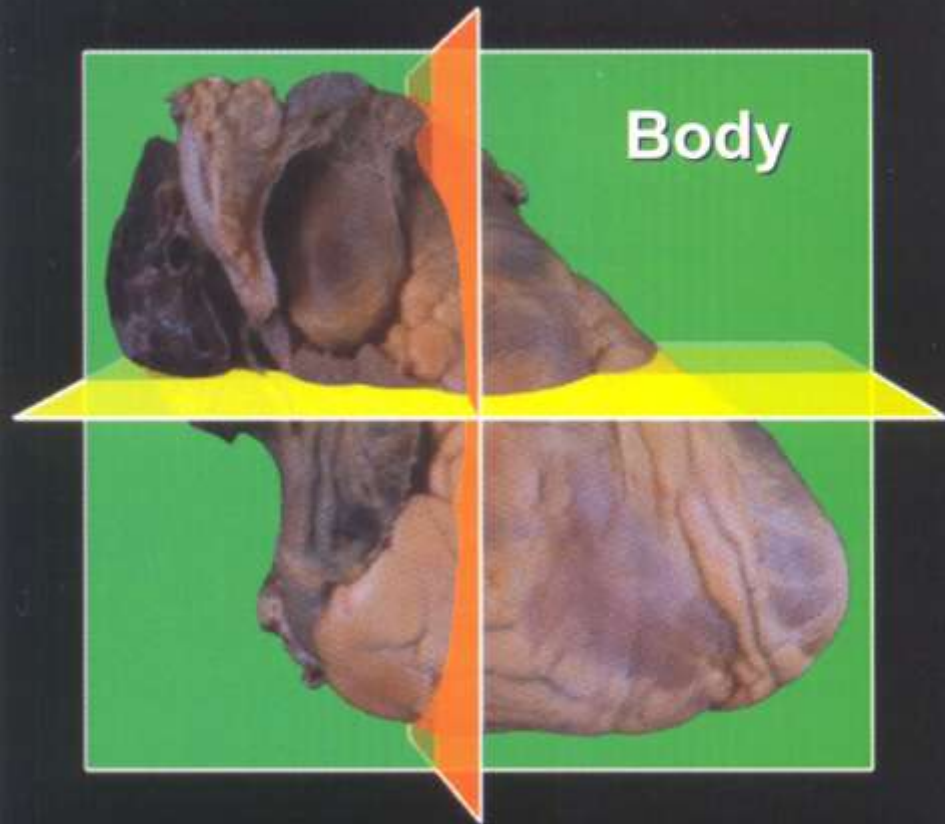


Malouf JF et al. Ch. 3, "Functional
Anatomy of the Heart" in Hurst's
The Heart 12th ed. 2008

Heart

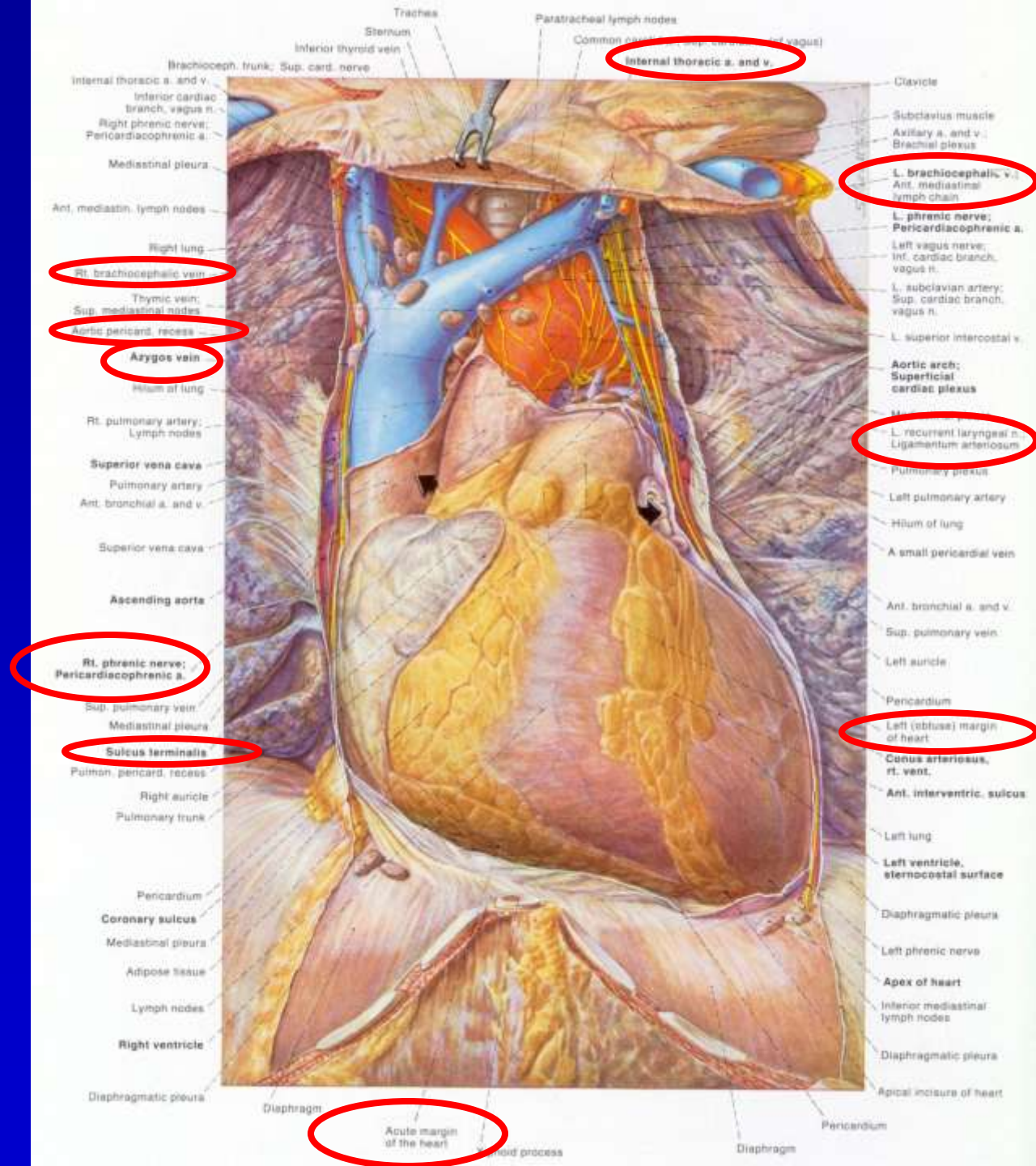


Body



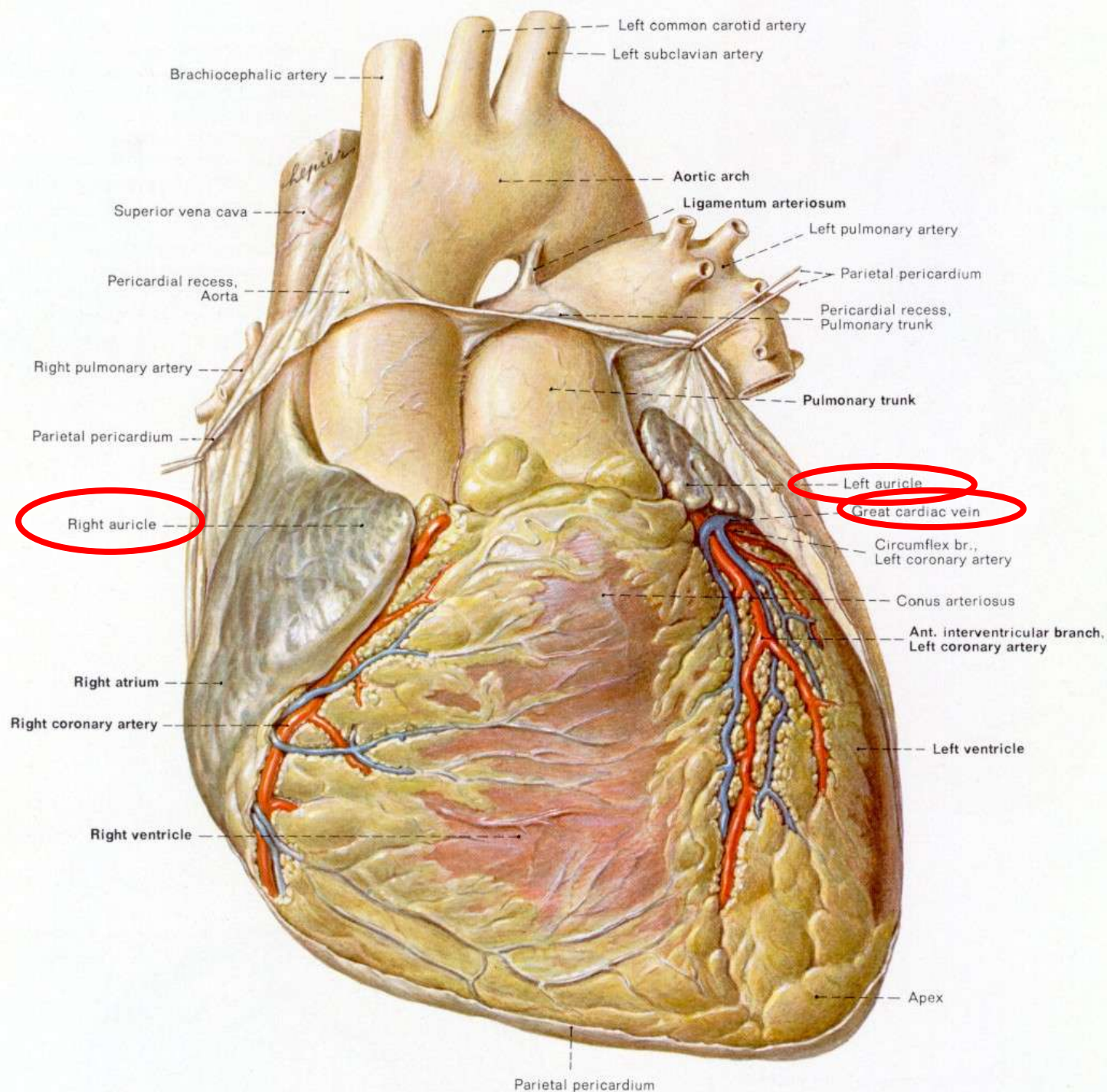
Malouf JF et al. Ch. 3, "Functional
Anatomy of the Heart" in Hurst's
The Heart 12th ed. 2008

Heart In Situ and Pericardium



Clemente CD.
Anatomy
3rd Ed, 1987, fig 188.

Anterior Cardiac Surface



Clemente CD.
Anatomy
3rd Ed, 1987, fig
194.

Topics

- Pericardium
- Veins
 - Systemic (SVC, IVC)
 - Pulmonary (RU, RL, LU, LL)
 - Coronary
- Chambers
 - Atria (R, L)
 - Ventricles (R, L)
- Valves
 - AV (Tricuspid, mitral)
 - Semilunar (Pulmonary, aortic)
- Arteries
 - Pulmonary
 - Systemic
 - Coronary

Pericardium

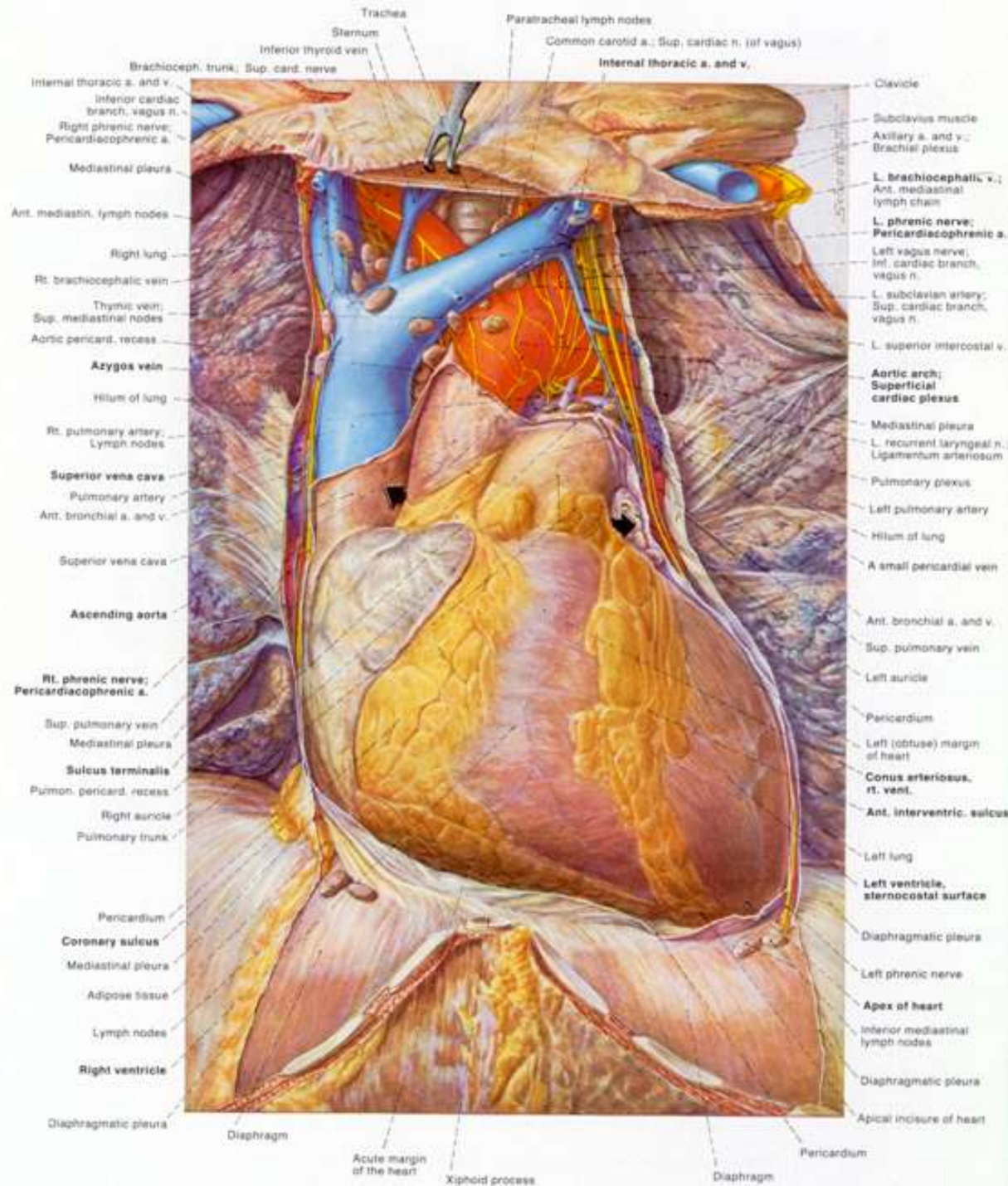
Heart In Situ and Pericardium

Transverse pericardial sinus shown by arrows

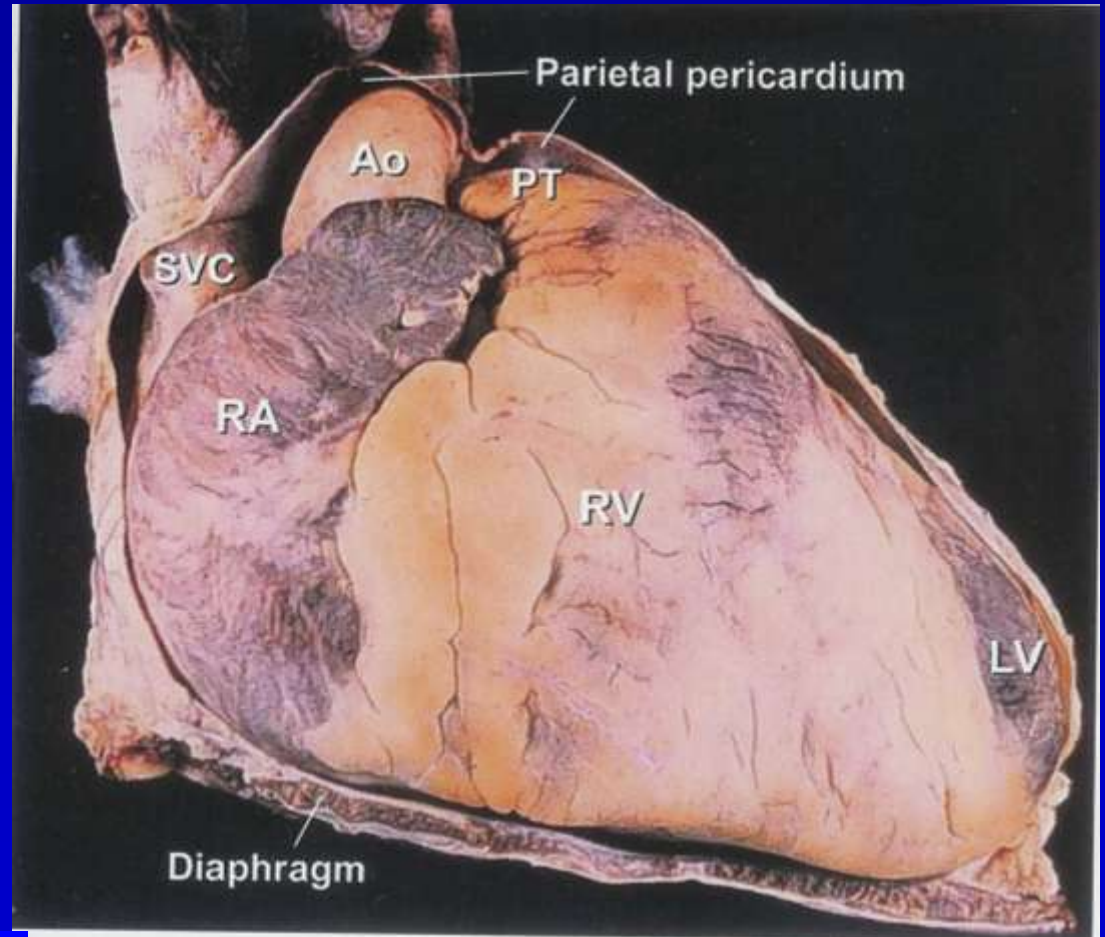
Visceral pericardium is simply epicardium

Parietal pericardium is fibrous

Clemente CD. Anatomy
3rd Ed, 1987, fig 212.



Pericardium



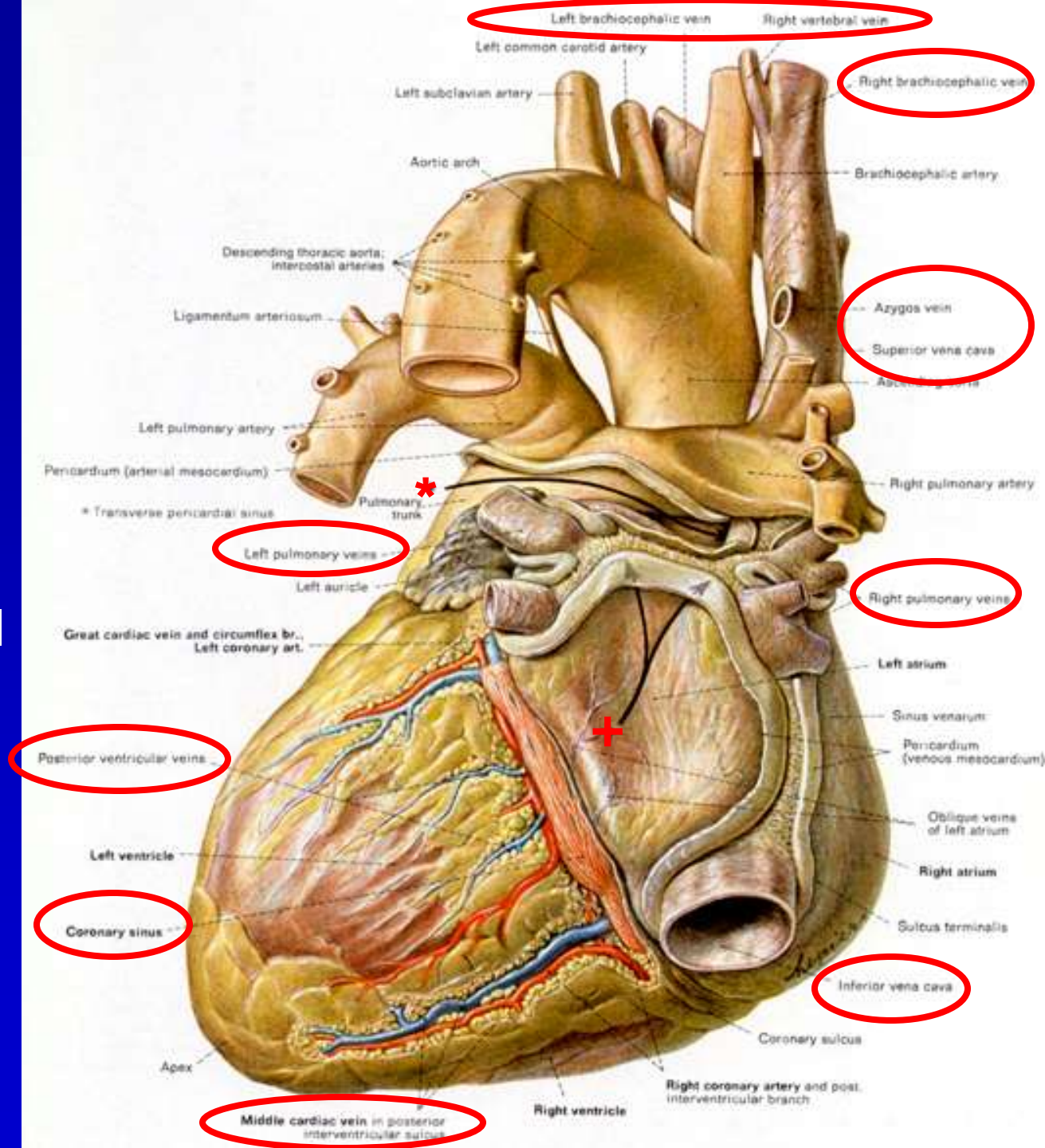
Malouf JF et al. Ch. 3, "Functional Anatomy of the Heart" in Hurst's The Heart 12th ed. 2008

Veins

Posterior Surface of Heart

Transverse pericardial sinus shown by *

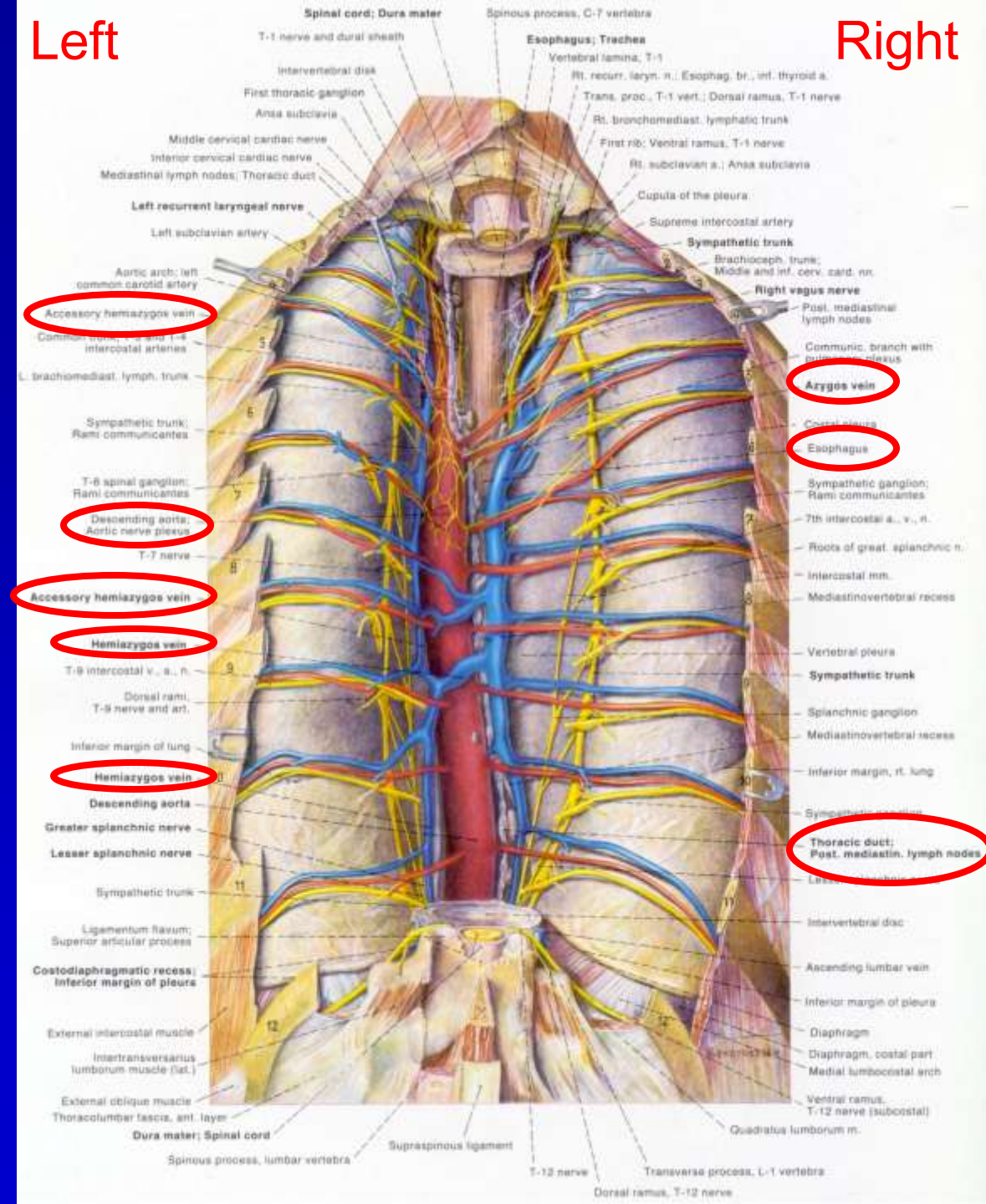
Oblique pericardial sinus shown by +



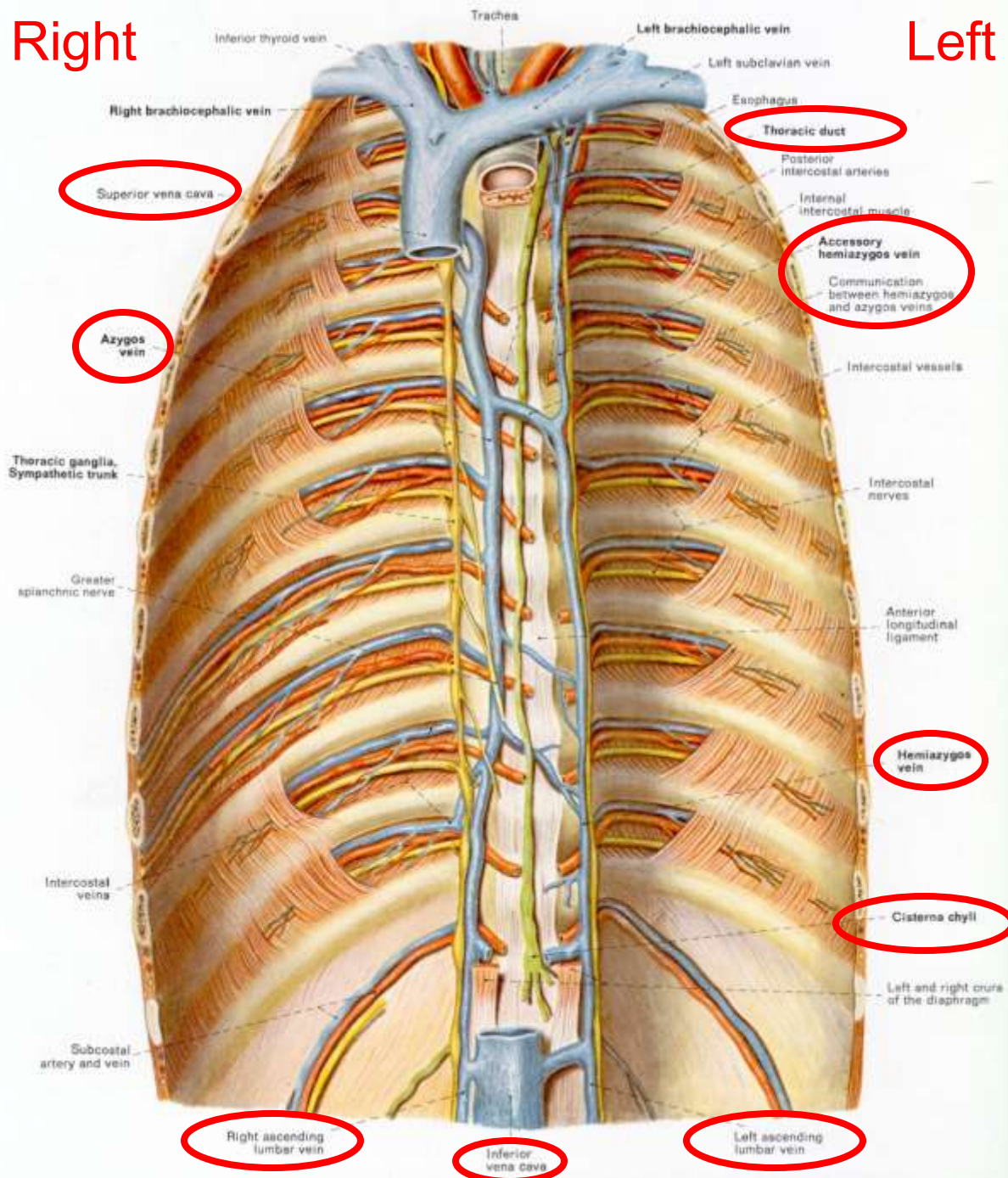
Veins of Thorax, Posterior View

Left

Right

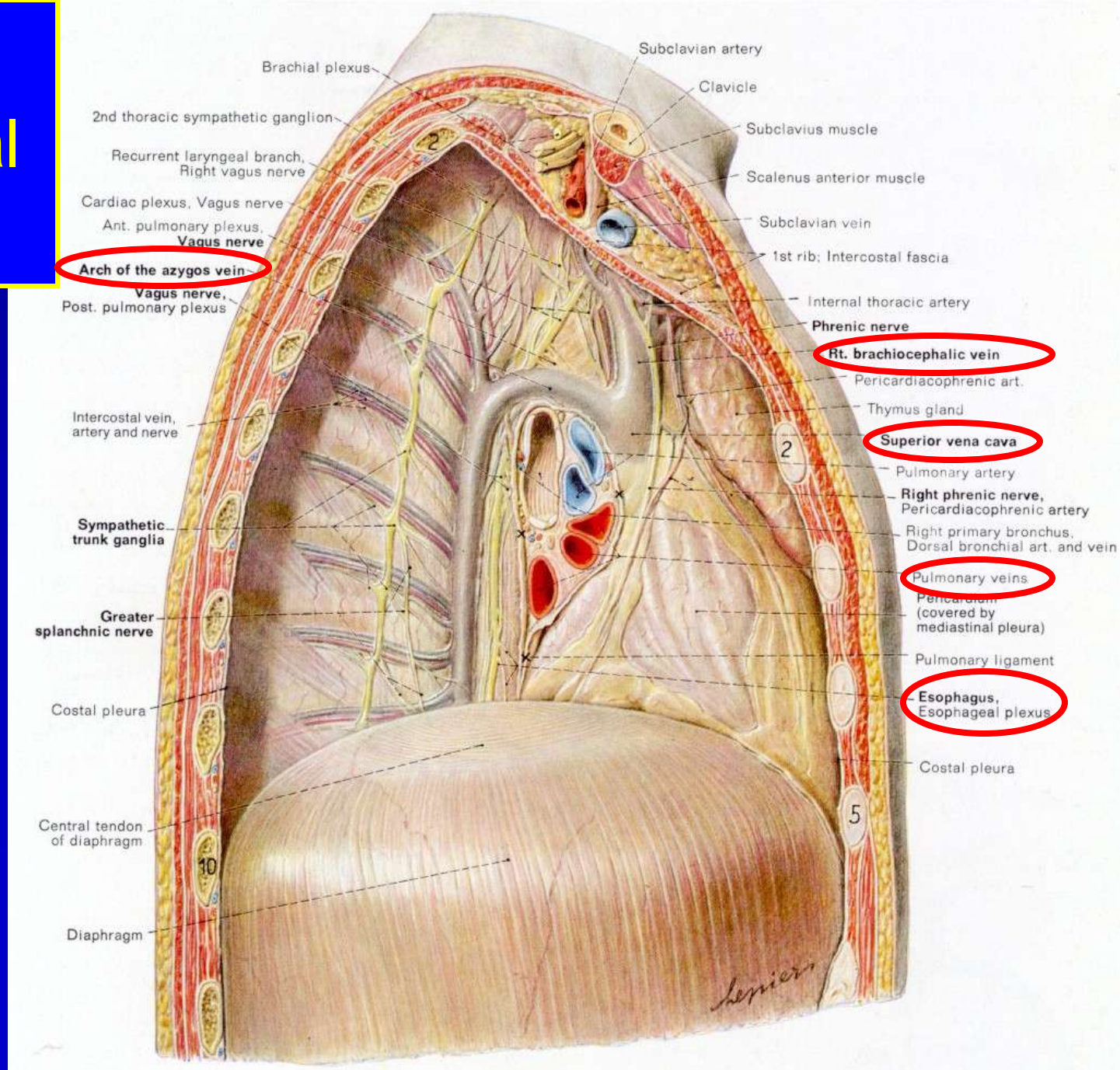


Azygous Veins



Clemente CD. Anatomy
3rd Ed, 1987, fig 221.

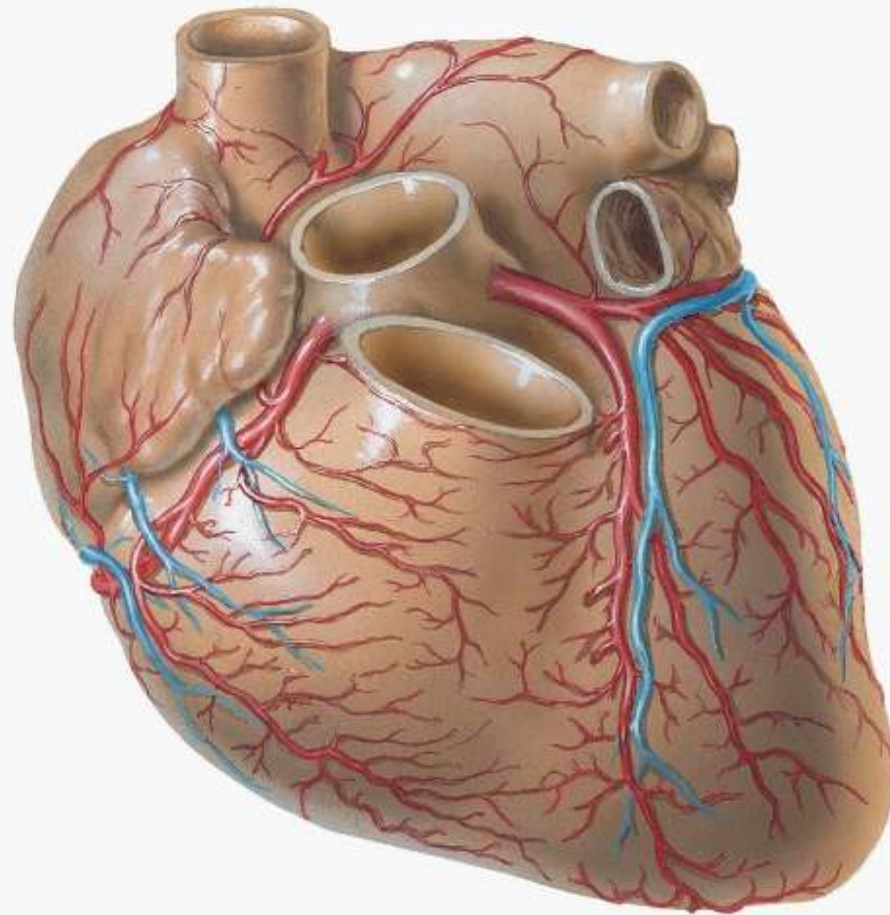
Right Mediastinal Surface



Clemente CD.
Anatomy
3rd Ed, 1987,
fig 184.

Coronary Arteries and Cardiac Veins

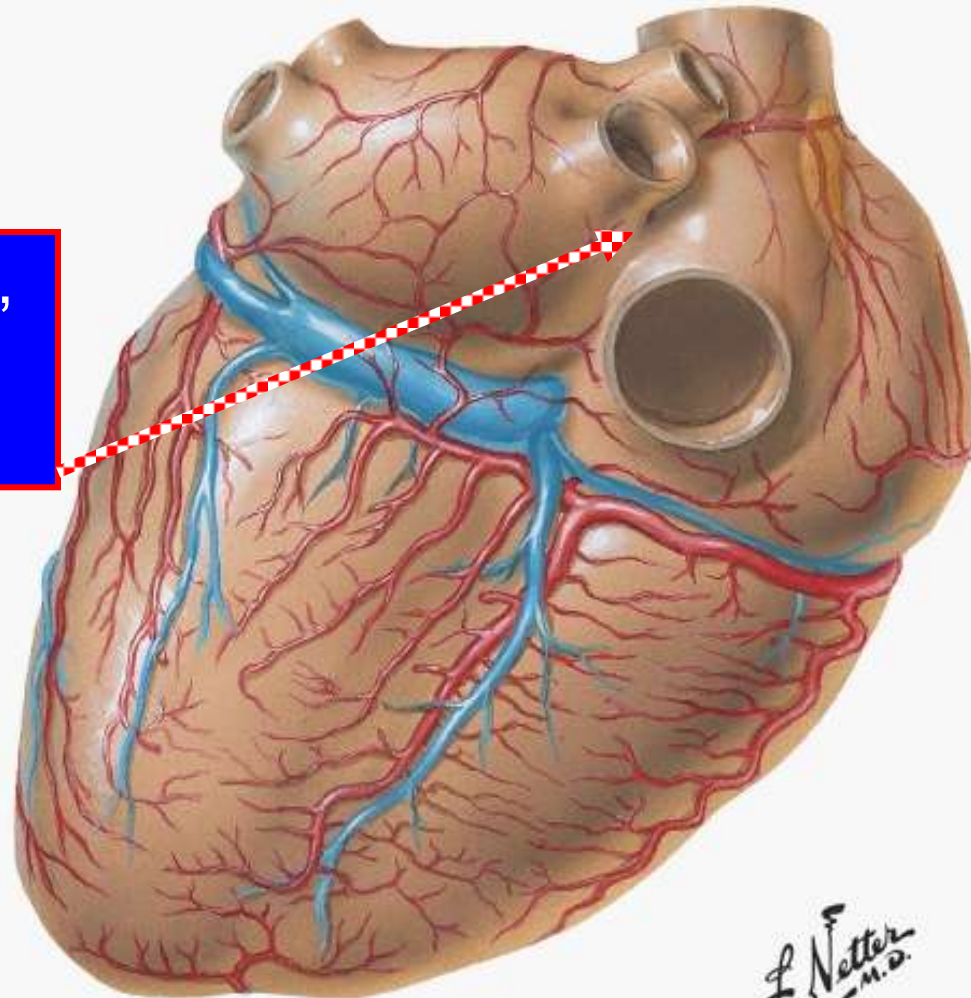
Sternocostal Surface



Coronary Arteries and Cardiac Veins

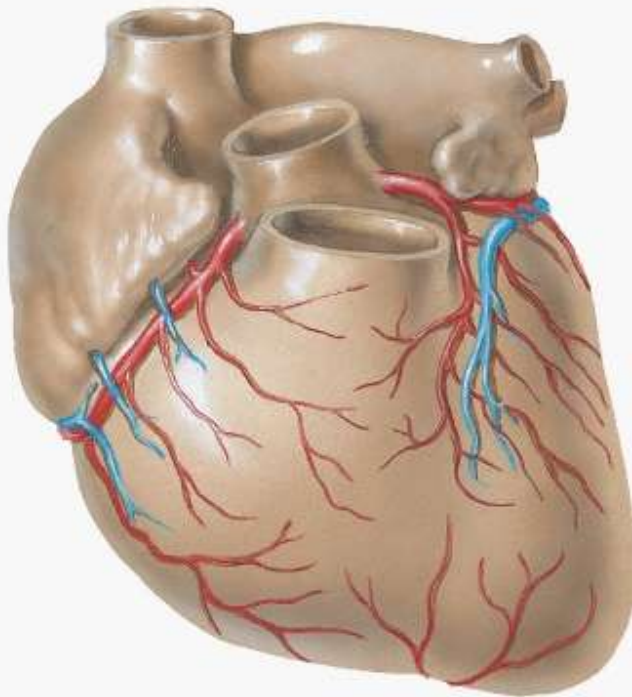
Diaphragmatic Surface

Sondegaard's Groove,
Waterston's groove,
interatrial groove

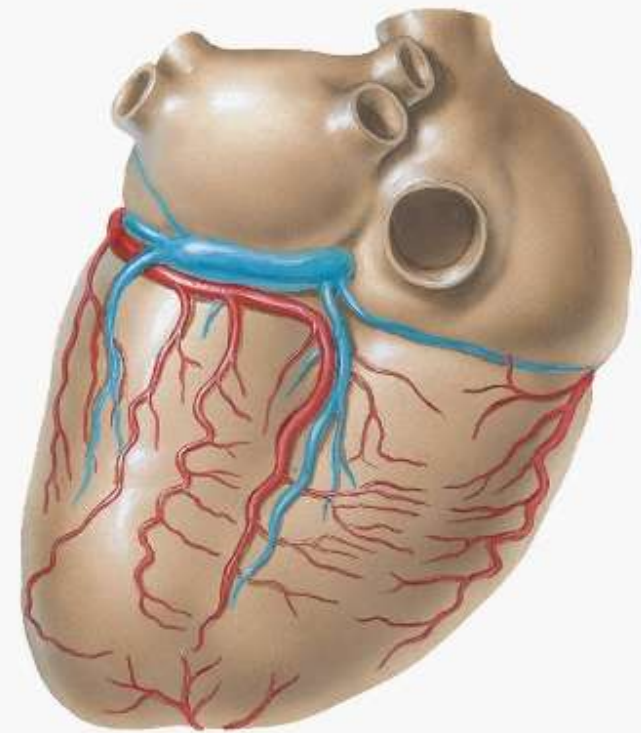


Coronary Arteries and Cardiac Veins

Variations

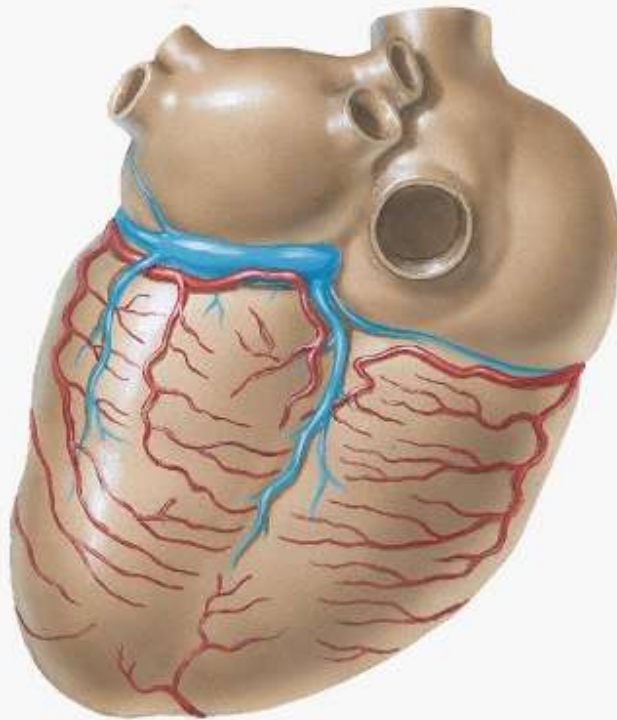


Small LAD



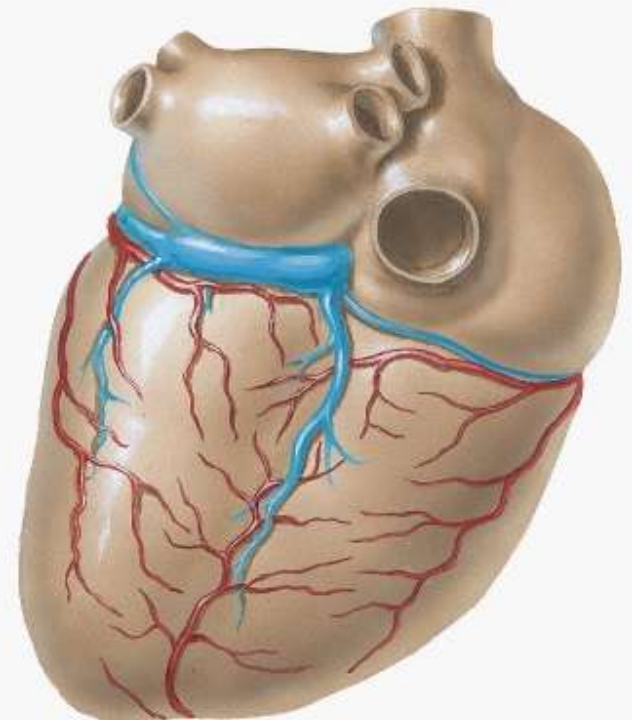
**Dominant LCX
(left-dominant)**

Coronary Arteries and Cardiac Veins Variations



Dominant LAD

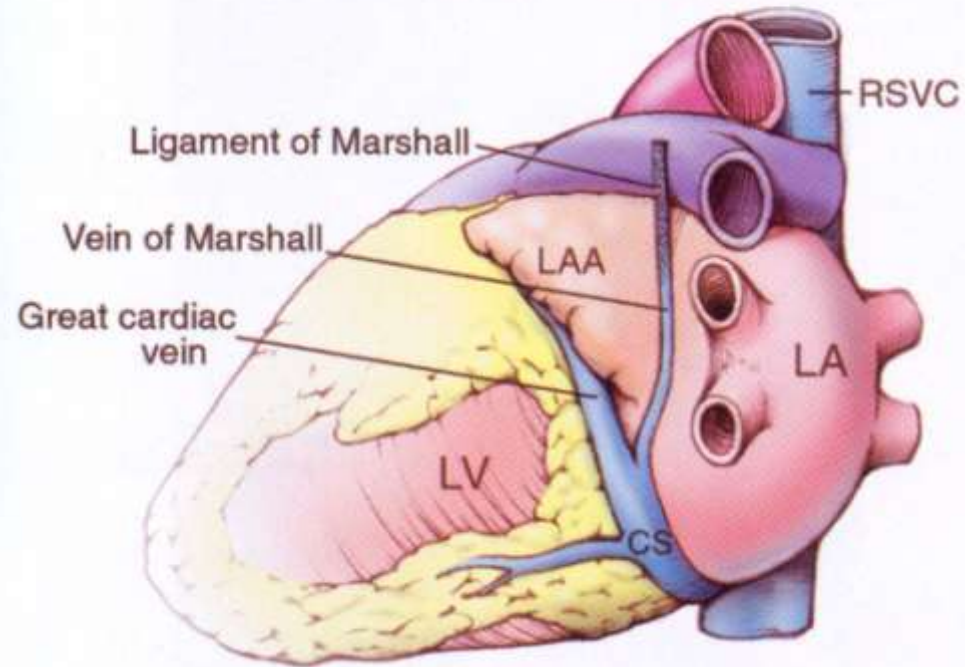
No PDA



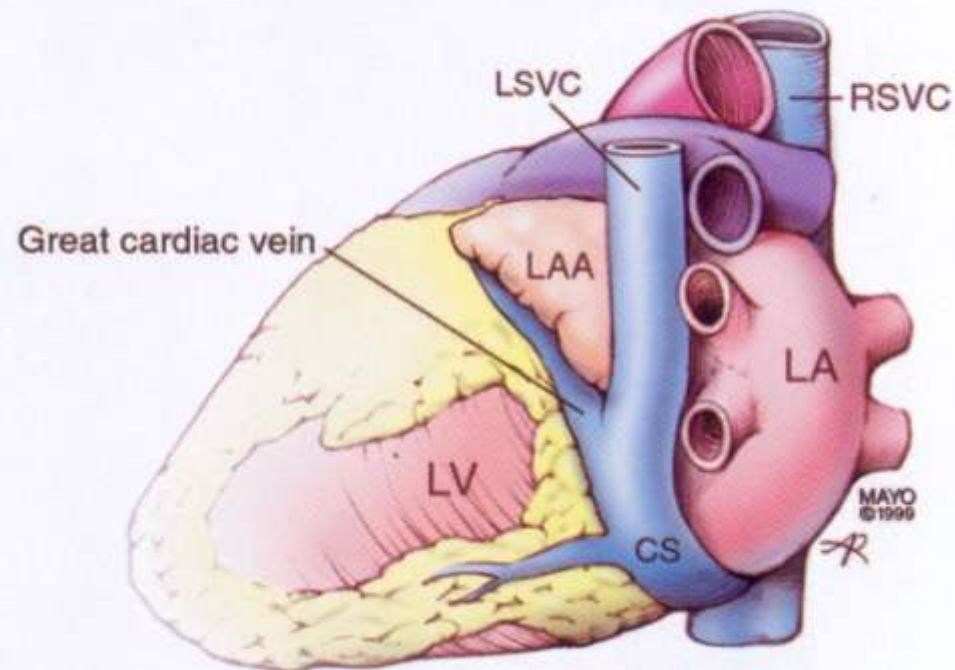
Dominant LAD

No PDA

NORMAL HEART



PERSISTENT LSVC

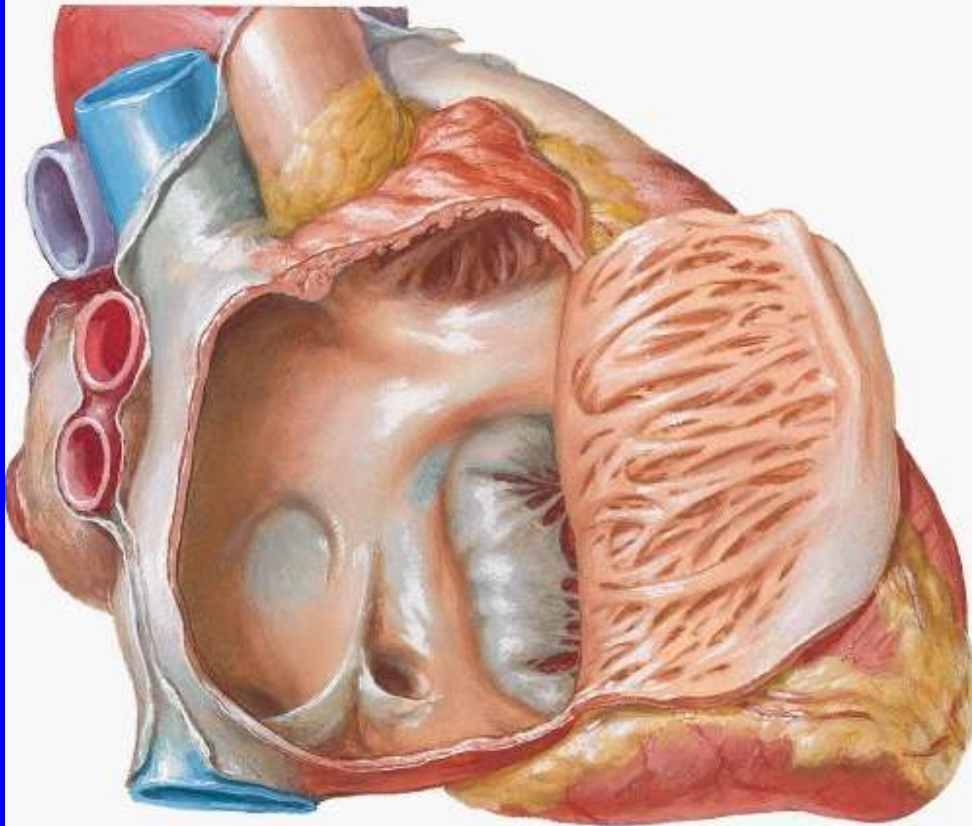


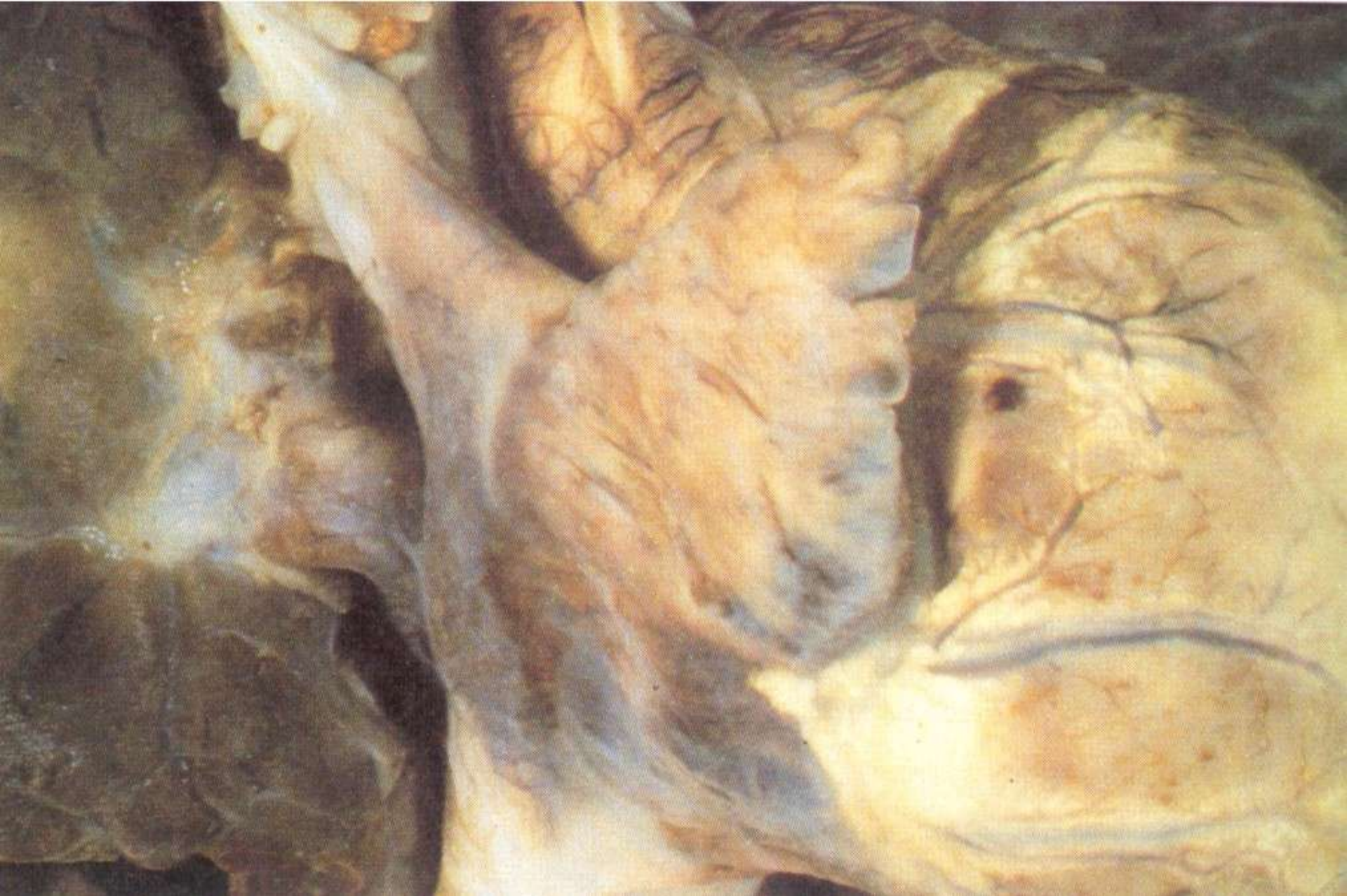Malouf JF et al. Ch. 3, "Functional Anatomy of the Heart" in Hurst's The Heart 12th ed. 2008

Chambers

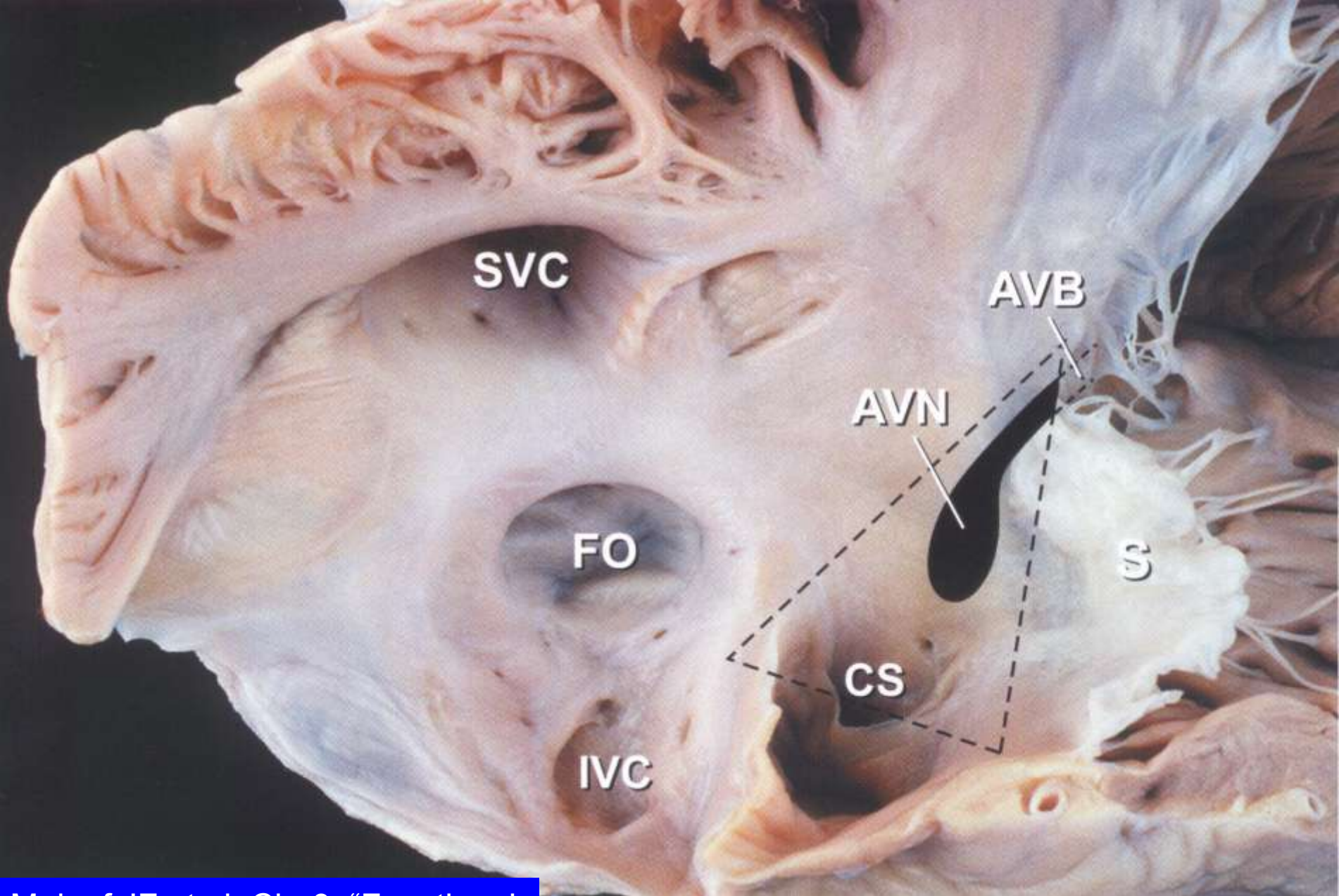
Opened Right Atrium
Right Lateral View

- SVC
- Ascending Ao
- Right PA
- RA appendage
- Right PV
- Sondegaard's groove
- Crista terminalis
- Fossa Ovalis
- Eustachian valve
- Thebesian valve
- Triangle of Koch
- Cavotricuspid isthmus
- Atrioventricular septum (Gerbode)
- IVC
- Sinus venosus atrium

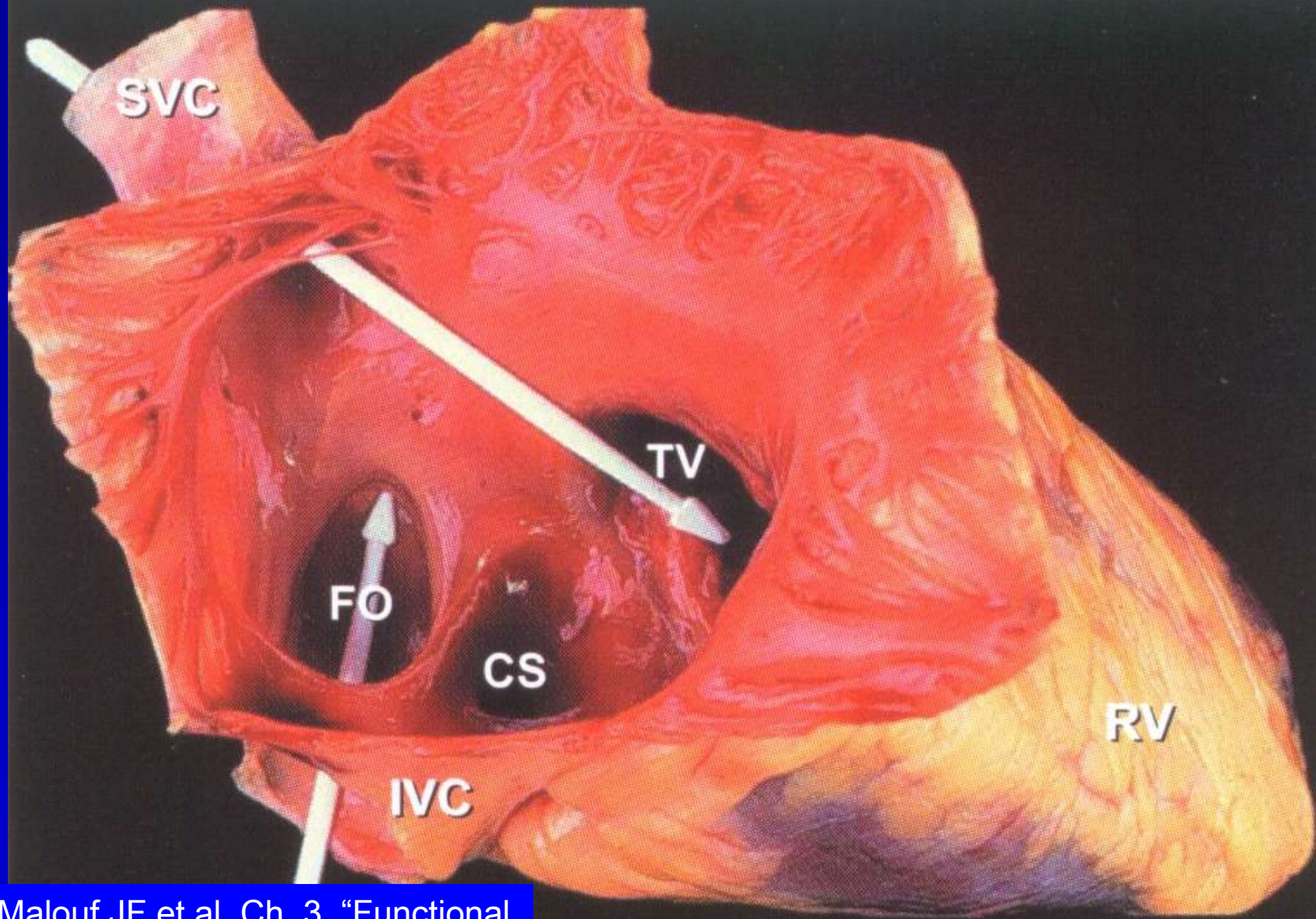




RA Appendage and sulcus terminalis

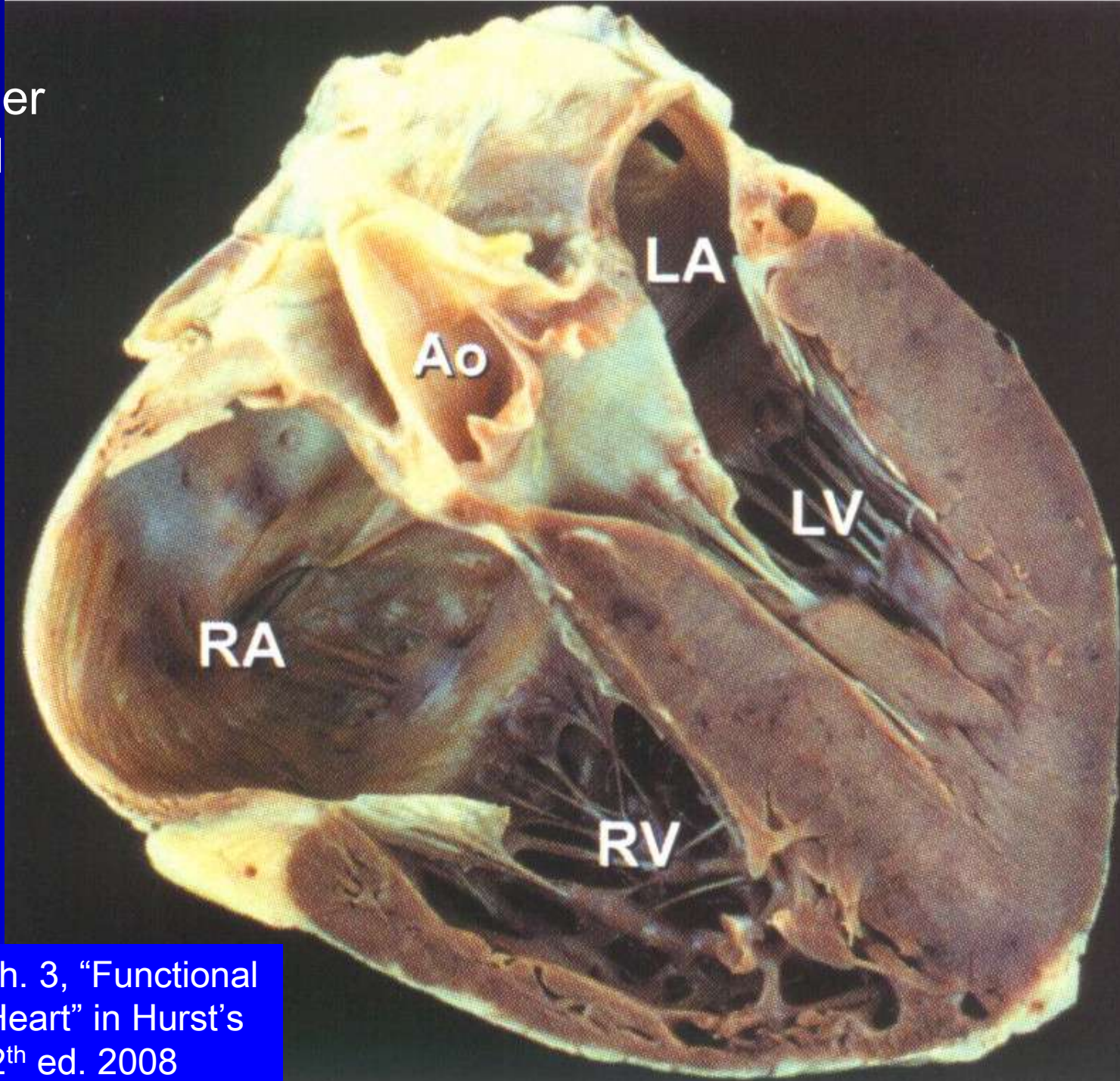


Malouf JF et al. Ch. 3, "Functional Anatomy of the Heart" in Hurst's The Heart 12th ed. 2008



Malouf JF et al. Ch. 3, "Functional
Anatomy of the Heart" in Hurst's
The Heart 12th ed. 2008

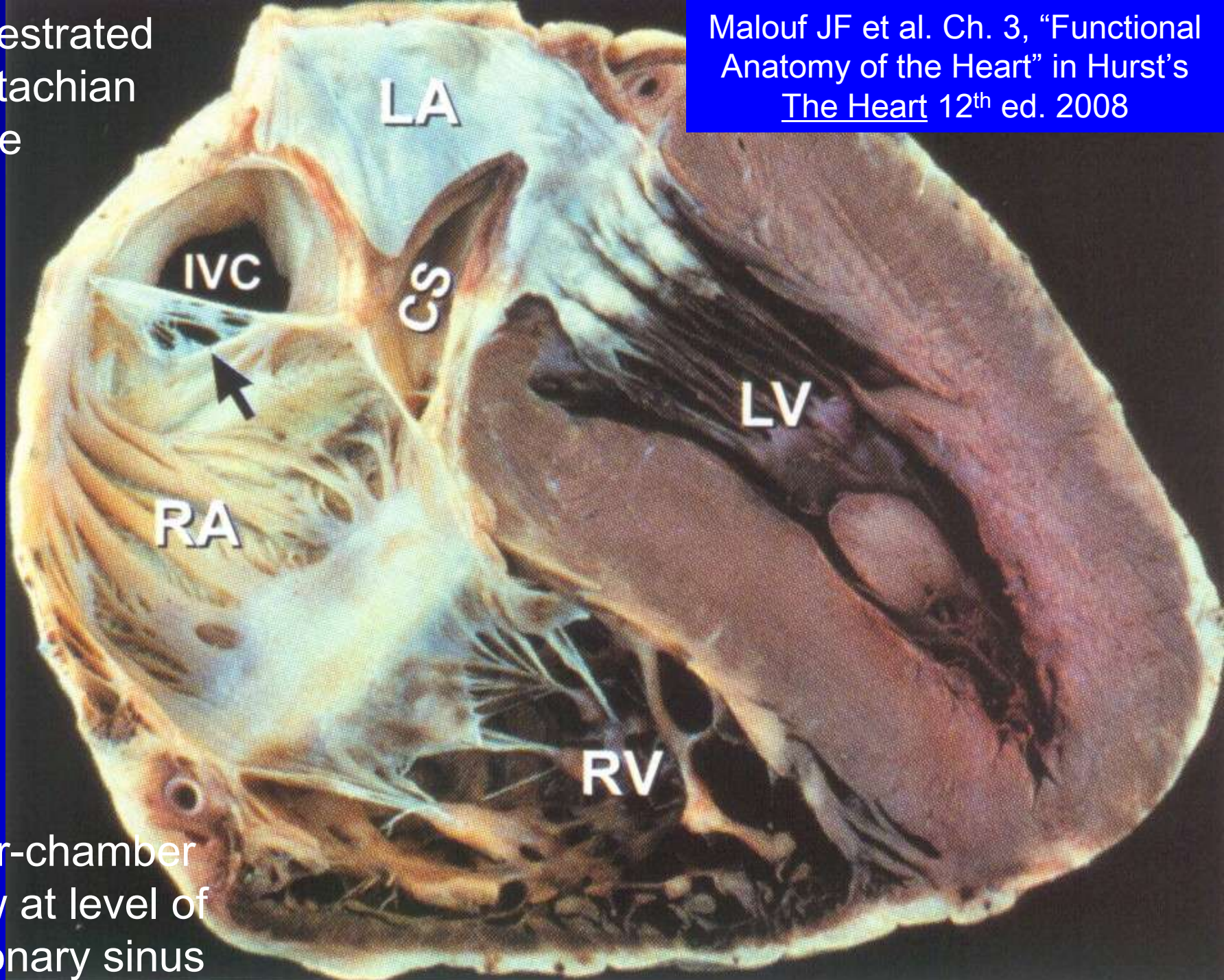
Four-chamber
view at level
of aorta



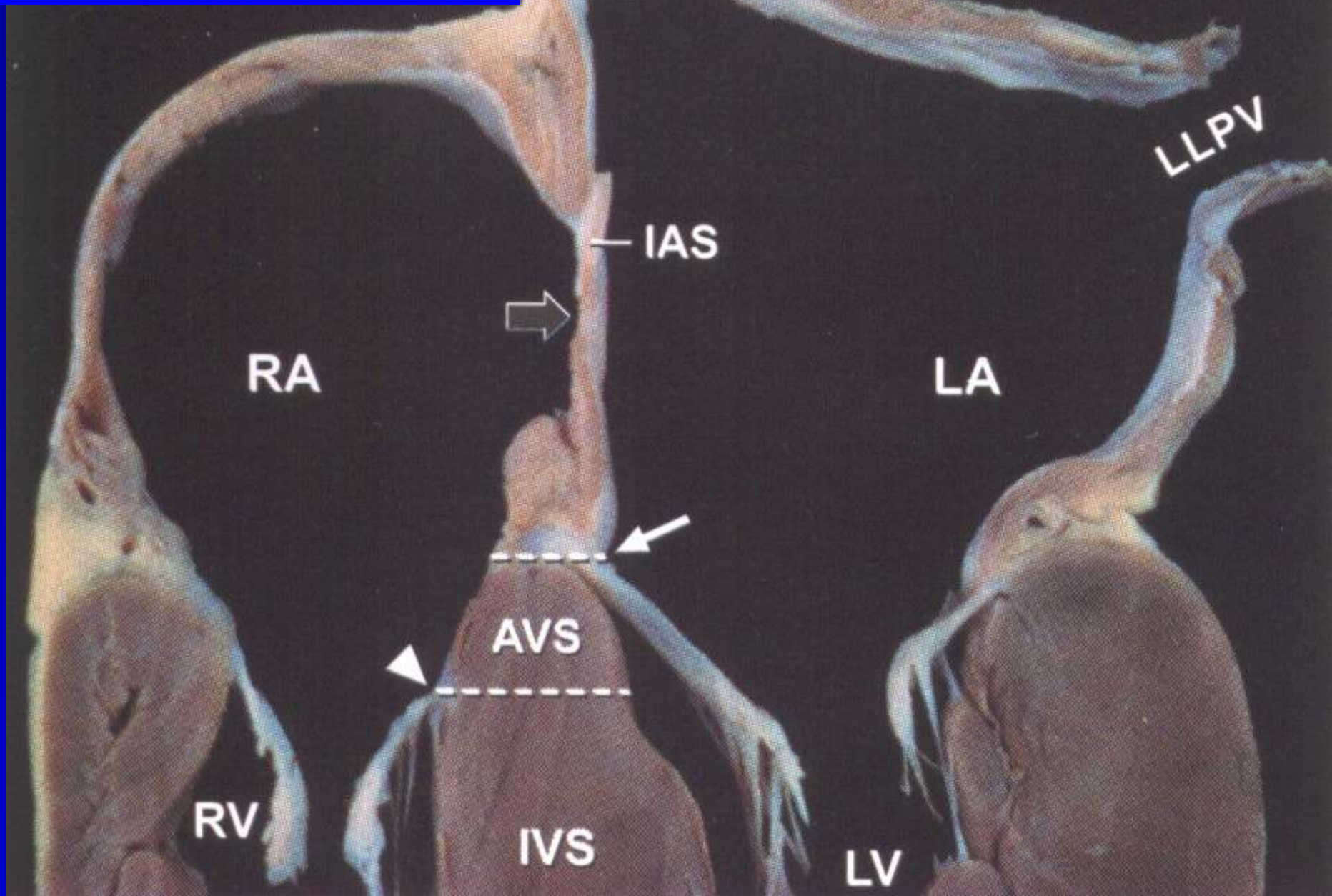
Malouf JF et al. Ch. 3, "Functional
Anatomy of the Heart" in Hurst's
The Heart 12th ed. 2008

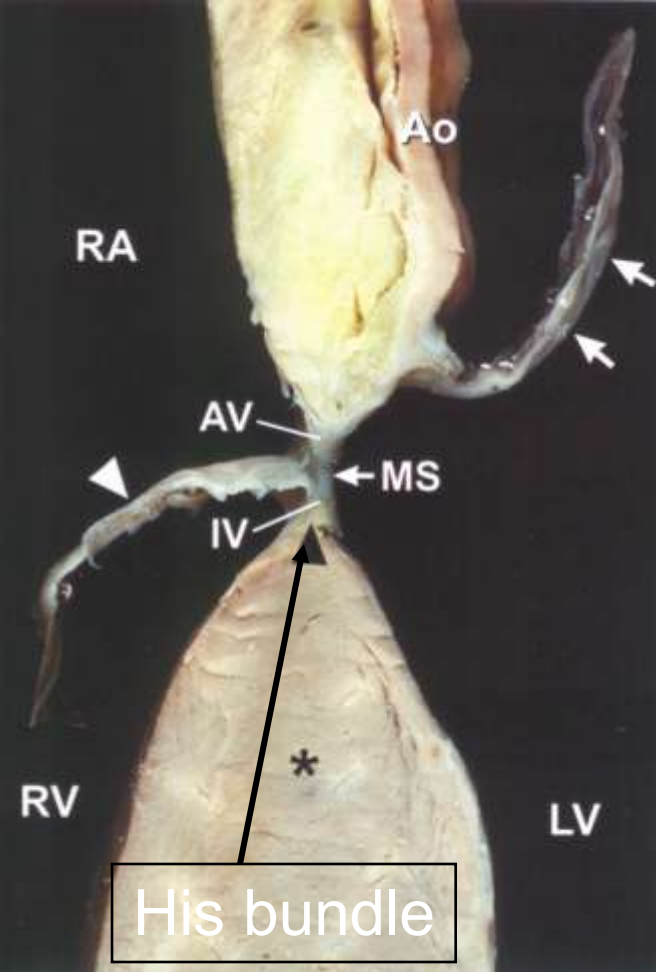
Fenestrated
Eustachian
valve

Malouf JF et al. Ch. 3, "Functional
Anatomy of the Heart" in Hurst's
The Heart 12th ed. 2008



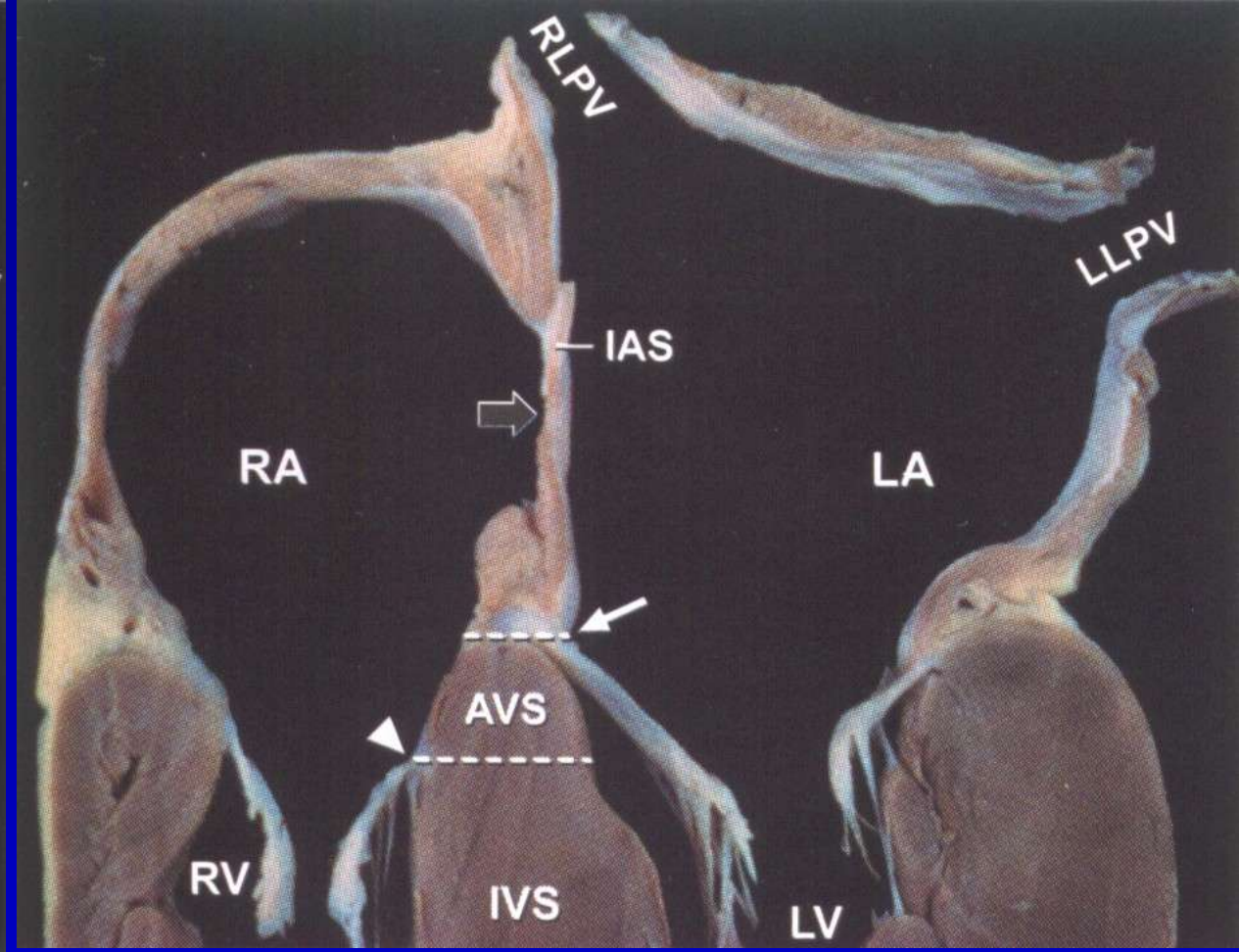
Four-chamber
view at level of
coronary sinus





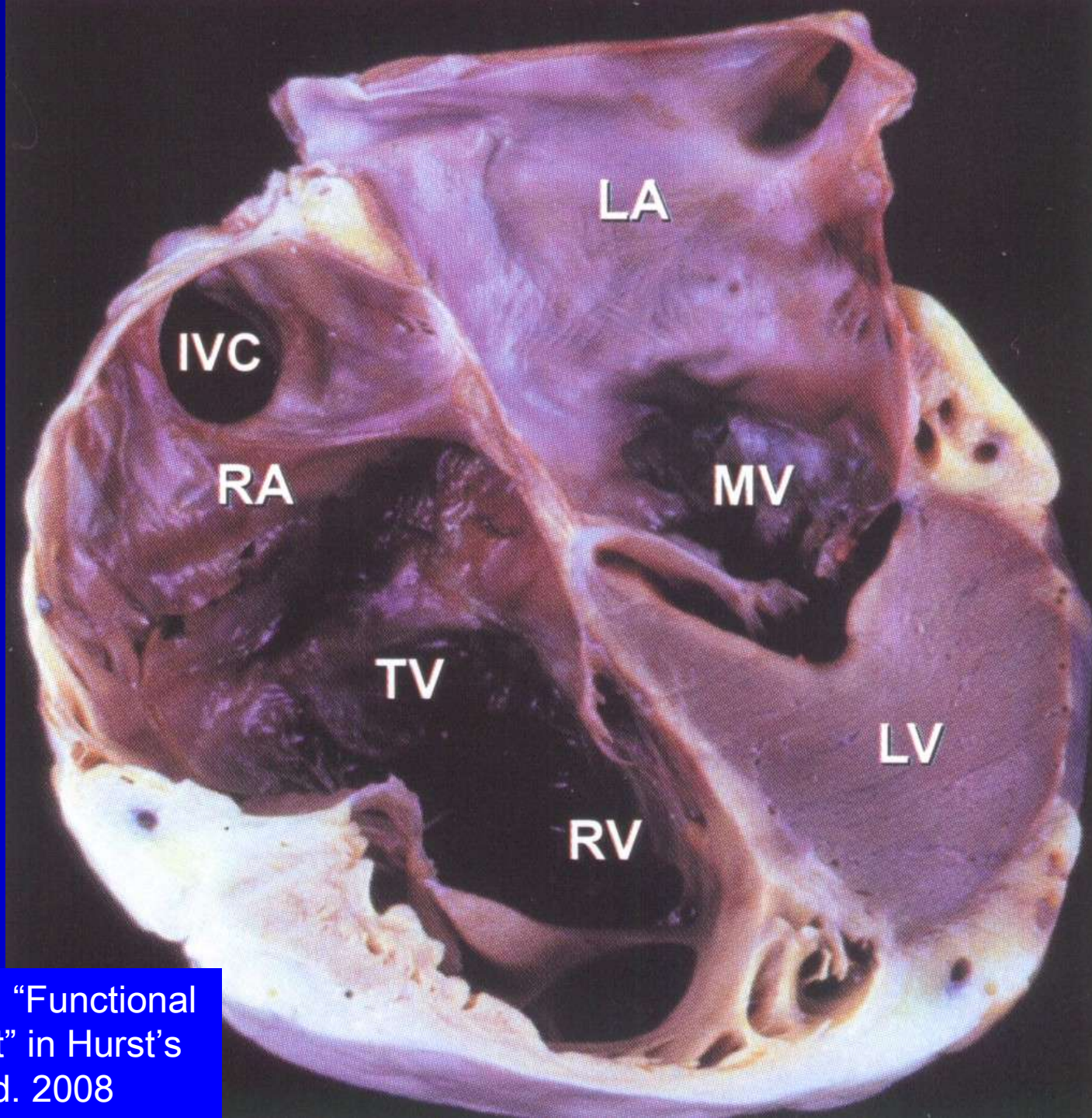
4-chamber slice
through aortic root
and aortic valve

Malouf JF et al. Ch. 3, "Functional
Anatomy of the Heart" in Hurst's
The Heart 12th ed. 2008



Internal cardiac crux – 4-chamber
slice with apical displacement of TV
septal leaflet compared with MV
septal leaflet

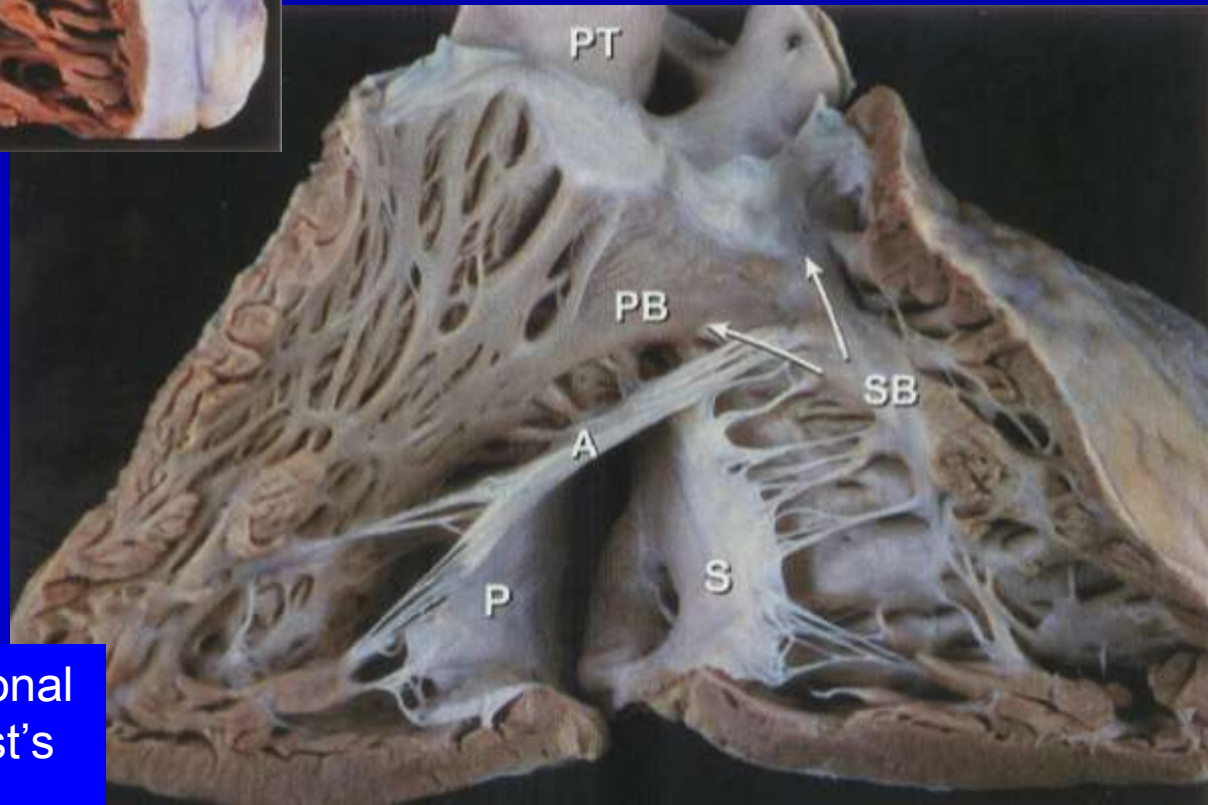
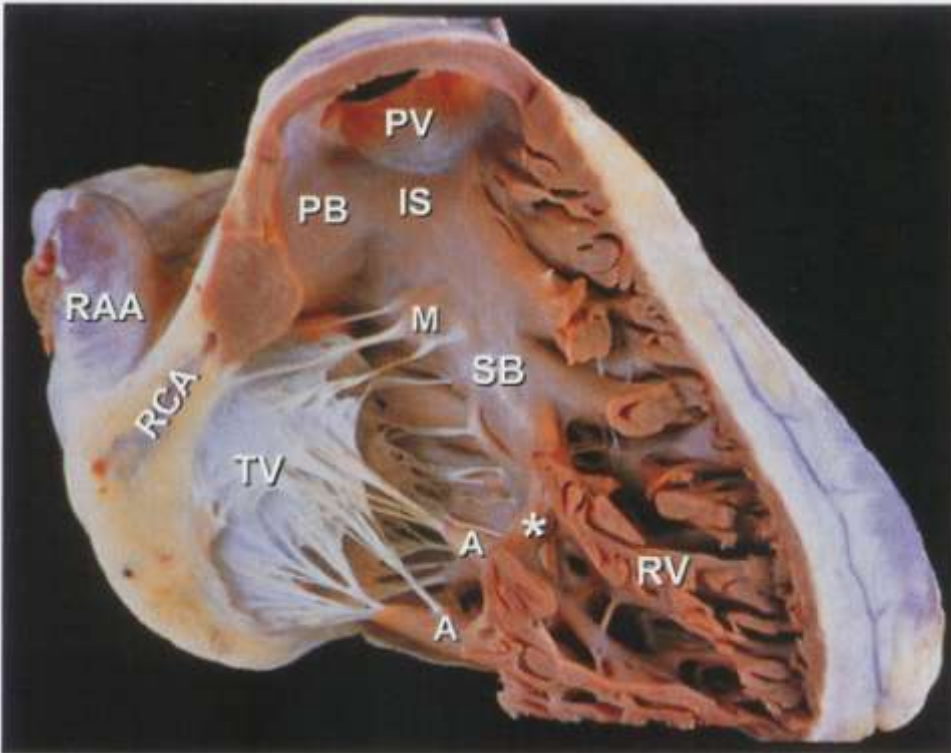
Transverse
section at
level of
cardiac
chambers



Malouf JF et al. Ch. 3, "Functional
Anatomy of the Heart" in Hurst's
The Heart 12th ed. 2008

Right Ventricle

Crista supraventricularis has 3 bands



PB - parietal band

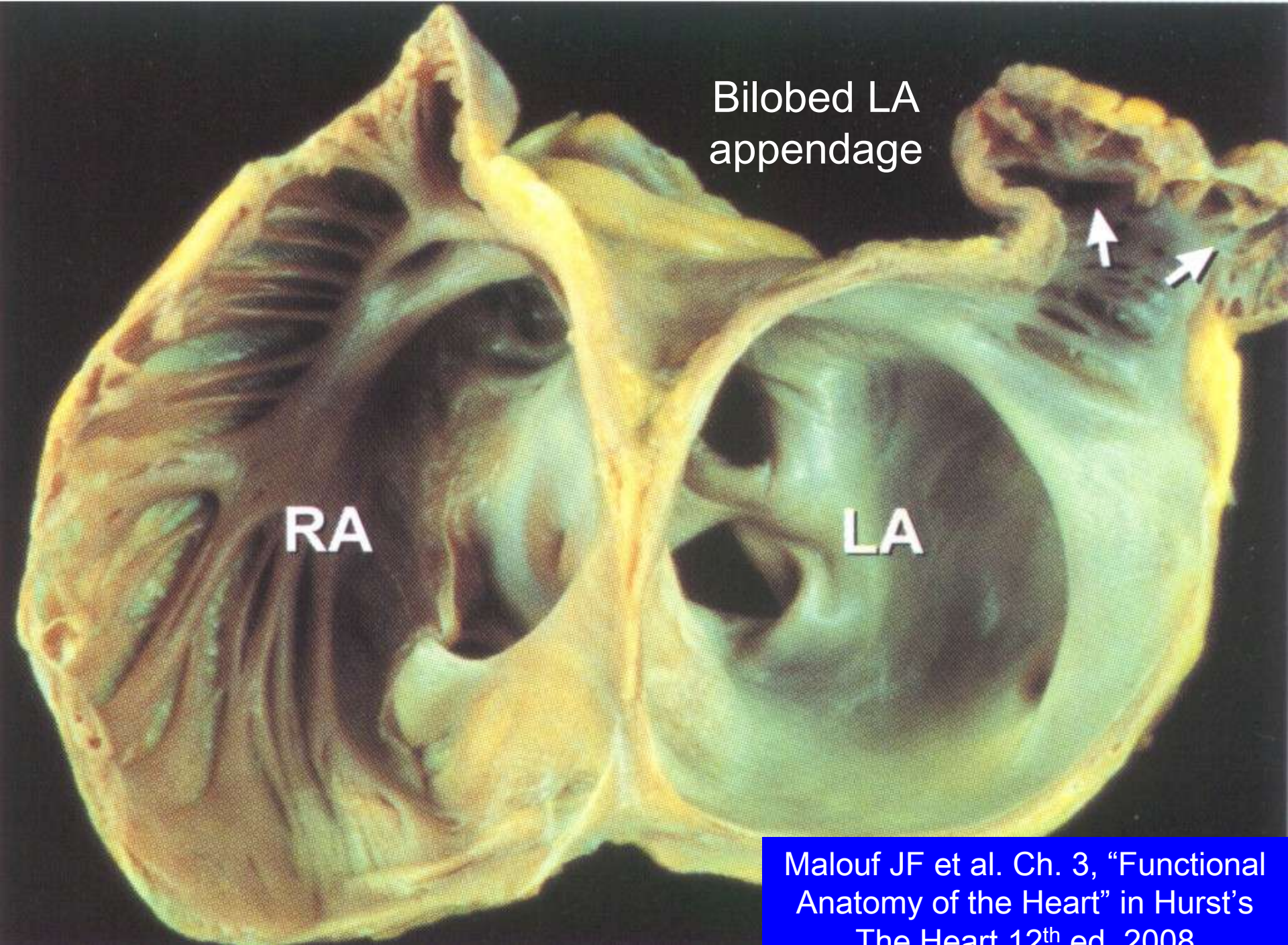
IS - infundibular septum

SB - septal band

• - Moderator band

M - medial papillary muscle

Malouf JF et al. Ch. 3, "Functional Anatomy of the Heart" in Hurst's The Heart 12th ed. 2008

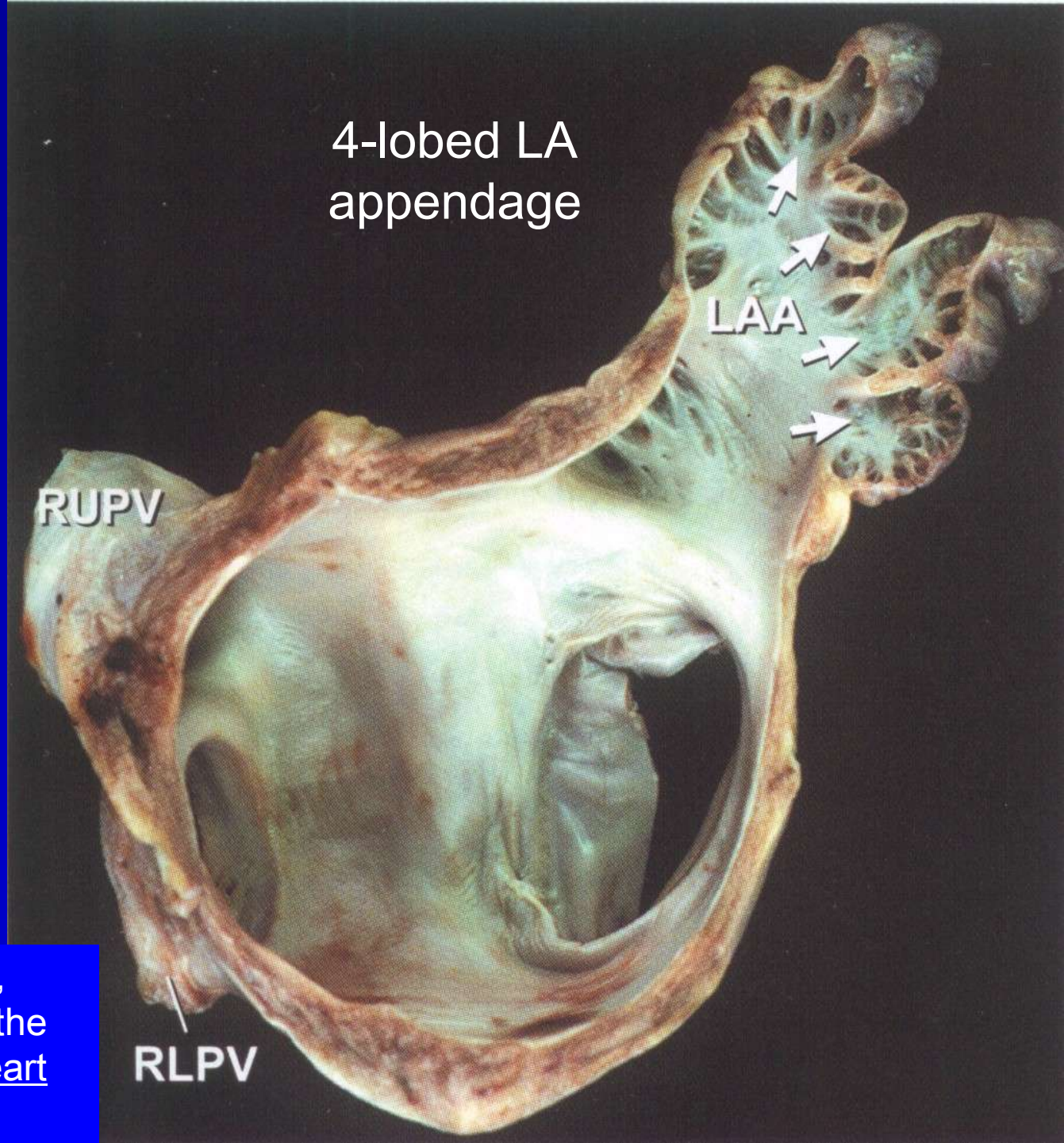


Bilobed LA
appendage

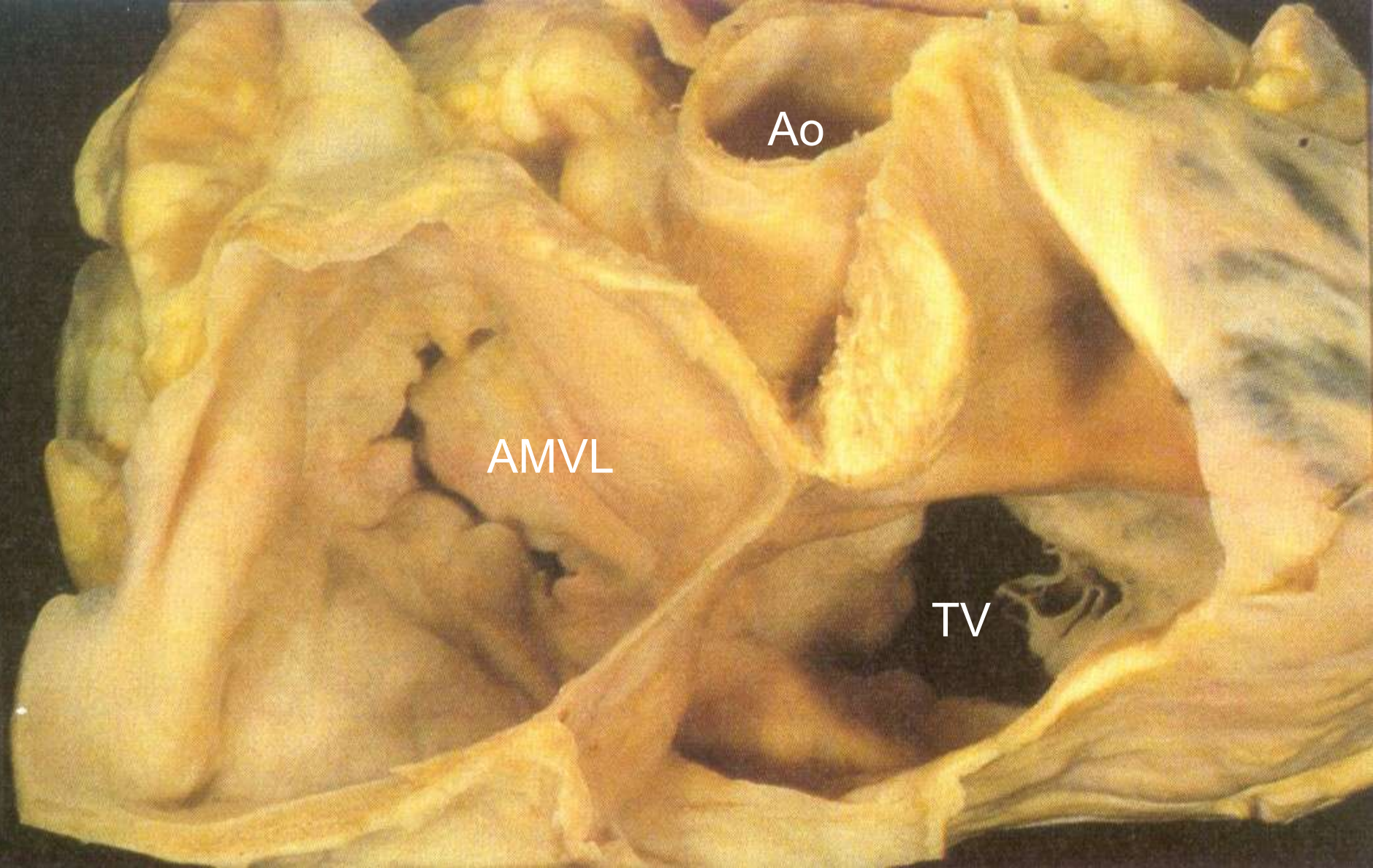
RA

LA

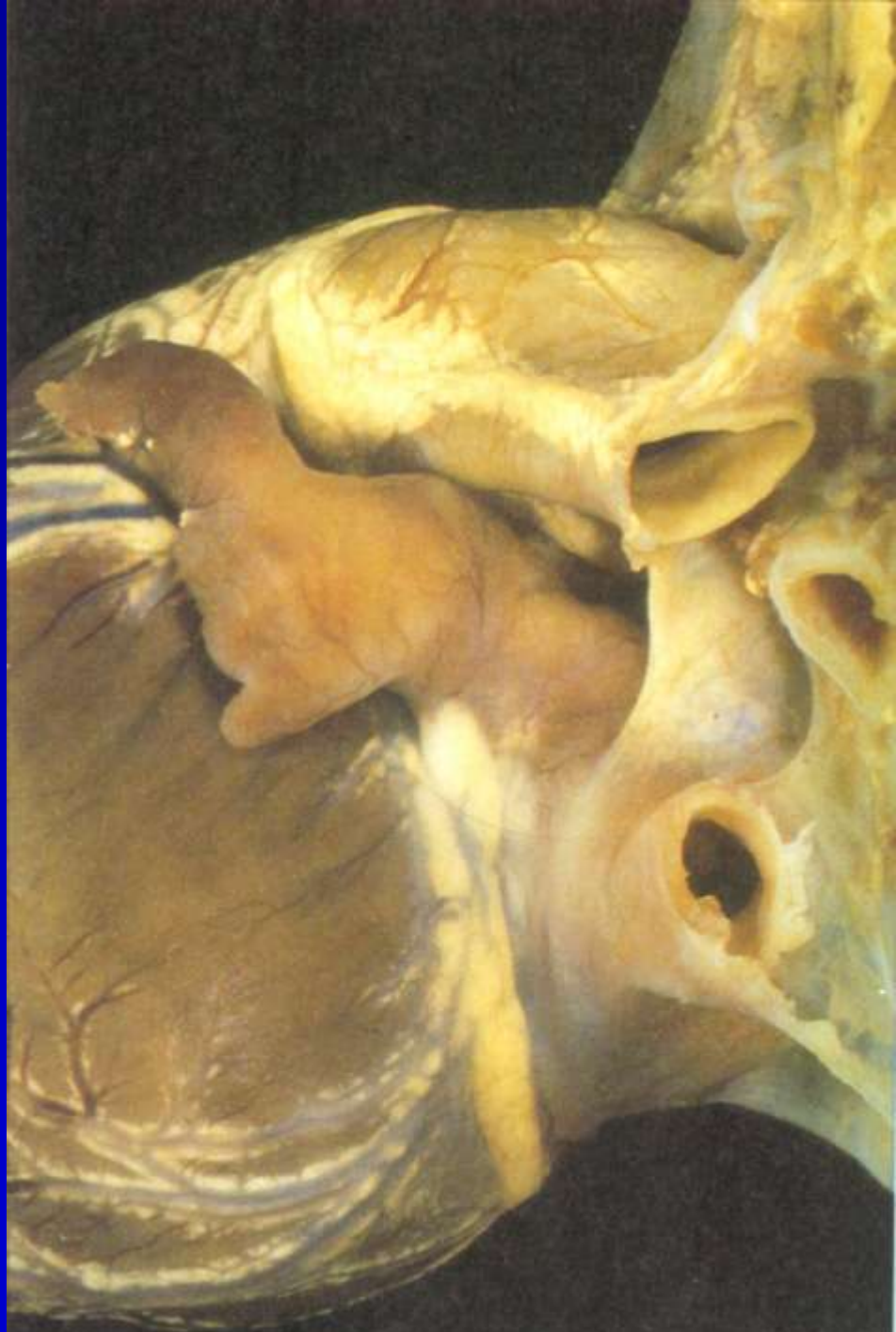
Malouf JF et al. Ch. 3, "Functional
Anatomy of the Heart" in Hurst's
The Heart 12th ed. 2008



Malouf JF et al. Ch. 3,
“Functional Anatomy of the
Heart” in Hurst’s The Heart
12th ed. 2008

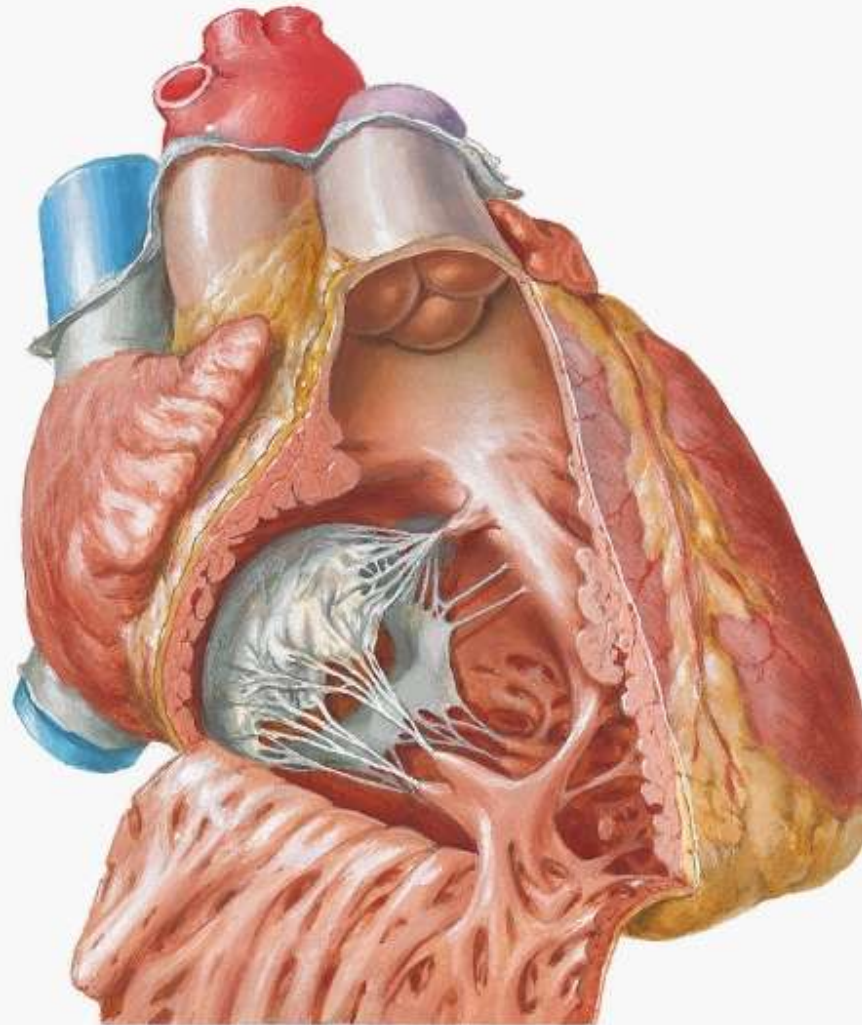


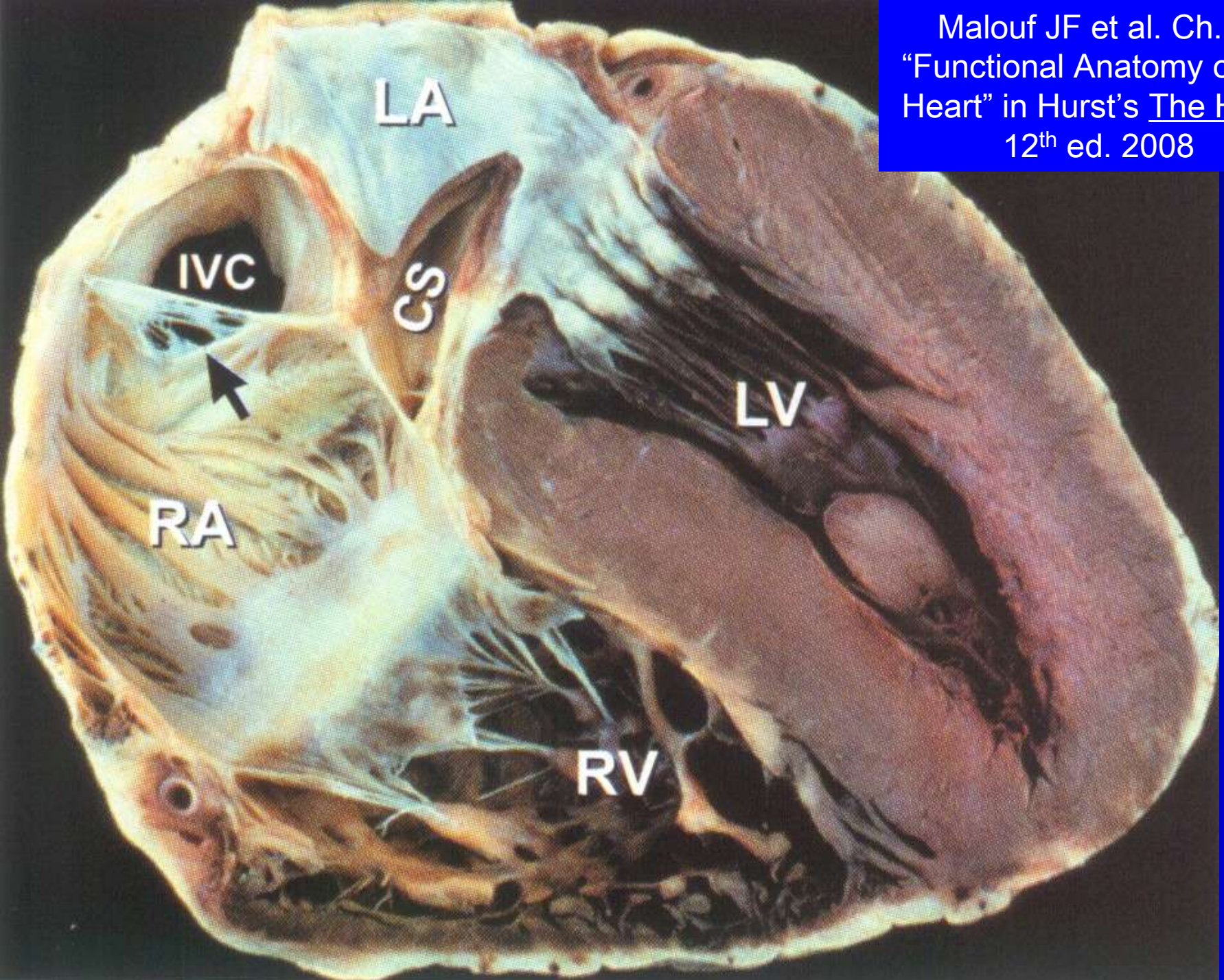
Interatrial septum: Waterston's groove



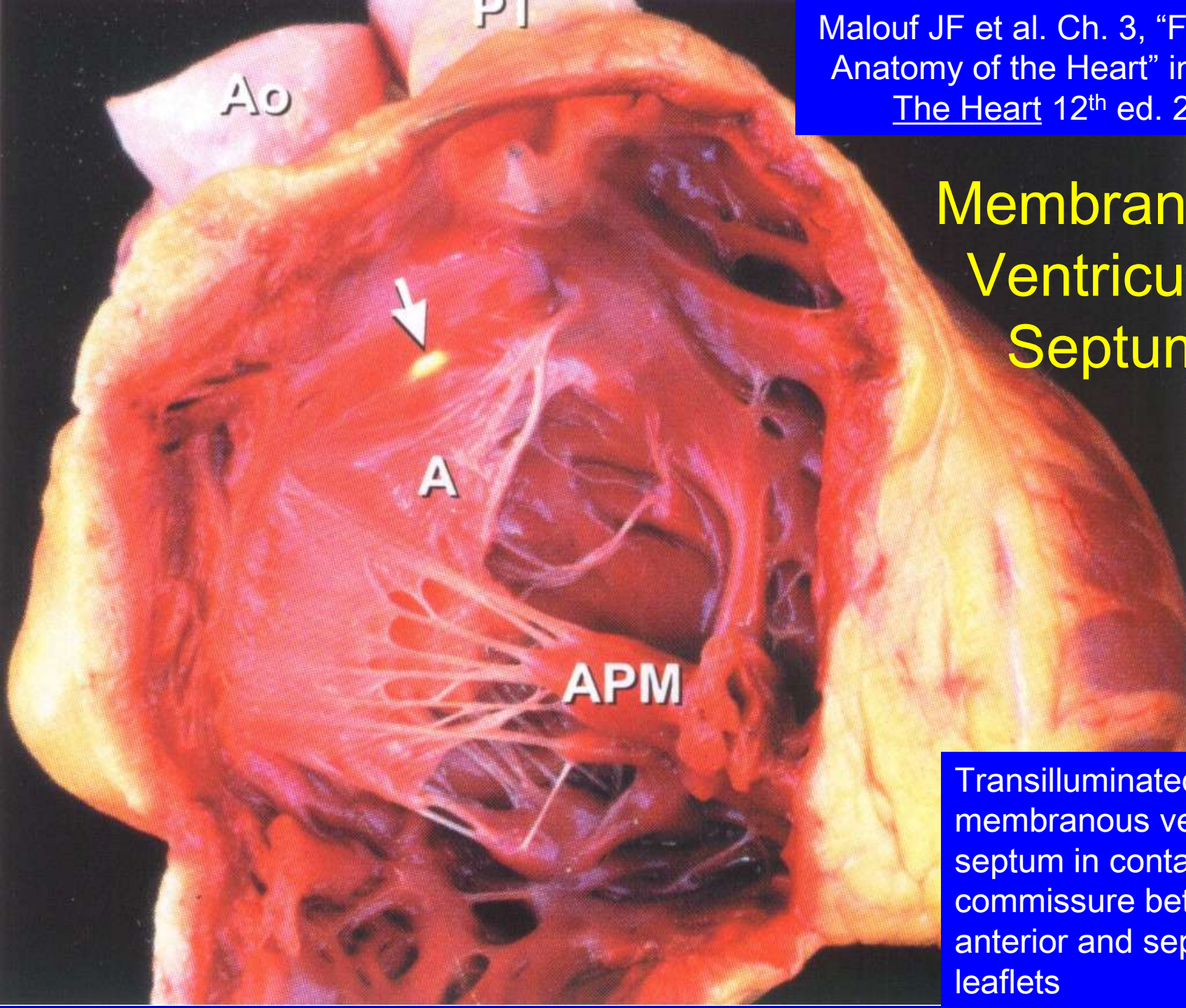
Opened Right Ventricle

Anterior View





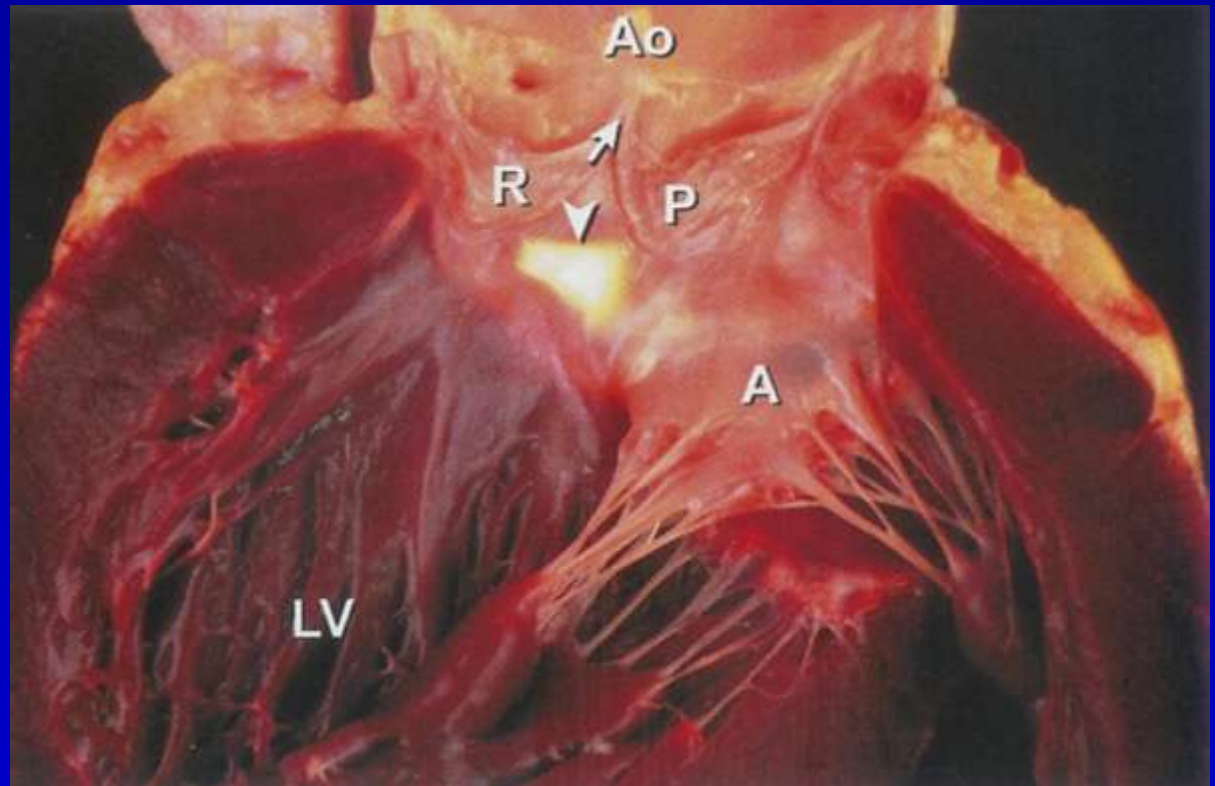
Membranous Ventricular Septum



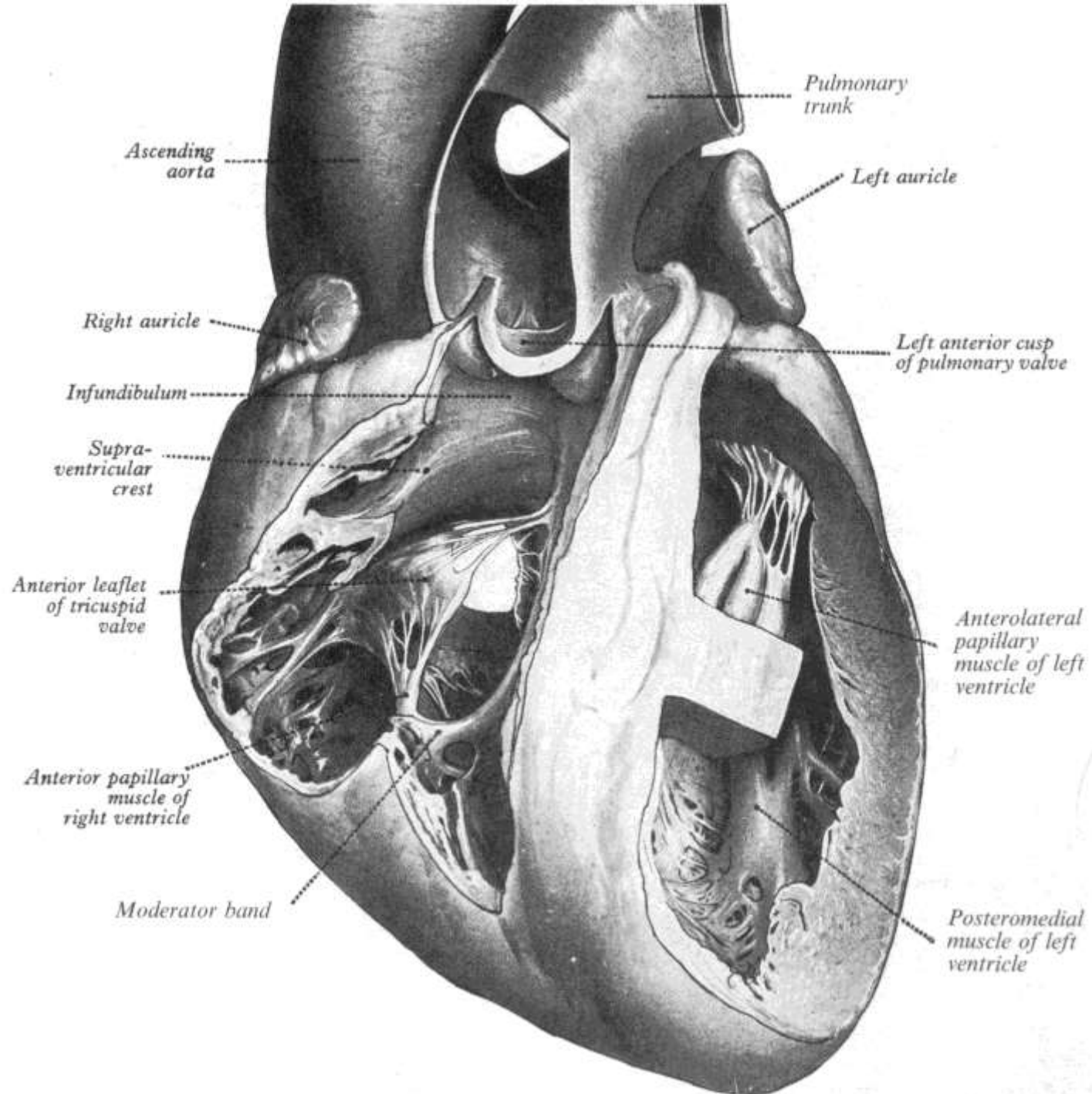
Transilluminated
membranous ventricular
septum in contact with
commissure between
anterior and septal
leaflets

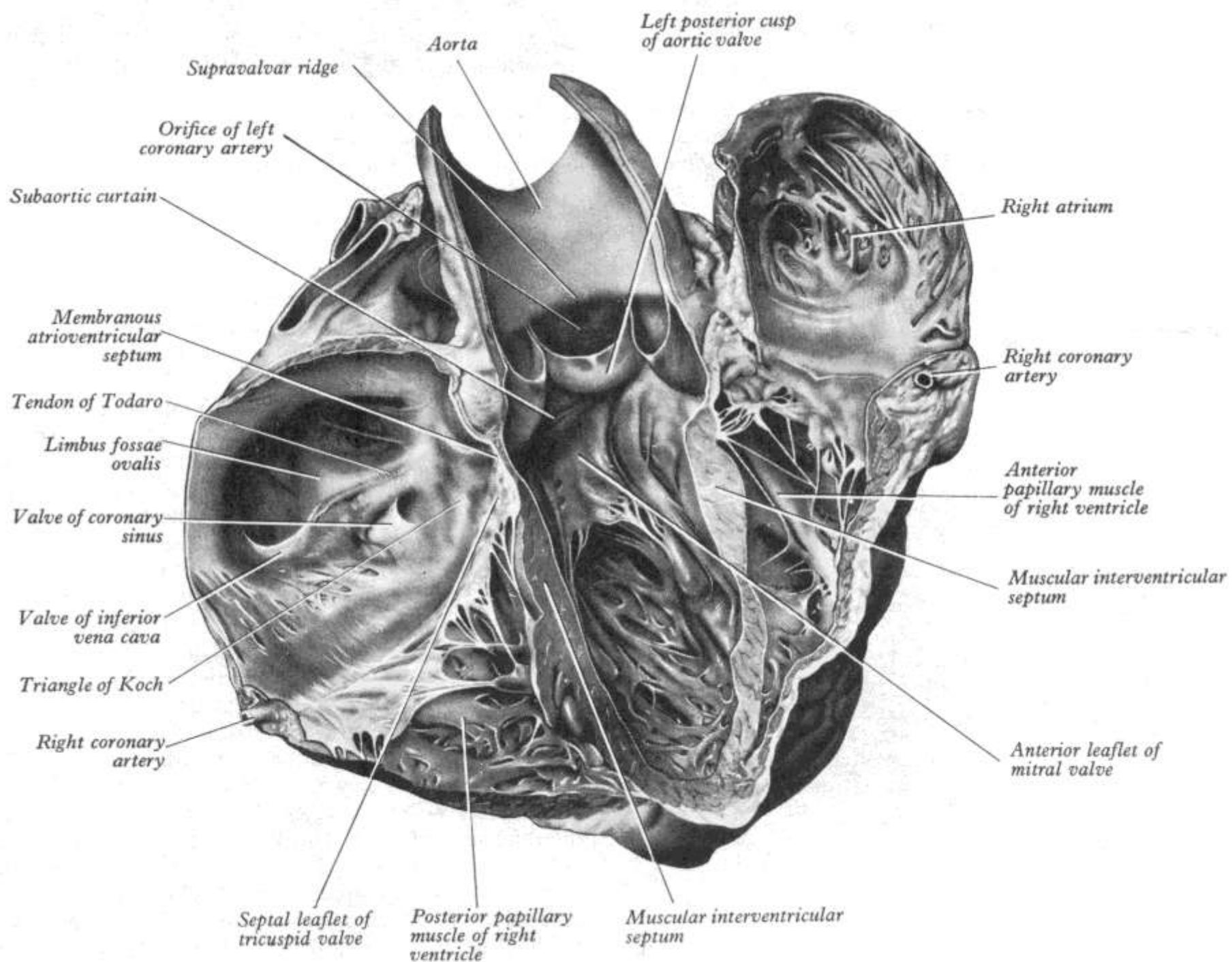
Membranous Ventricular Septum

Transilluminated
membranous ventricular
septum near junction of
right and posterior
leaflets

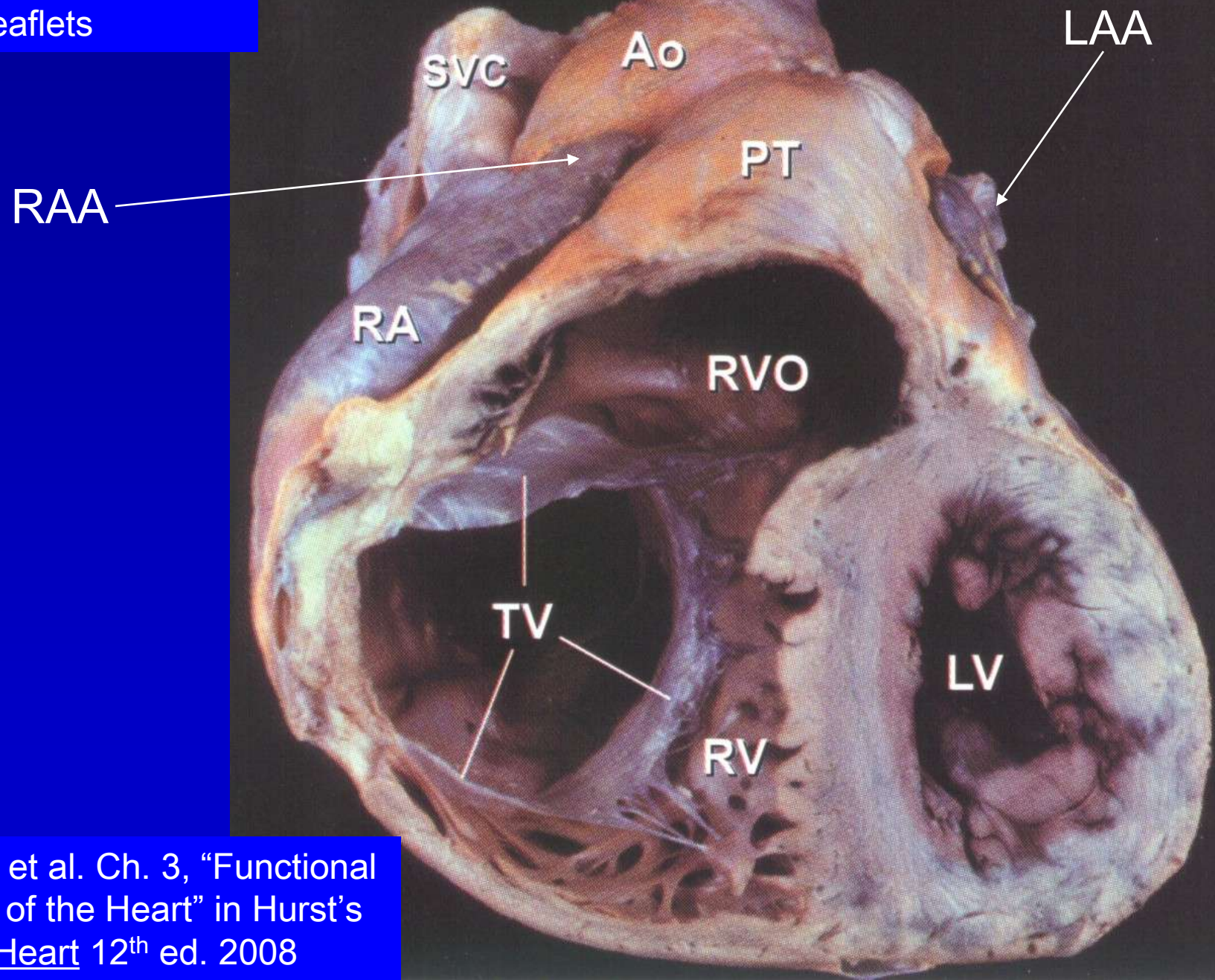


Malouf JF et al. Ch. 3, "Functional
Anatomy of the Heart" in Hurst's
The Heart 12th ed. 2008

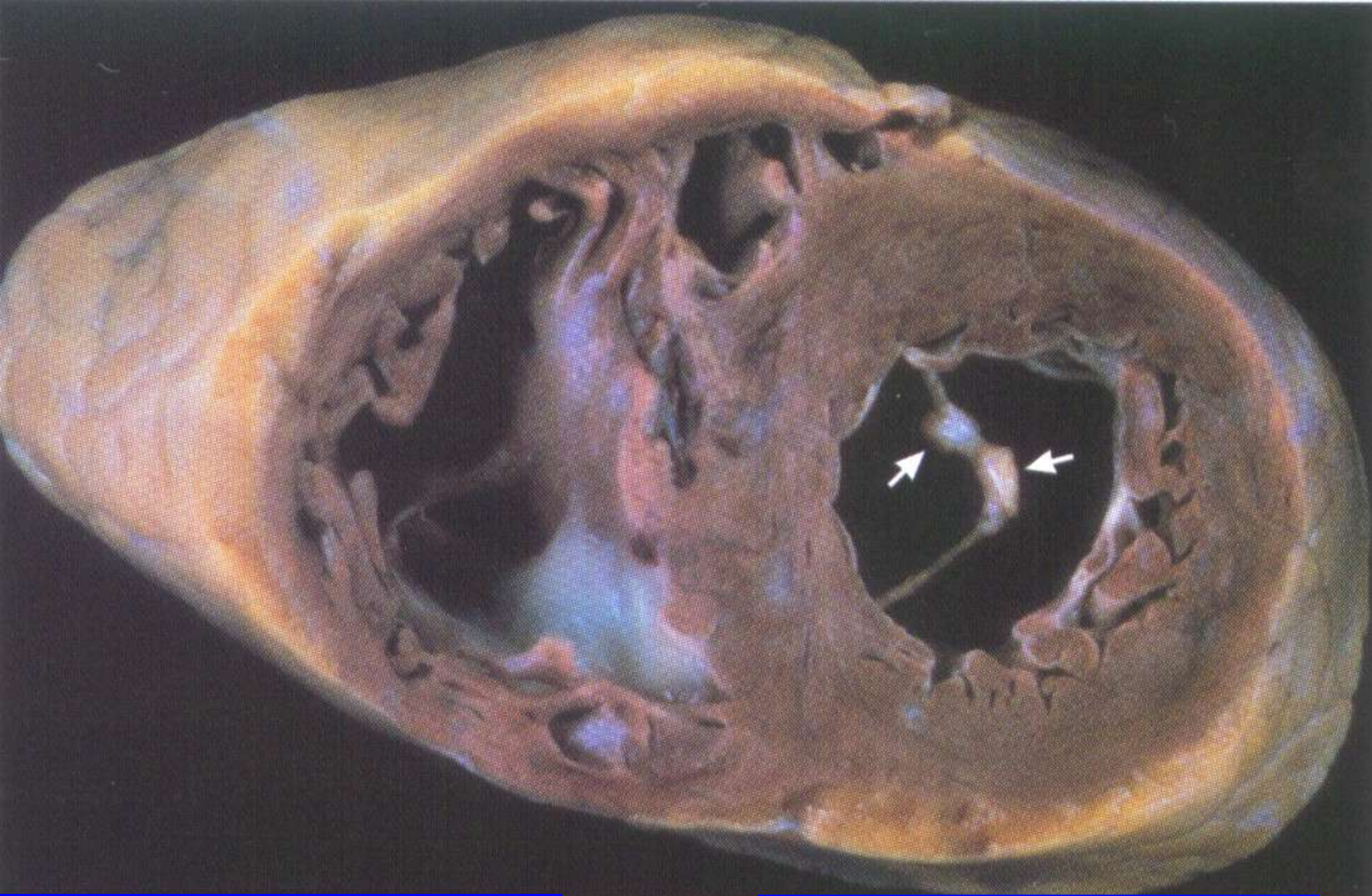




Frontal section:
TV anterior, septal and
posterior leaflets



Malouf JF et al. Ch. 3, "Functional
Anatomy of the Heart" in Hurst's
The Heart 12th ed. 2008

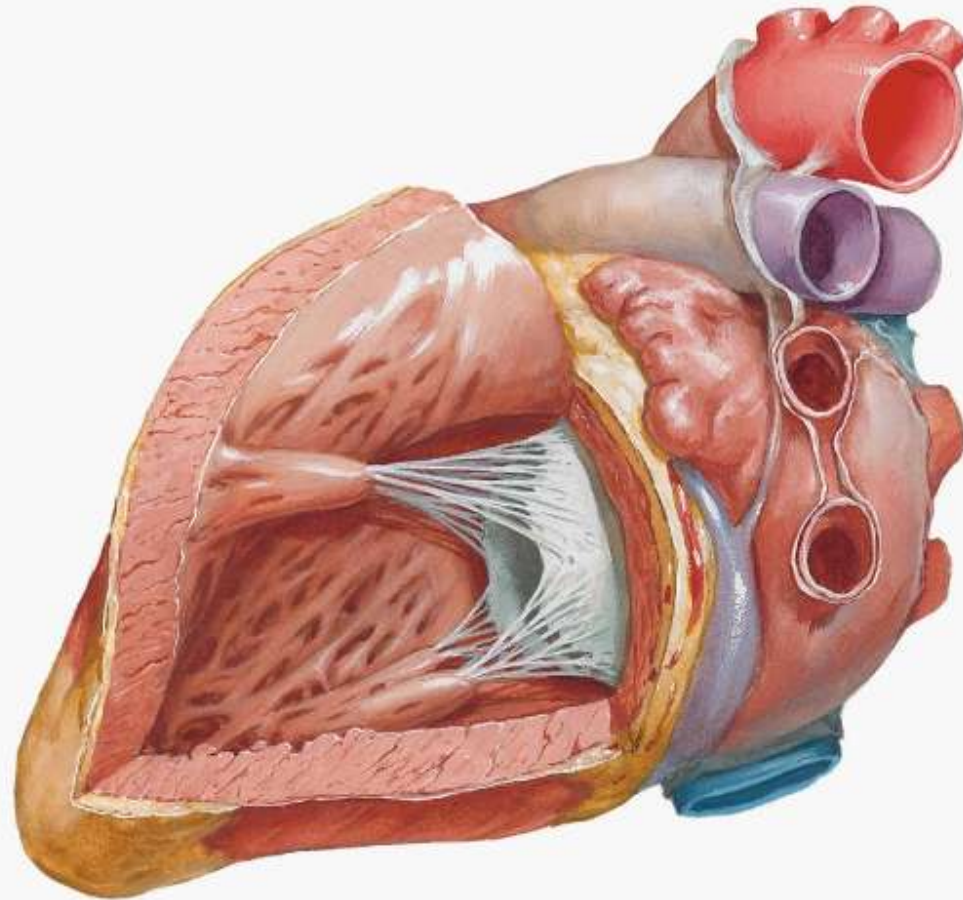


Malouf JF et al. Ch. 3, "Functional
Anatomy of the Heart" in Hurst's
The Heart 12th ed. 2008

Calcified LV false tendon seen in
short-axis view

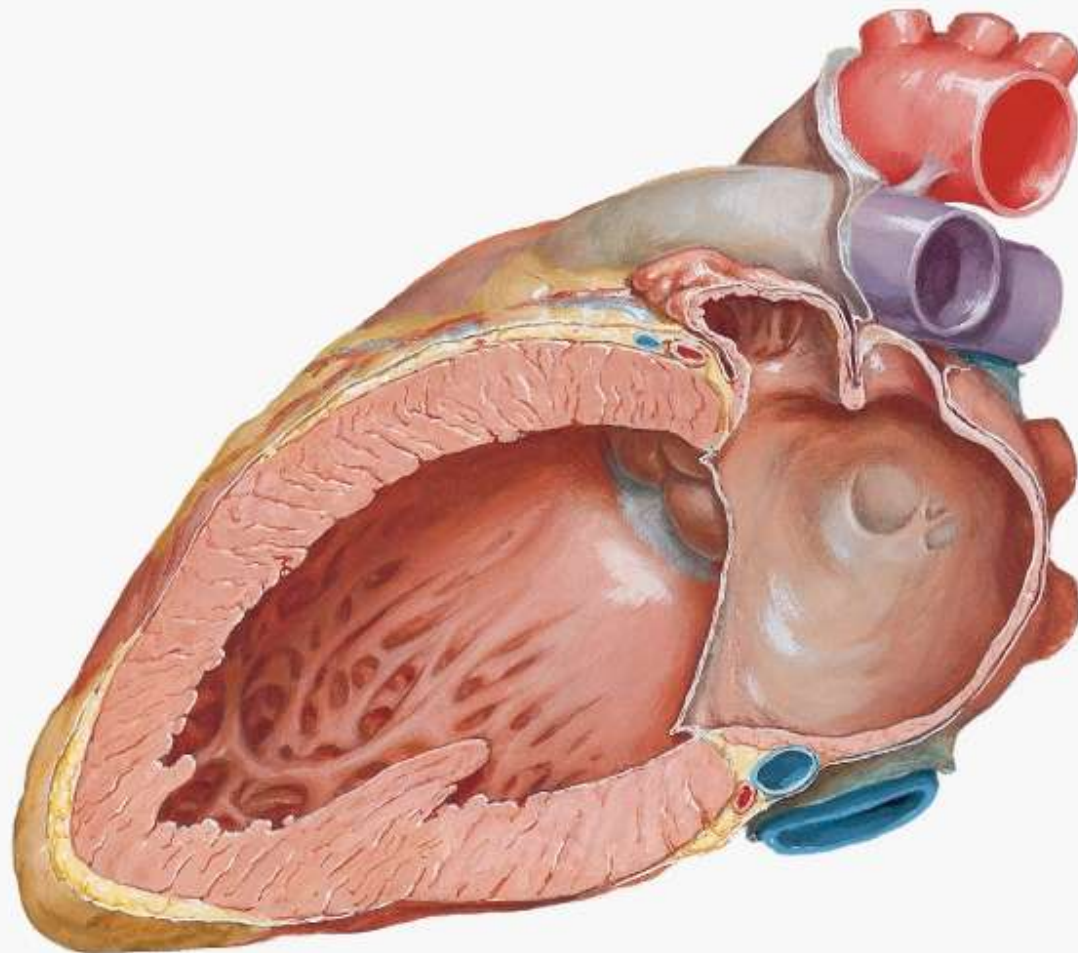
Left Ventricle

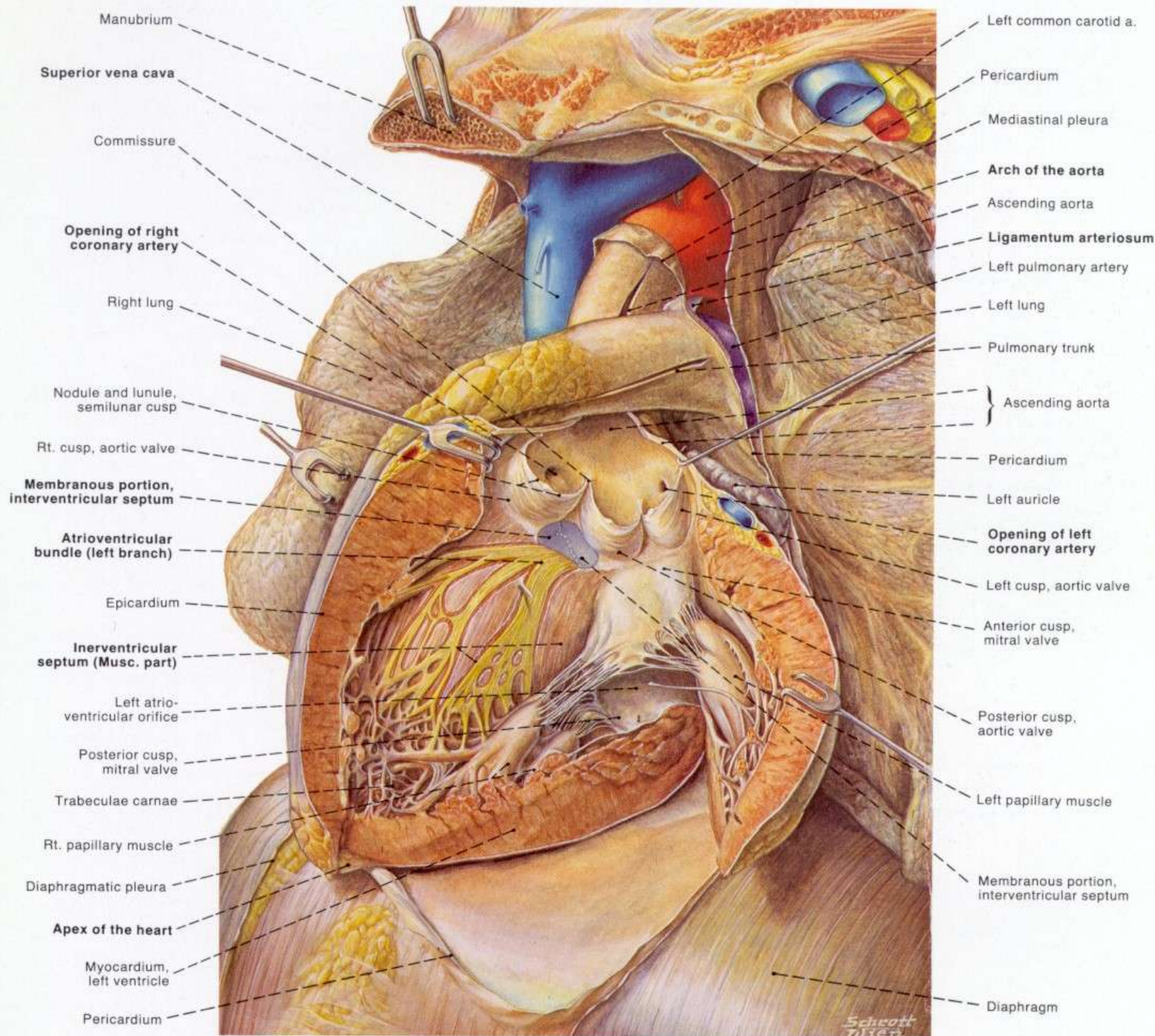
Flap Opened in Posterolateral Wall



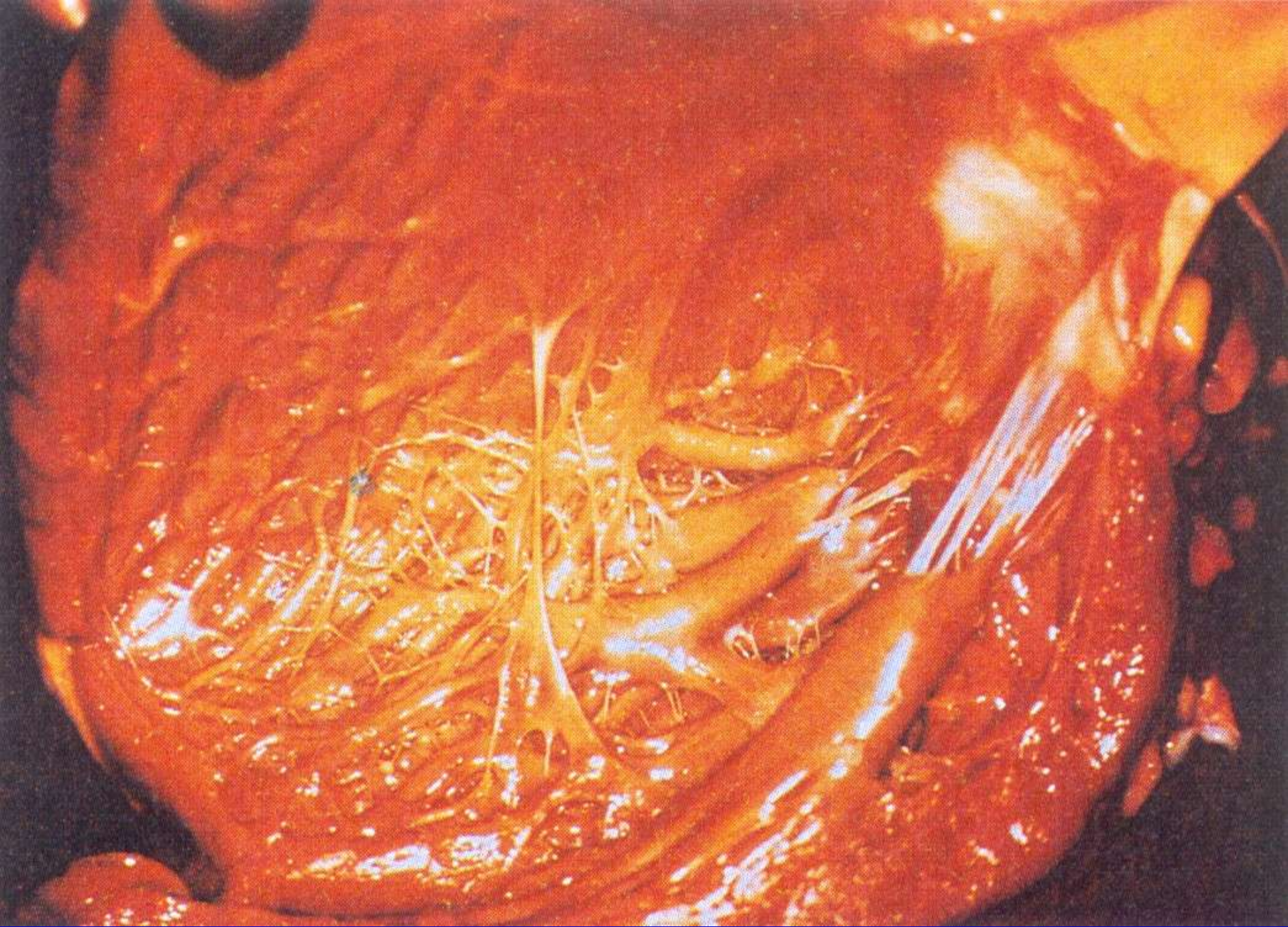
Left Atrium and Ventricle

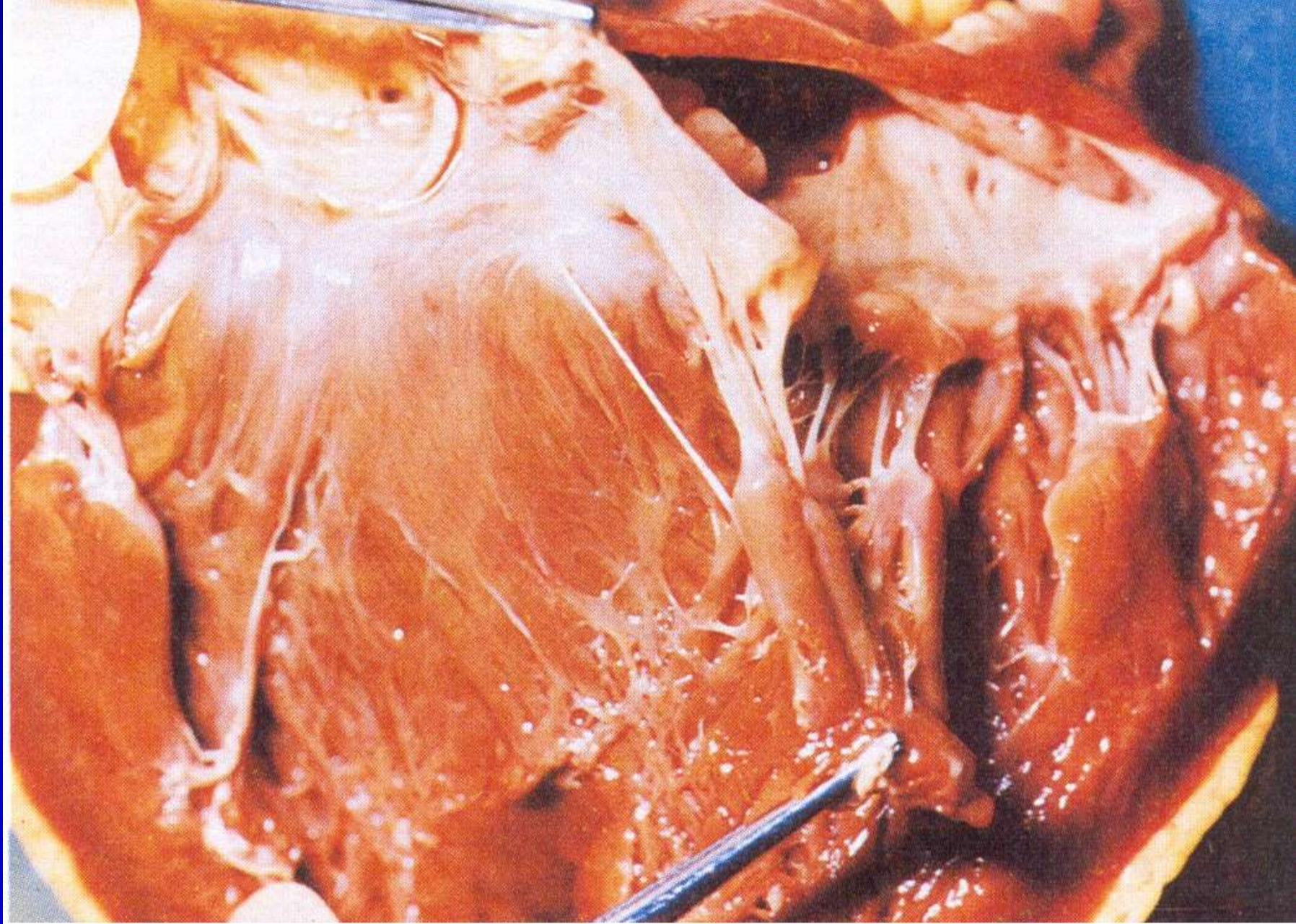
Sectioned with Mitral Valve Cut Away

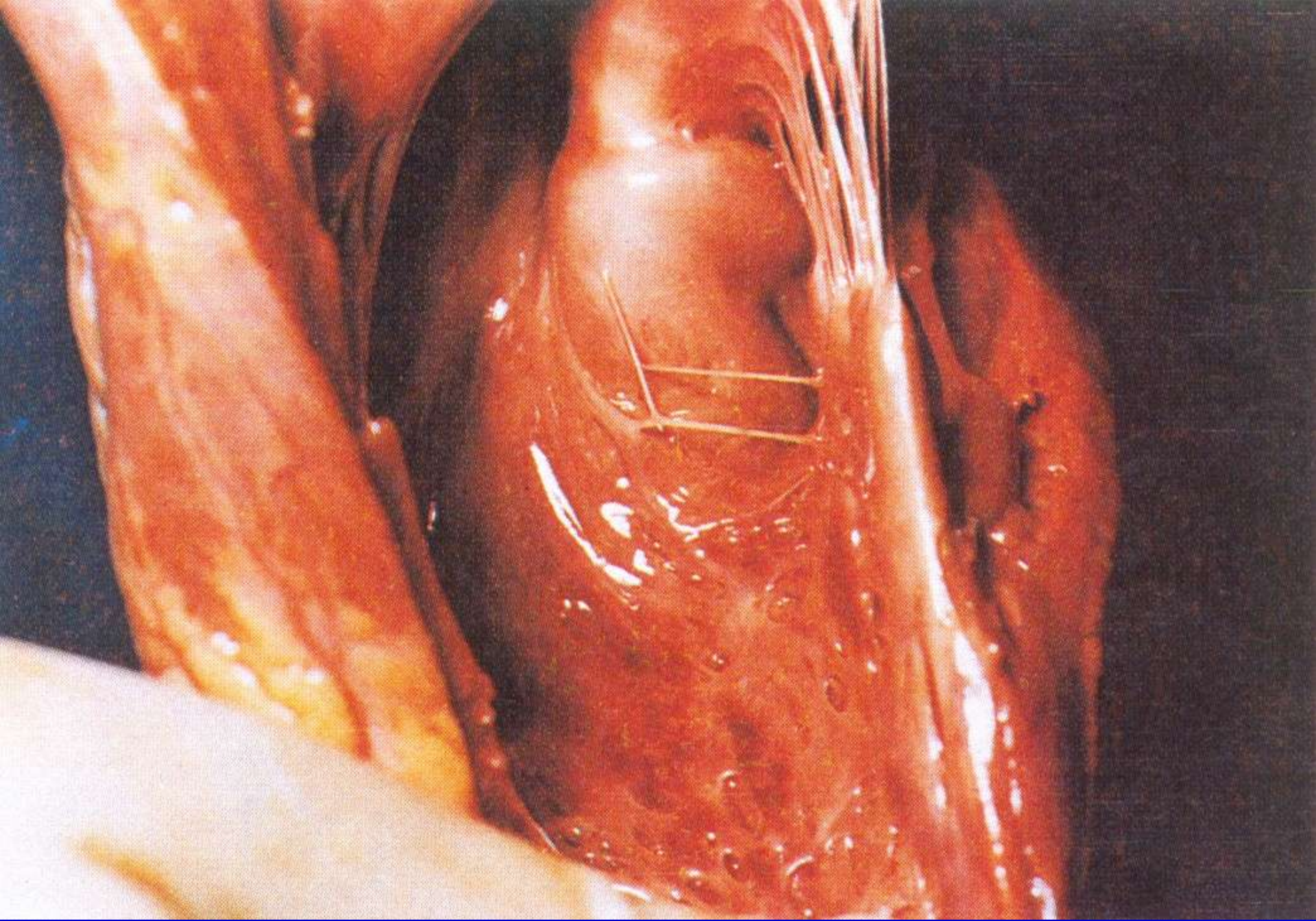


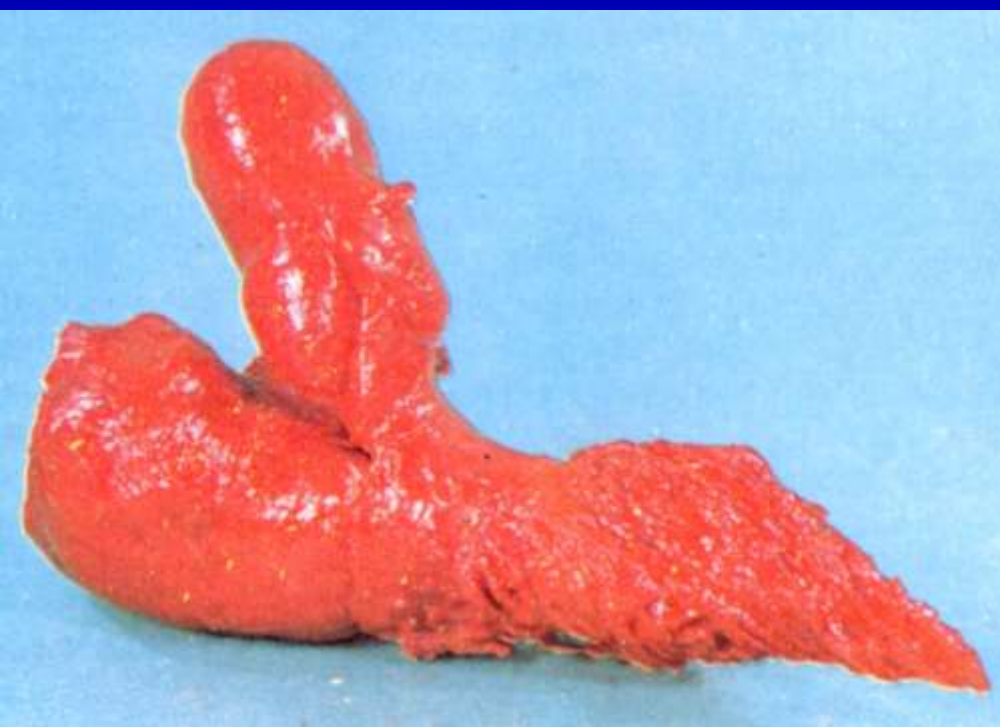


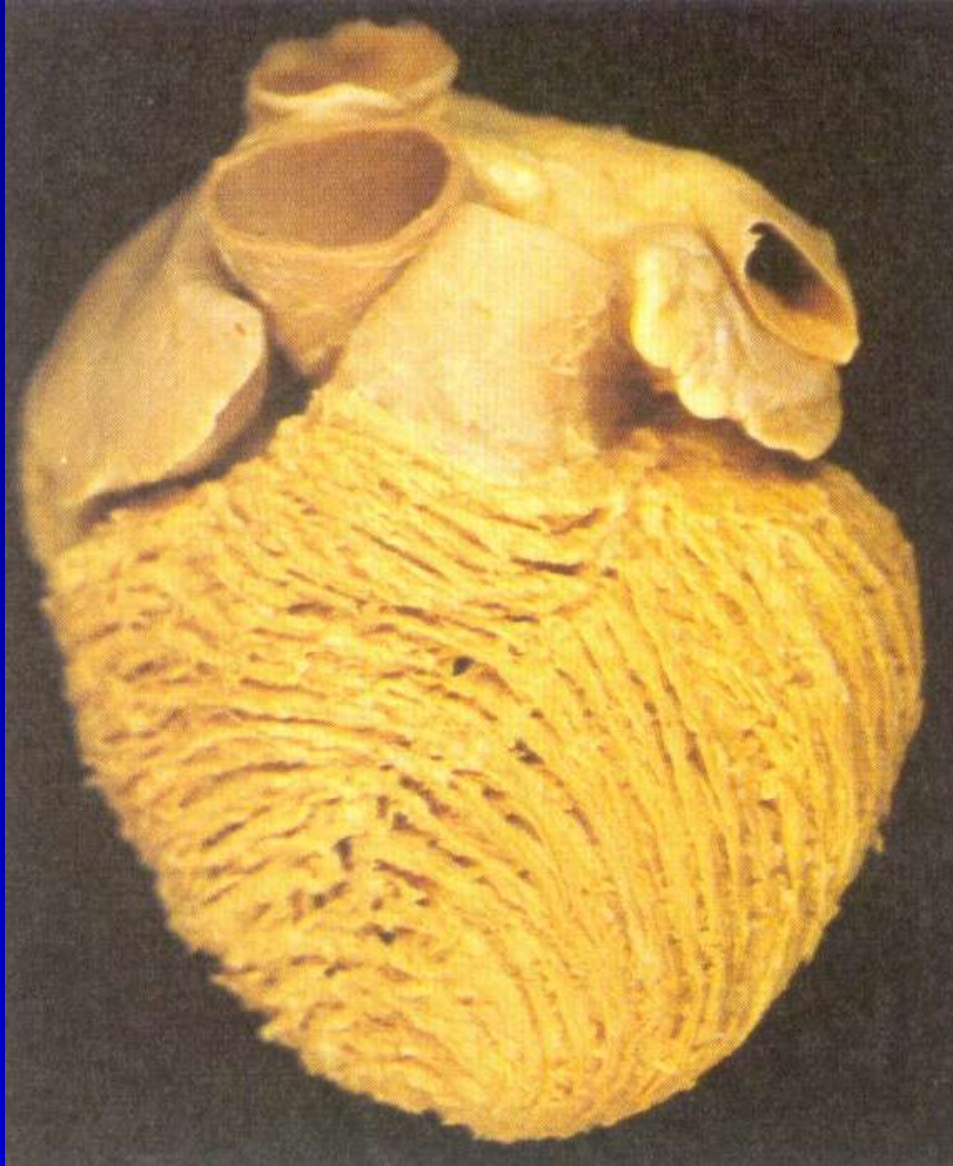
Clemente CD.
Anatomy
3rd Ed, 1987,
fig 212.







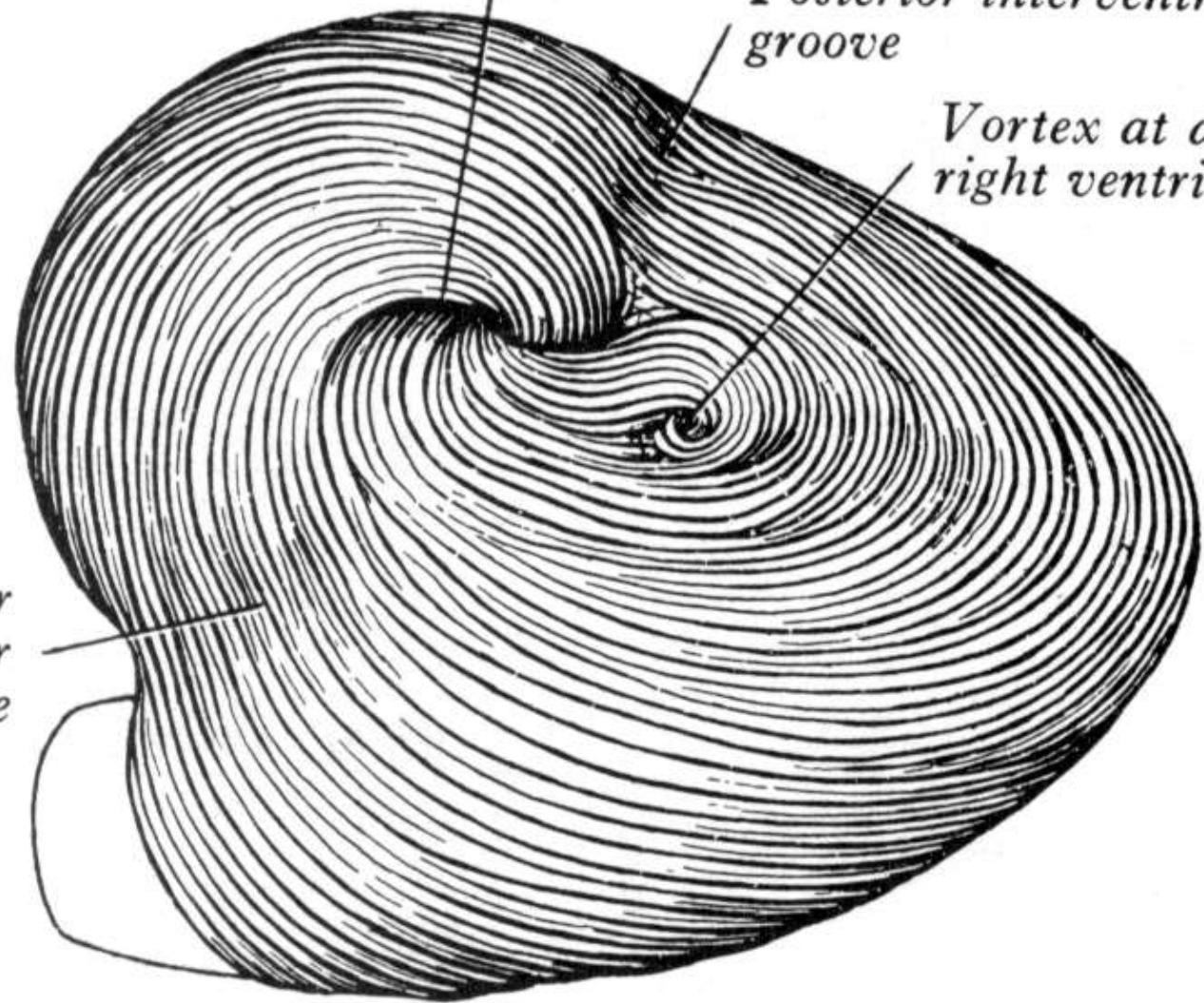




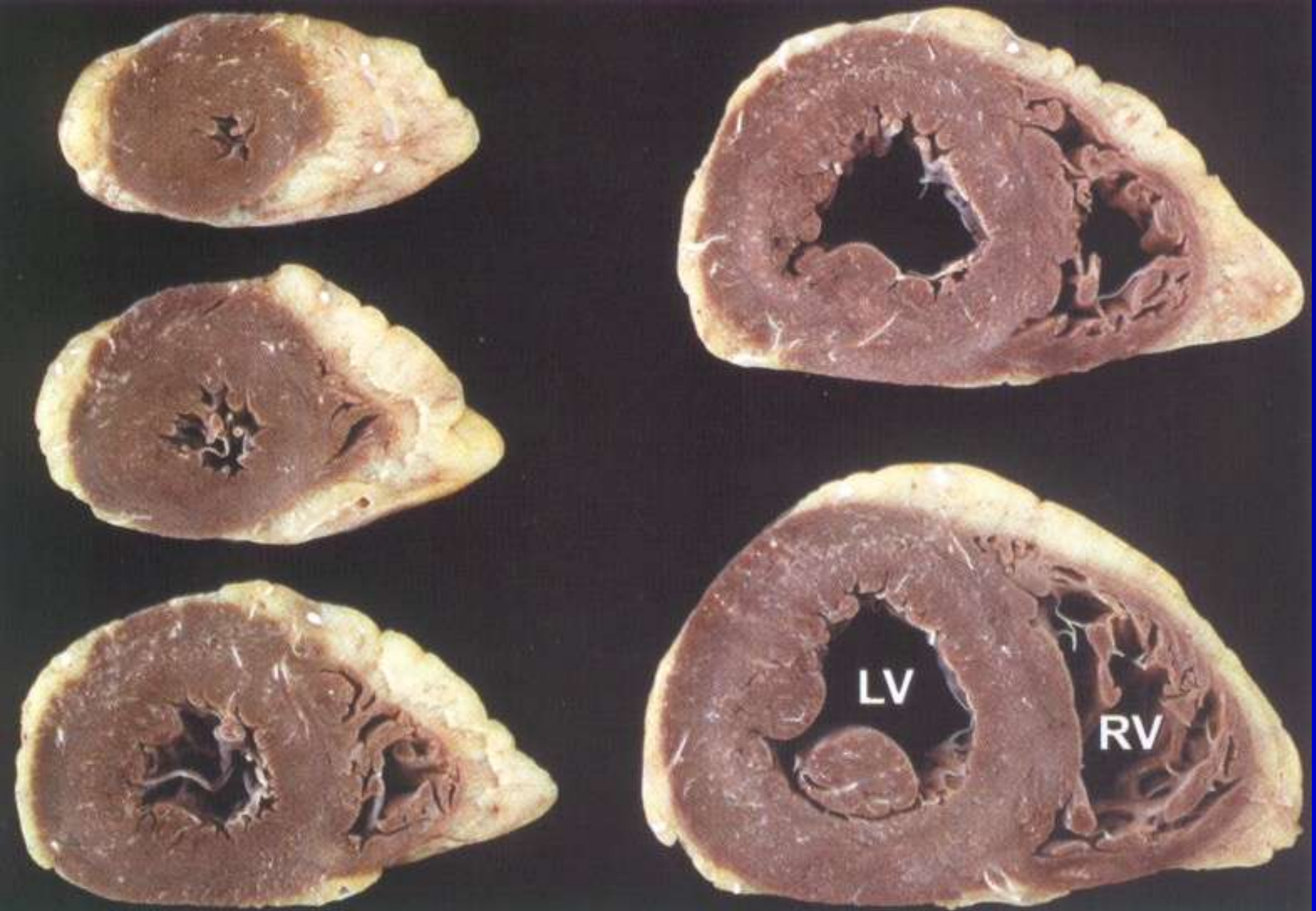
Vortex at apex of left ventricle

*Posterior interventricular
groove*

*Vortex at apex of
right ventricle*

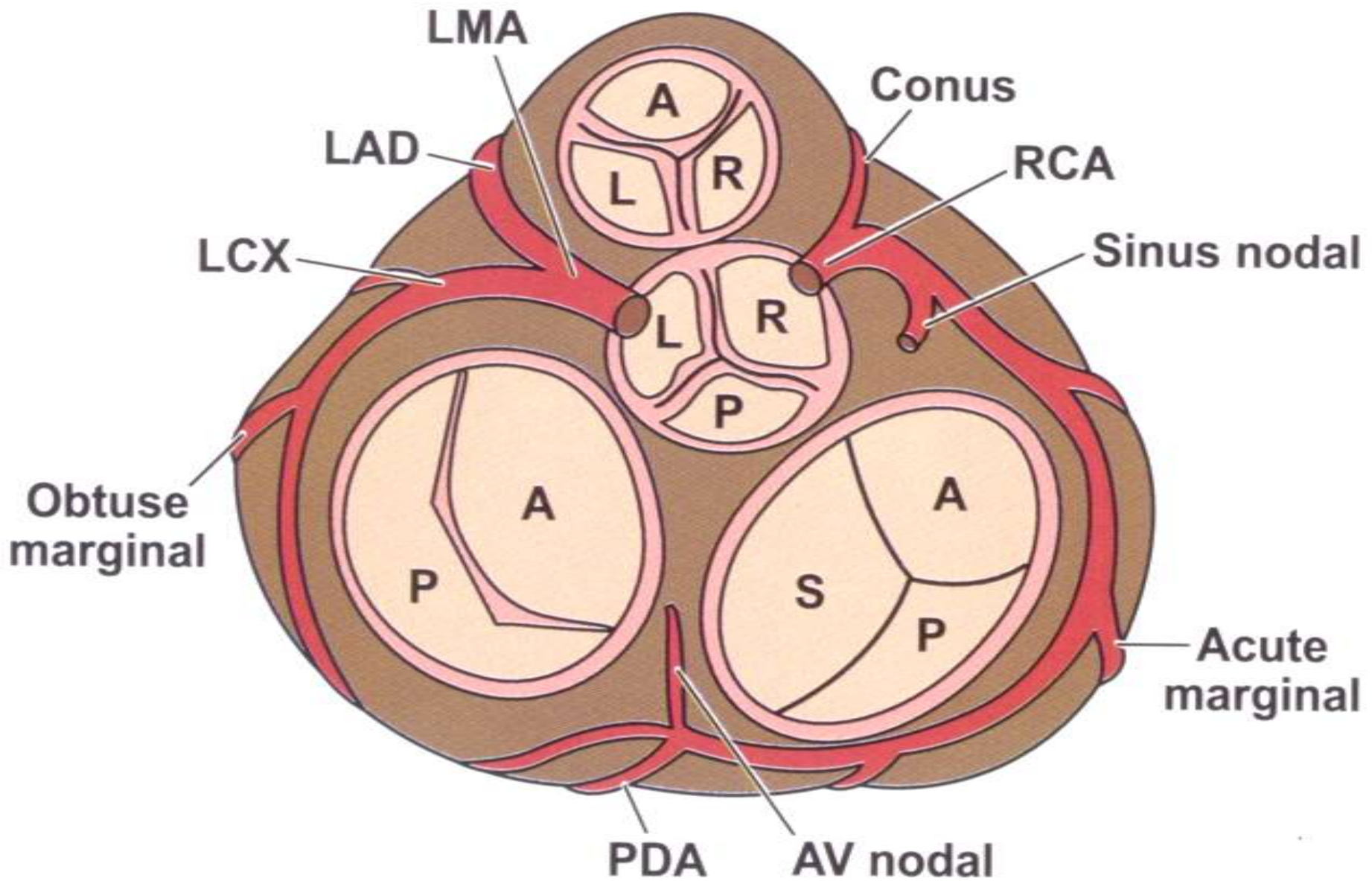


*Anterior
interventricular
groove*

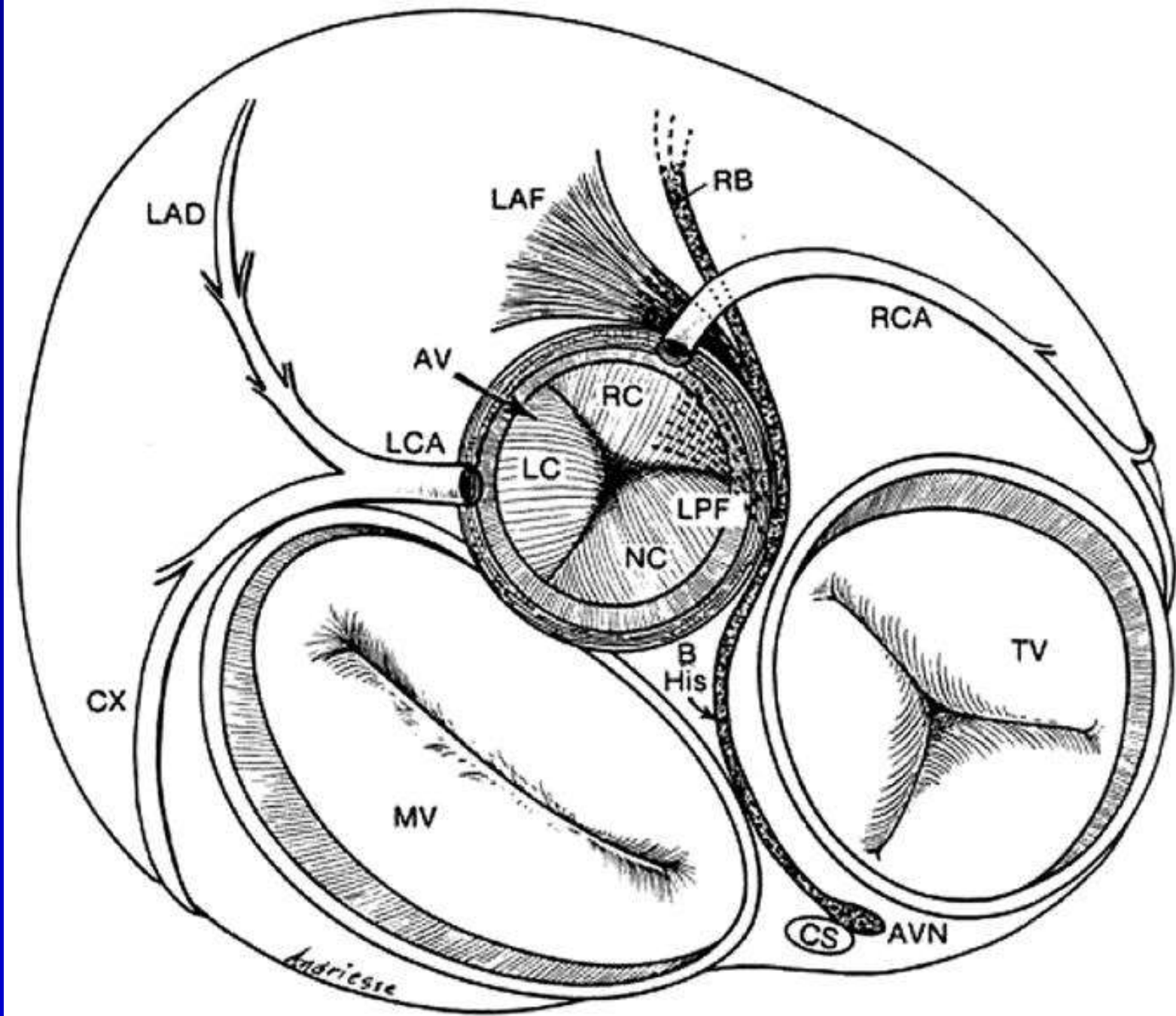


Malouf JF et al. Ch. 3, "Functional Anatomy of the Heart" in Hurst's The Heart 12th ed. 2008

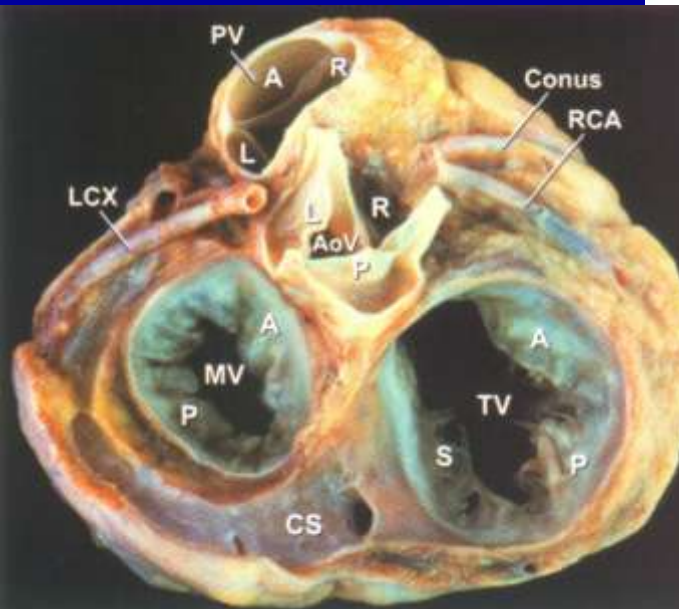
Valves



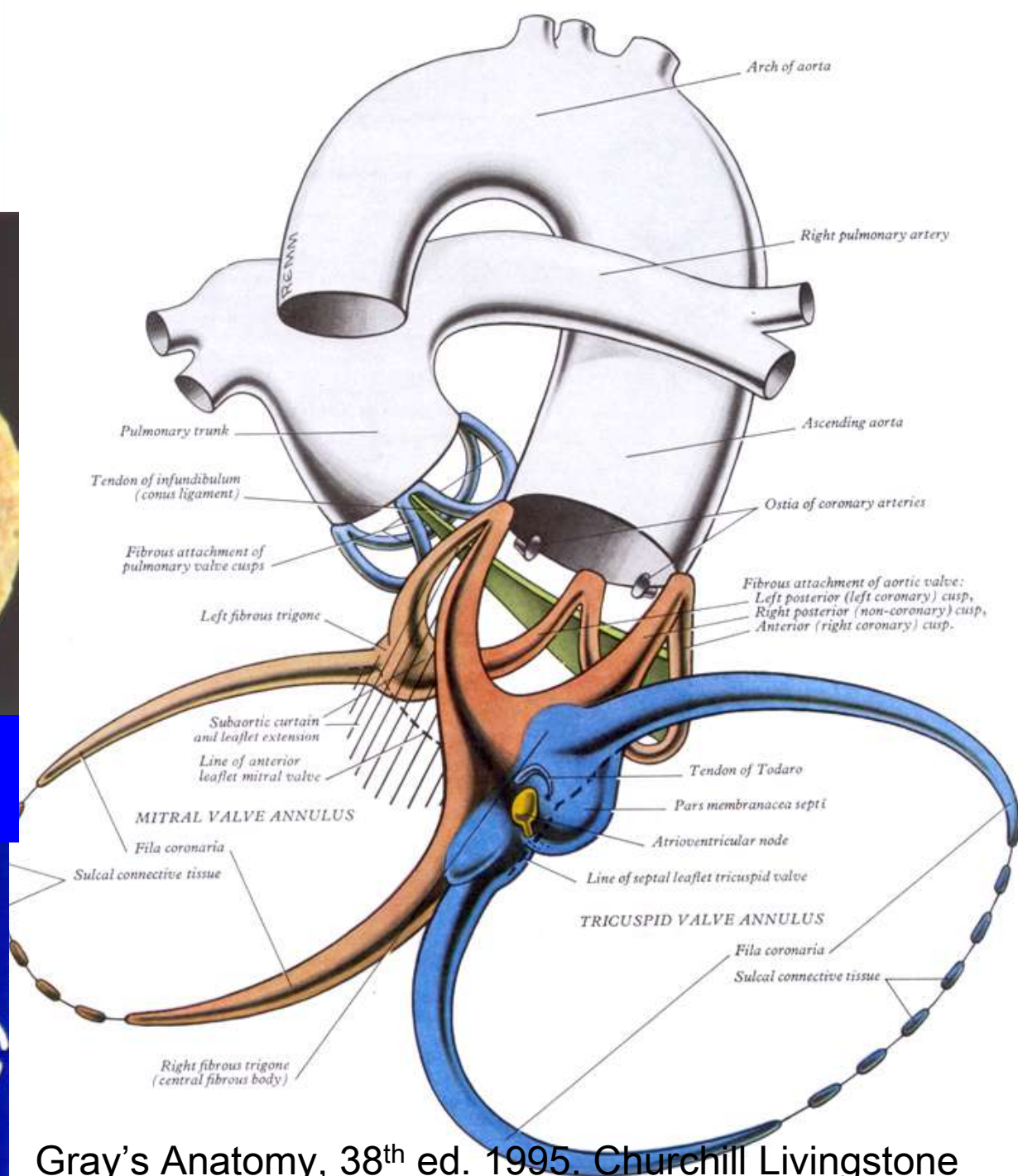
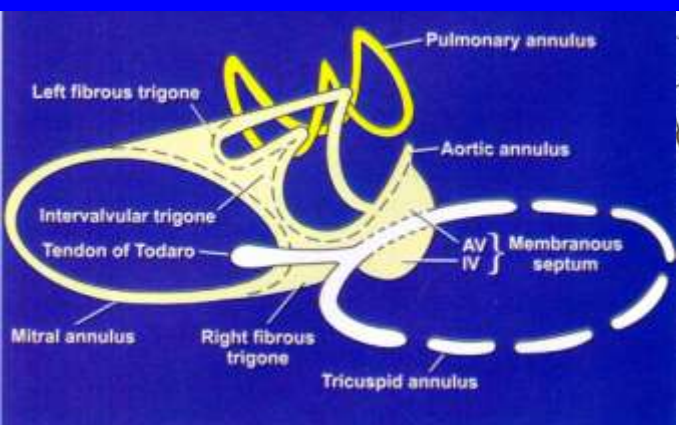
Malouf JF et al. Ch. 3, "Functional Anatomy of the Heart" in Hurst's The Heart 12th ed. 2008



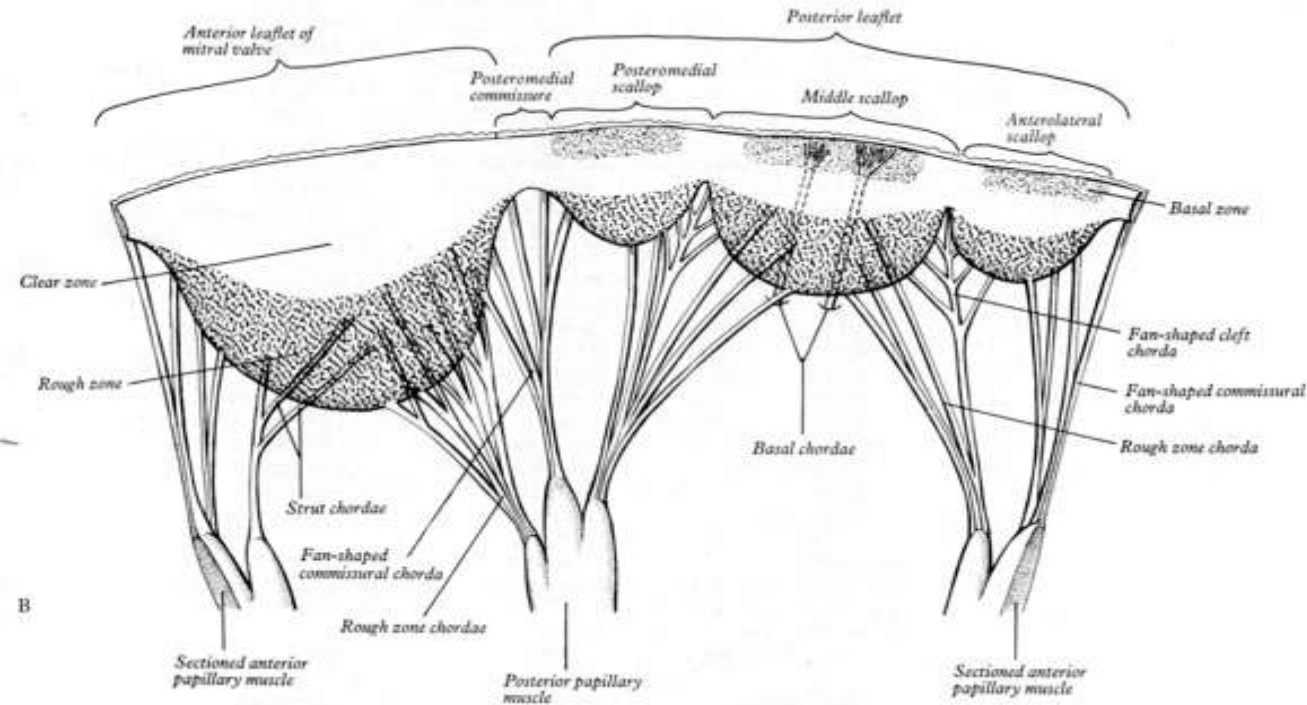
Fibrous Skeleton of the Heart



Malouf JF et al. Ch. 3, "Functional Anatomy of the Heart" in Hurst's The Heart 12th ed. 2008

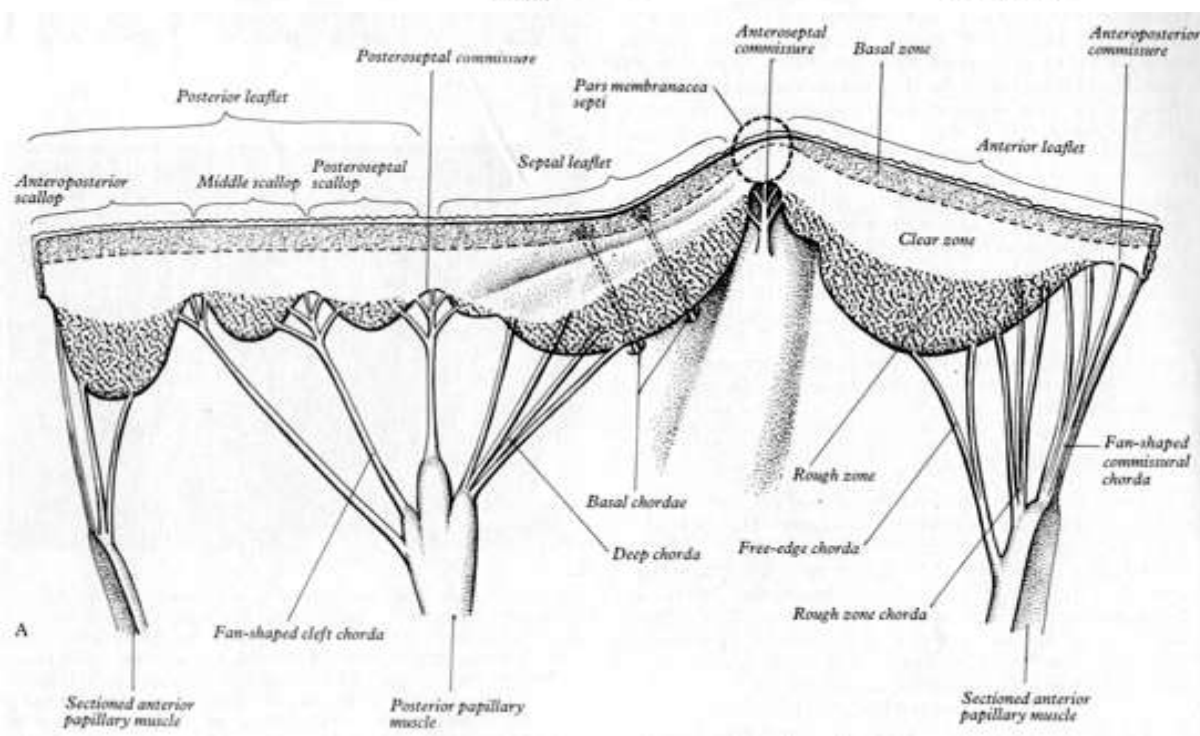


Gray's Anatomy, 38th ed. 1995. Churchill Livingstone



Mitral and Tricuspid Comparison

Mitral Valve



Tricuspid Valve

Mitral Valve Chordae Tendinae

- First-order (primary or “marginal”) – insert on leaflet free edges
- Second-order (“strut”) – insert on the ventricular surface of the leaflets, usually near the junction between the rough and smooth zones
- Third-order – arise directly from the LV wall

Mitral Valve Apparatus

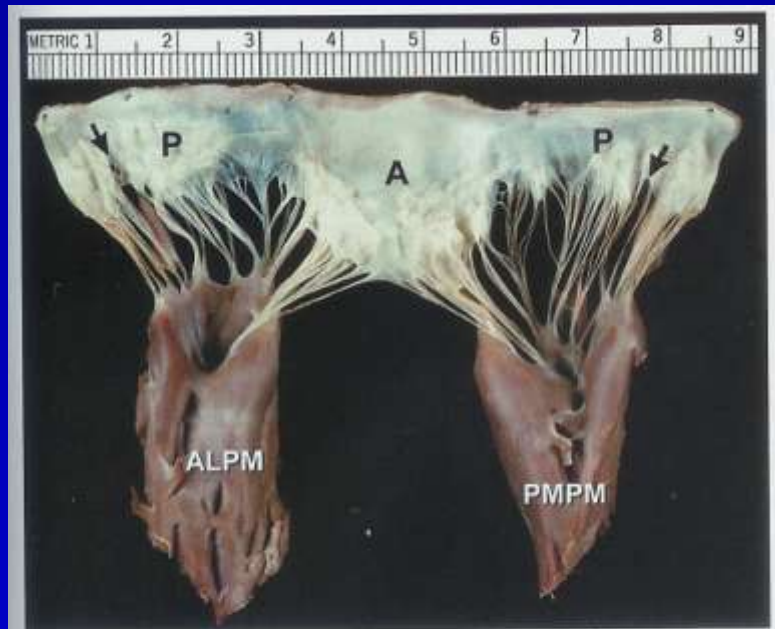


FIGURE 3-25. Gross anatomy of the mitral valve and papillary muscles-chordal apparatus, as demonstrated in an excised and unfolded valve. Each commissure overlies a papillary muscle. Arrows point to minor commissures. A, anterior leaflet; ALPM, anterolateral papillary muscle; P, posterior leaflet; PMPM, posteromedial papillary muscle.

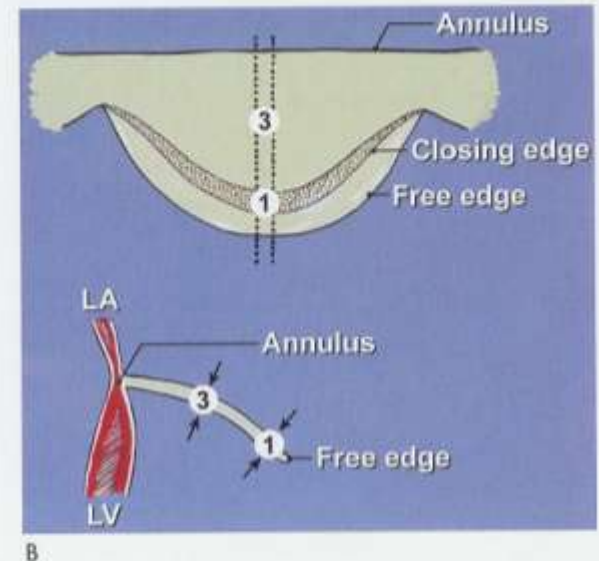
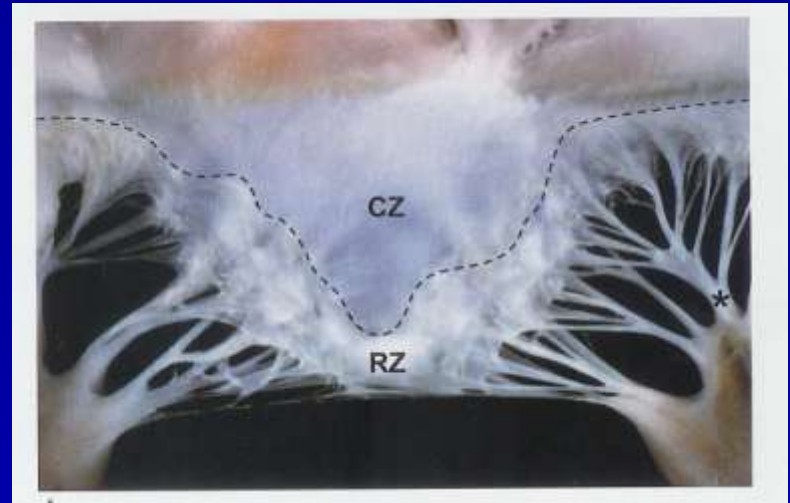
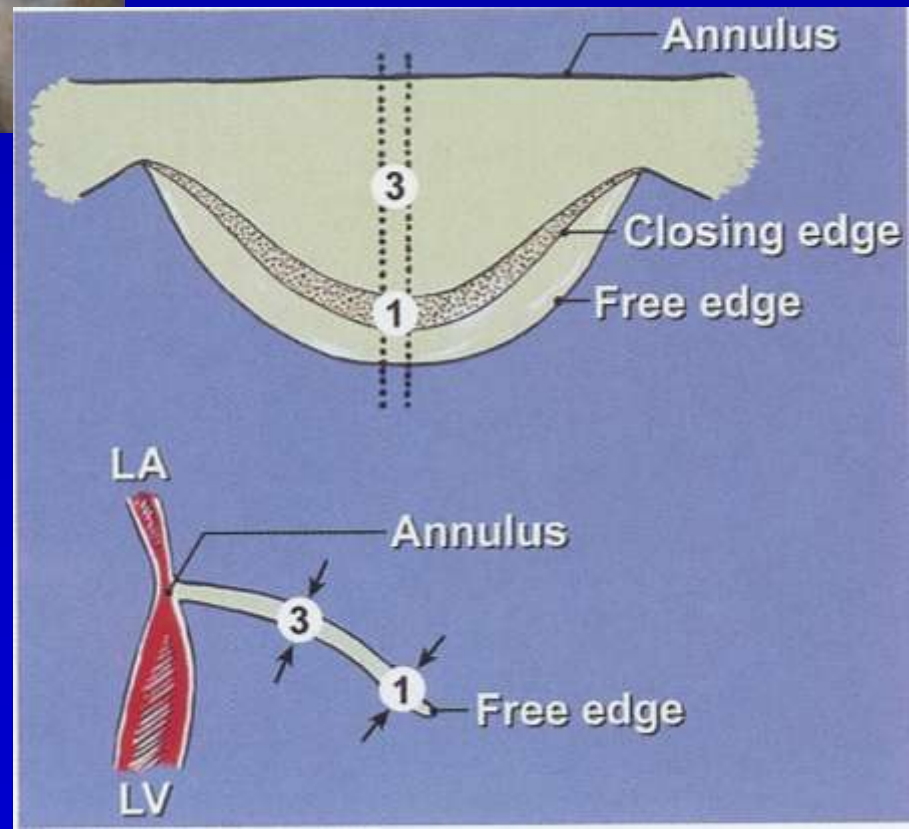
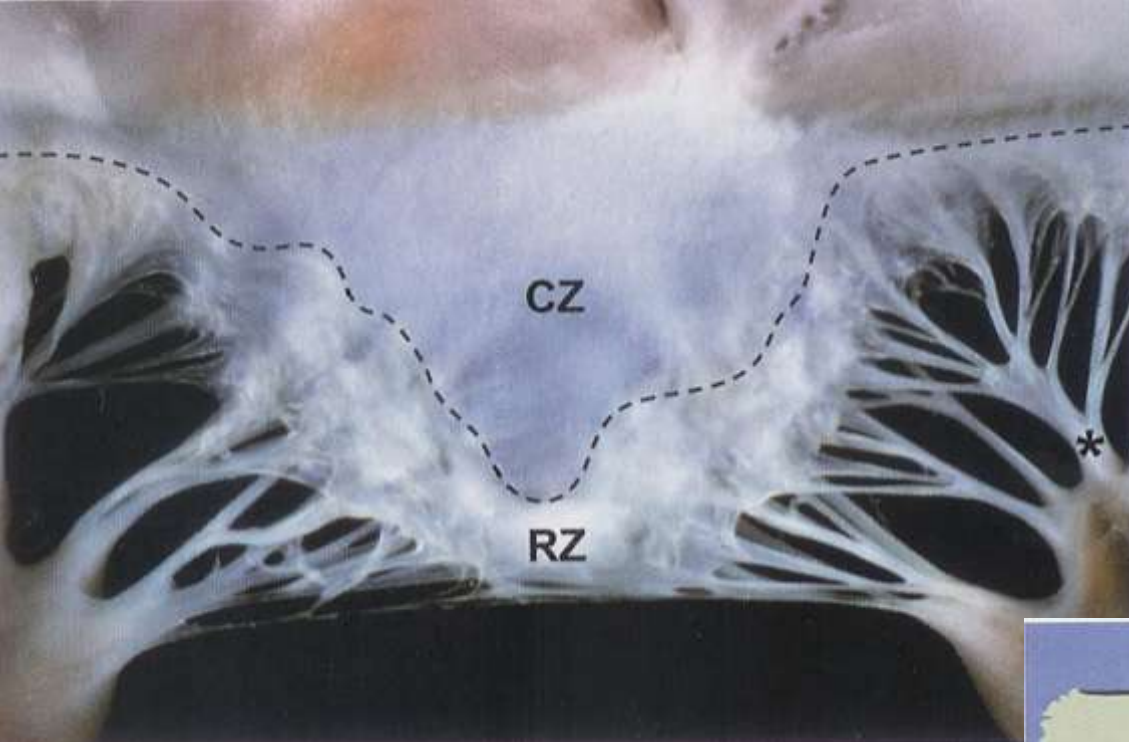
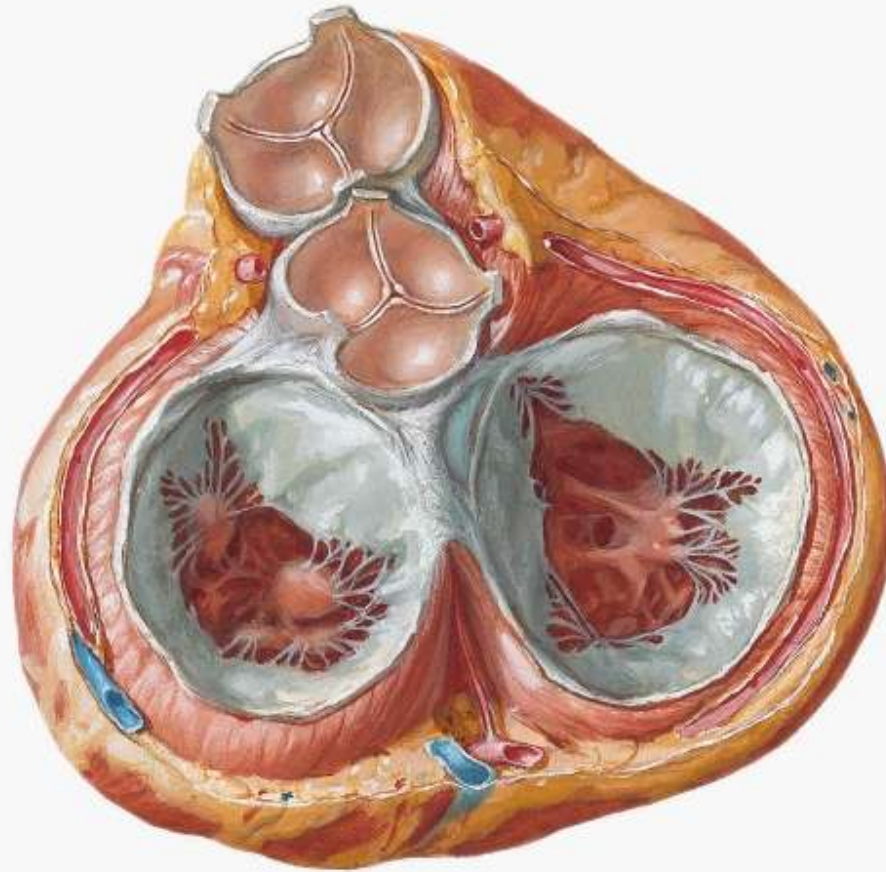


FIGURE 3-26. Components of the mitral valve. **A.** Each leaflet has a large clear zone (CZ) and a smaller rough zone (RZ) between its free edge and closing edge (dotted line). A fanlike commissural chordae tendinea (*) connects the tip of the papillary muscle to the commissure. **B.** Schematic diagram of an open anterior mitral leaflet comparable to **A.** Section obtained along the dotted lines shows the relationship of the mitral annulus and free edge to the closing edge.

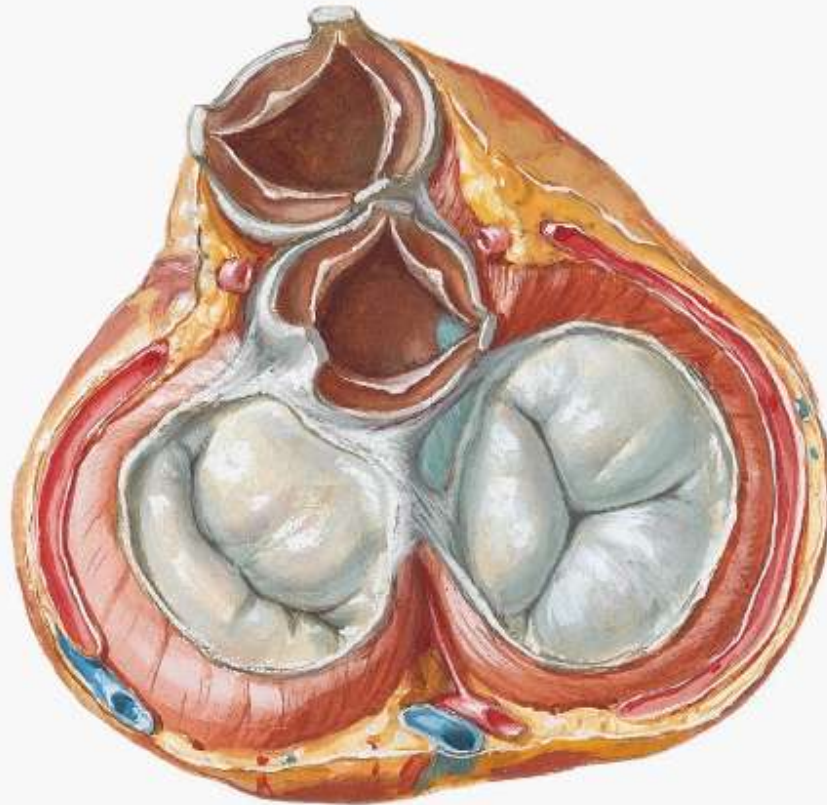


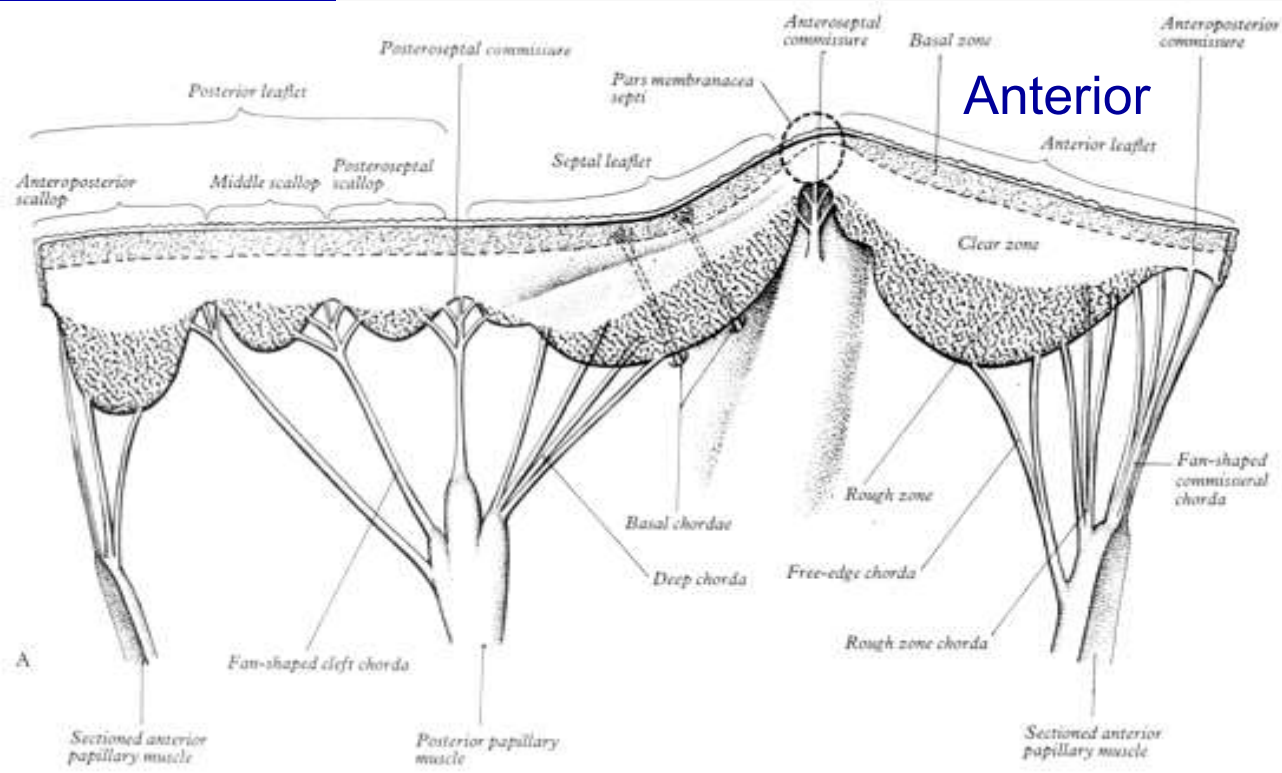
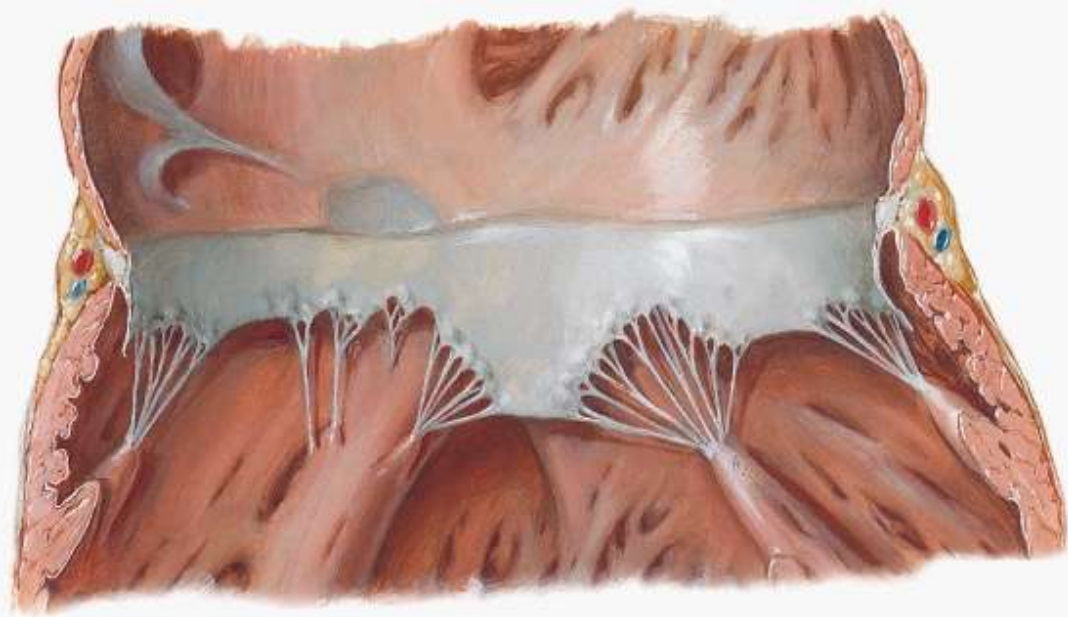
Malouf JF et al. Ch. 3, "Functional Anatomy of the Heart" in Hurst's The Heart 12th ed. 2008

Valves of Heart in Diastole



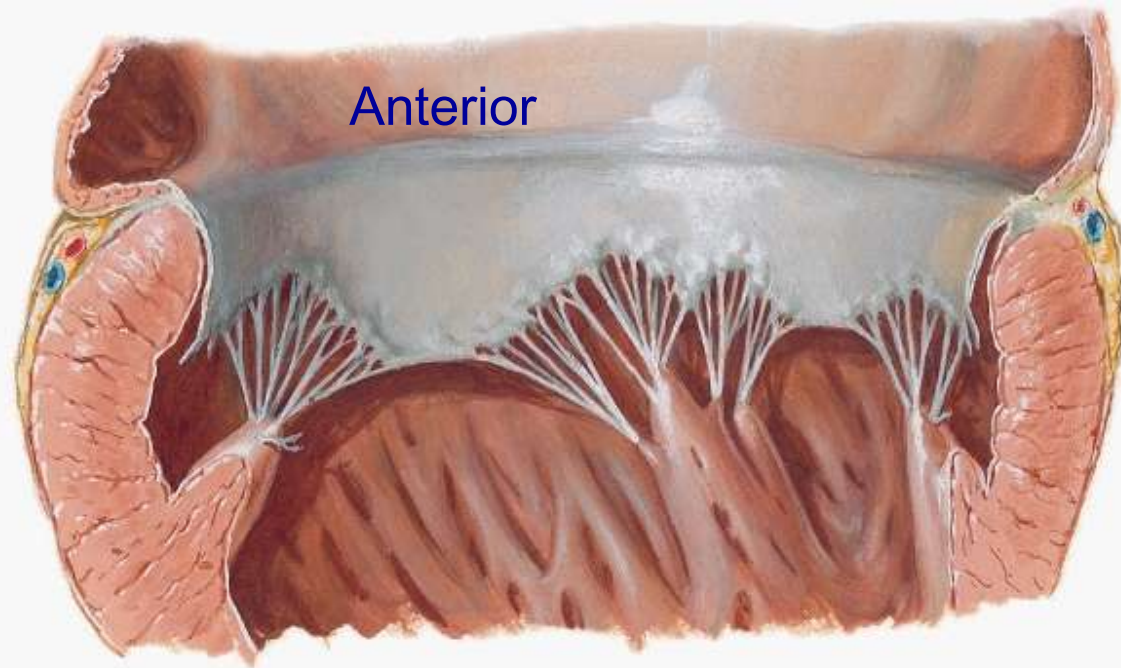
Valves of Heart in Systole



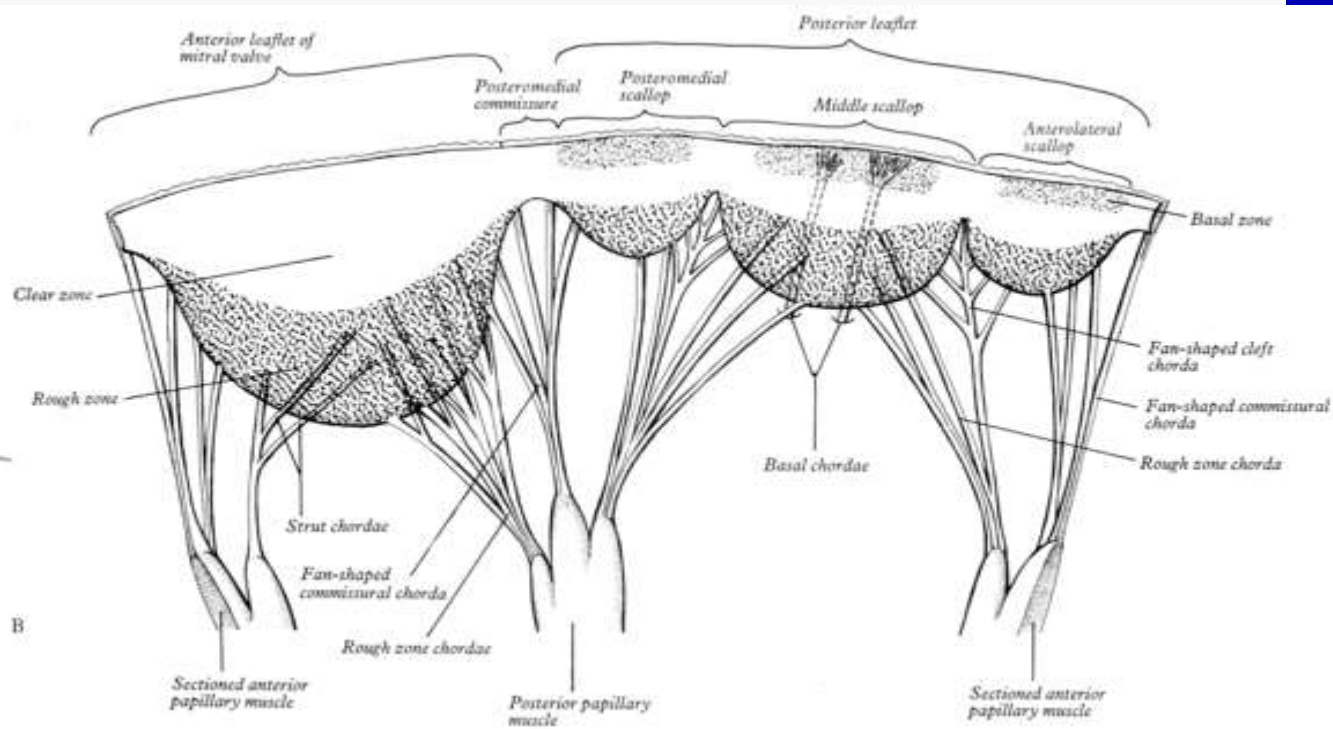


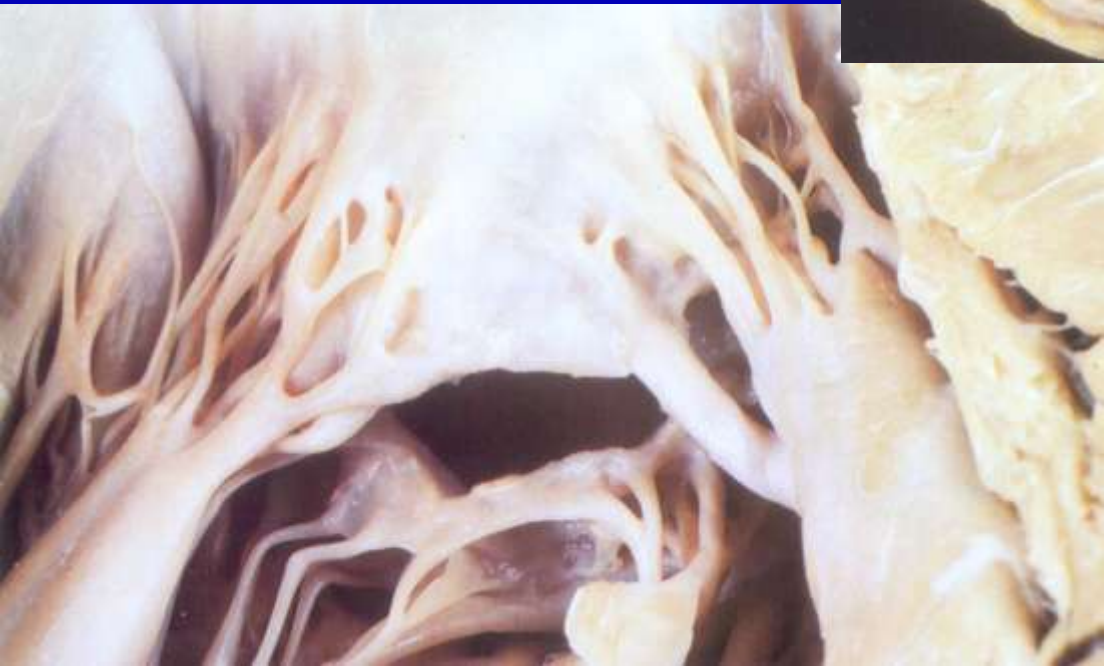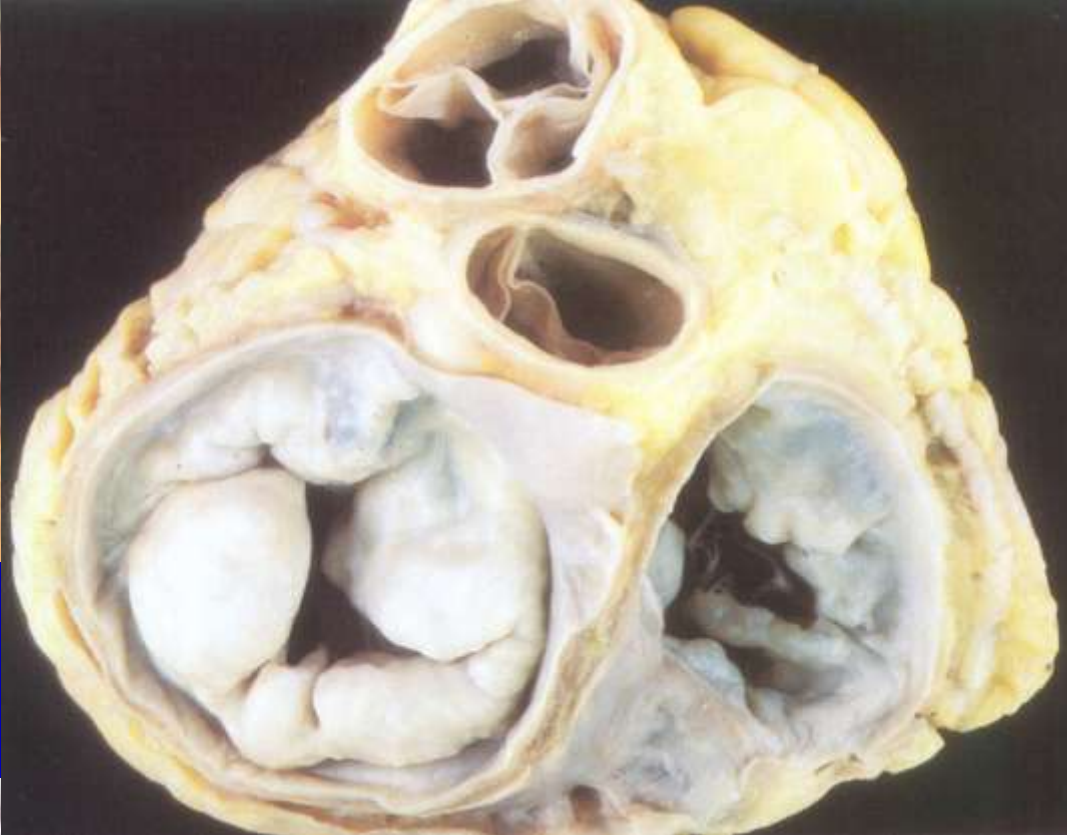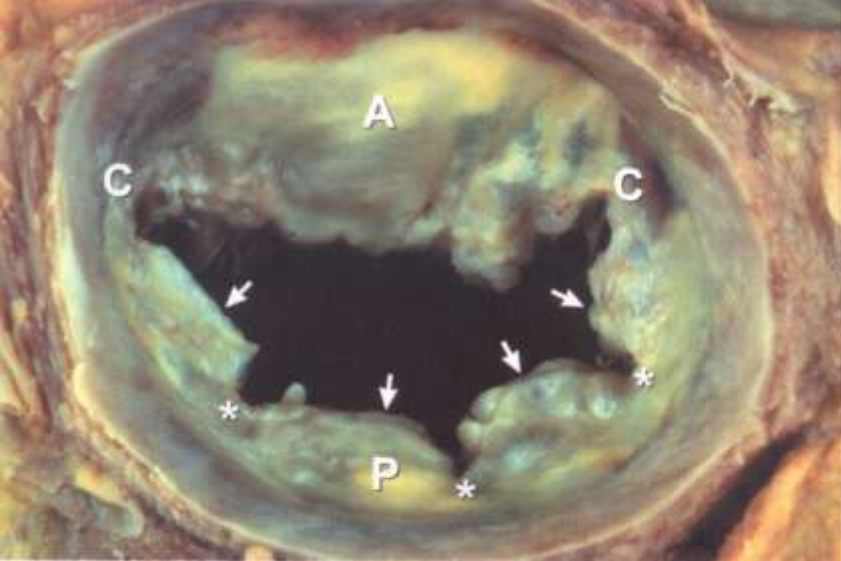
F. Netter M.D.
© IGV

Tricuspid Valve



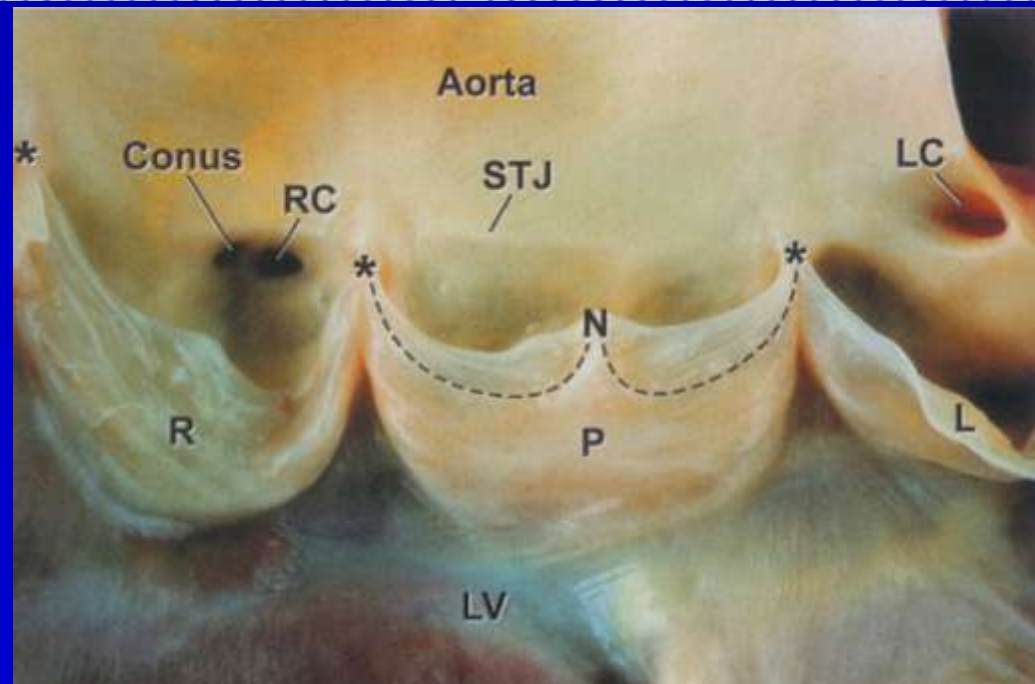
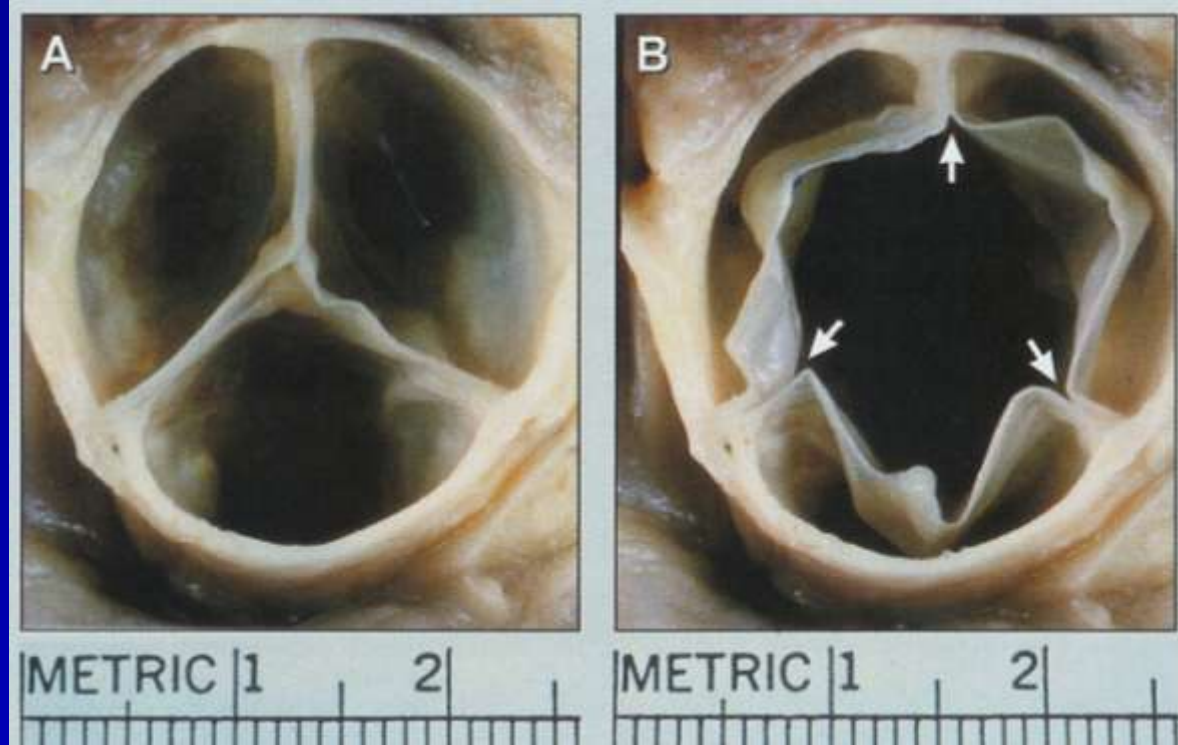
Mitral Valve





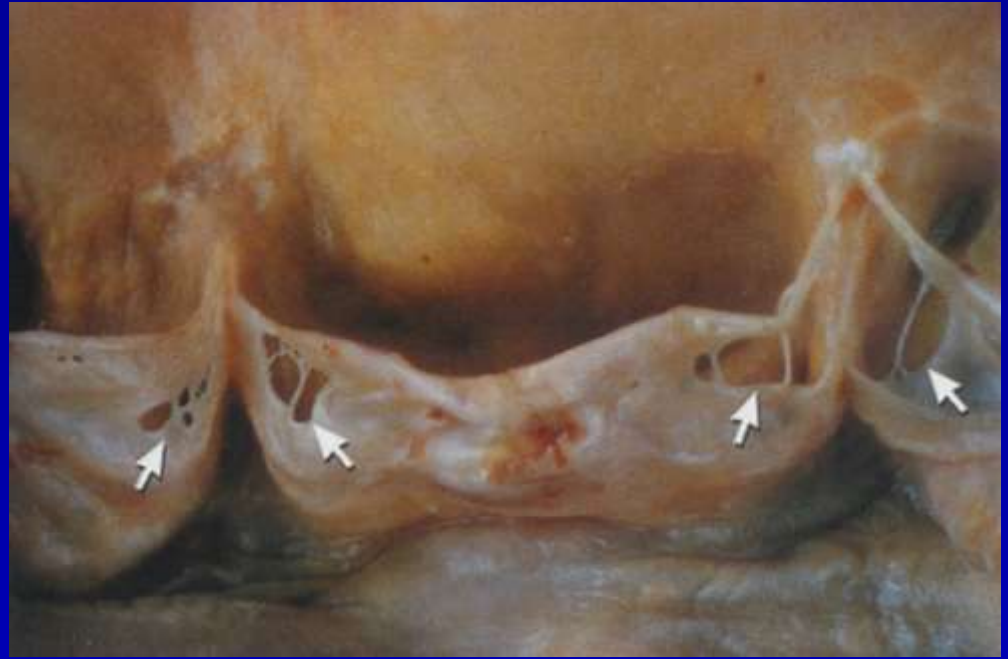
Malouf JF et al. Ch. 3, "Functional Anatomy of the Heart" in Hurst's The Heart 11th ed. 2004

Aortic Valve

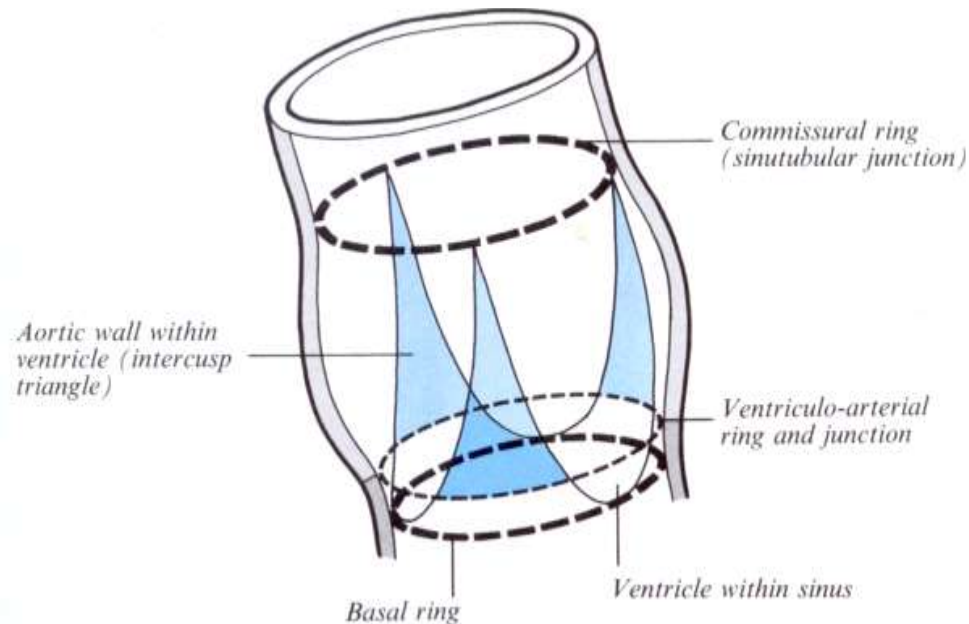
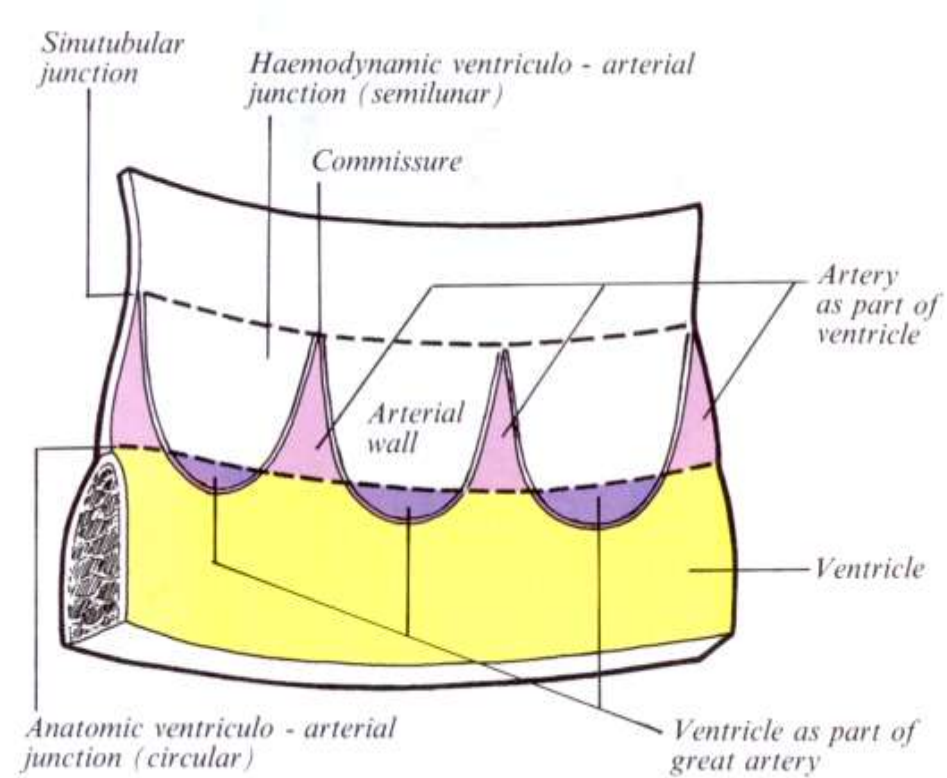
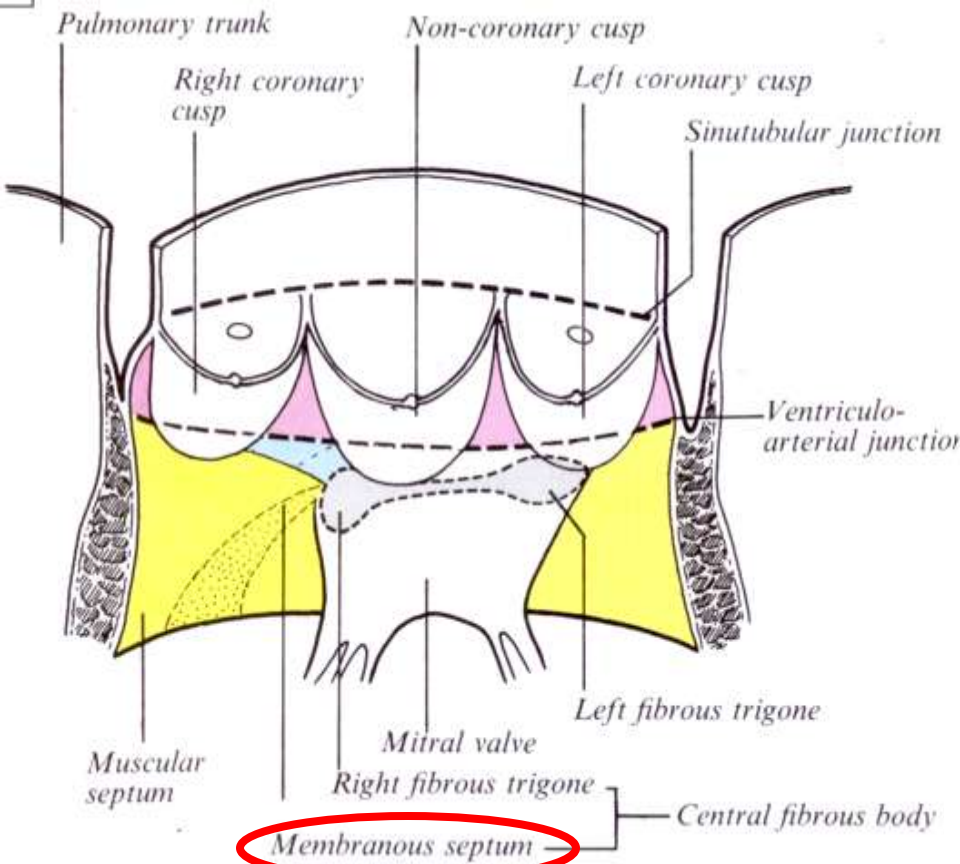


Malouf JF et al. Ch. 3, "Functional Anatomy of the Heart" in Hurst's The Heart 12th ed. 2008

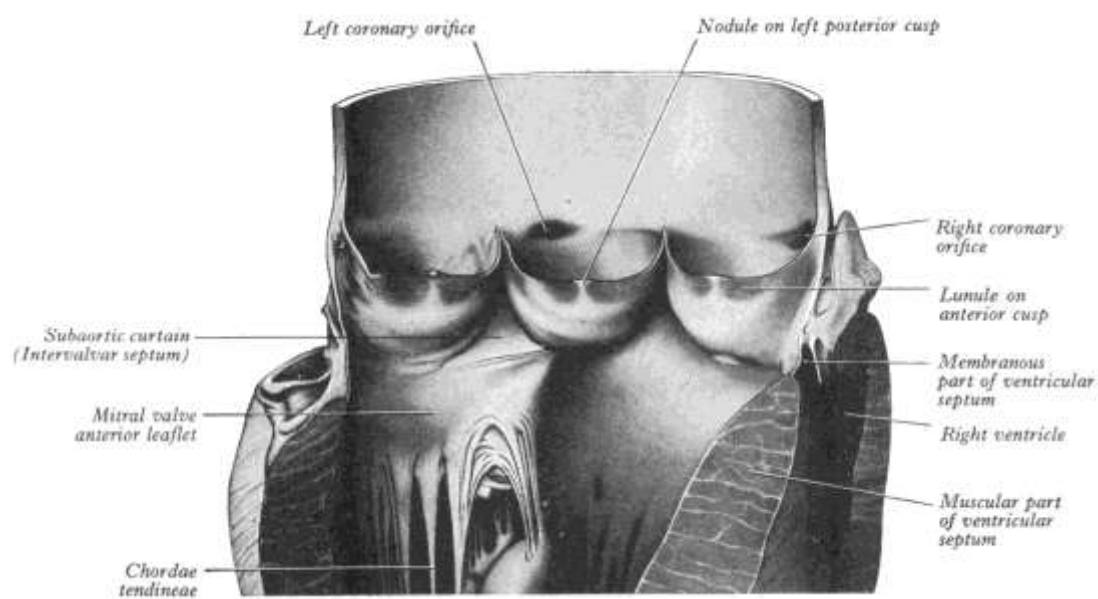
Aortic Valve



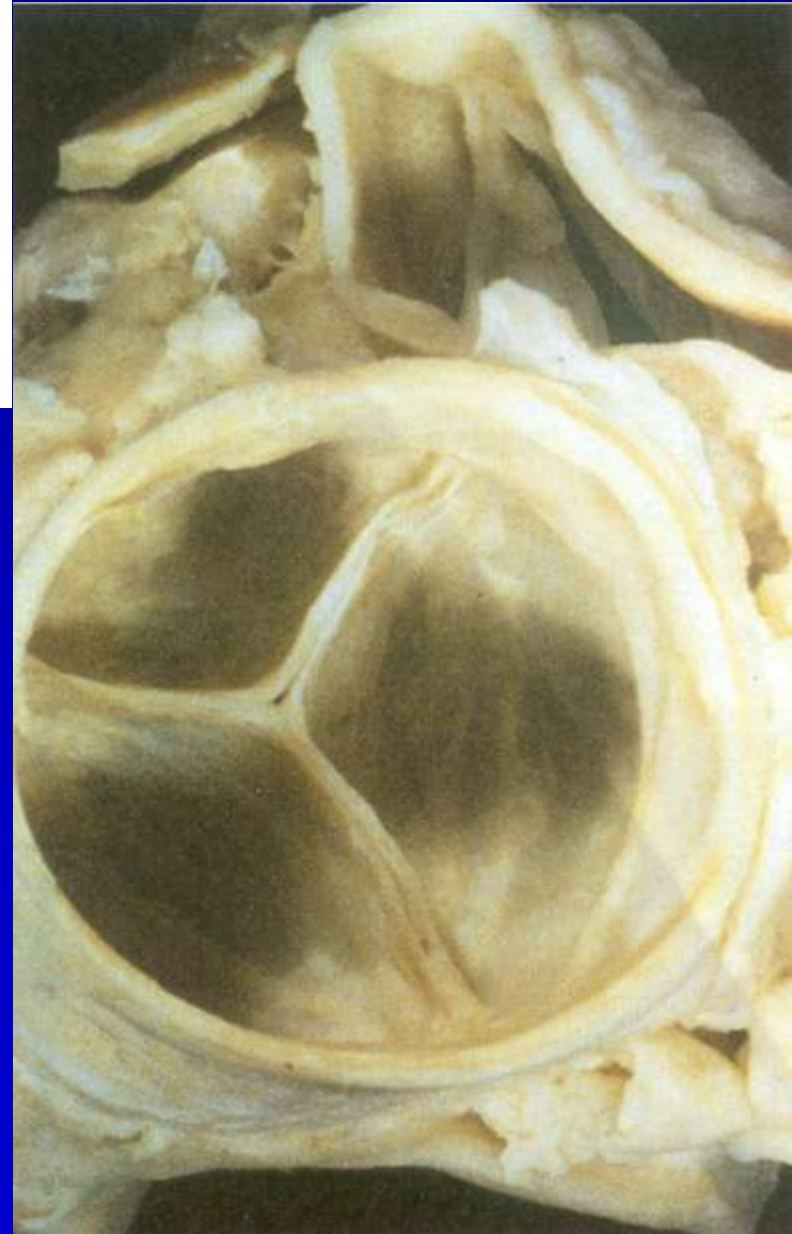Age-related fenestrations in the lunulae; do not result in clinically significant regurgitation



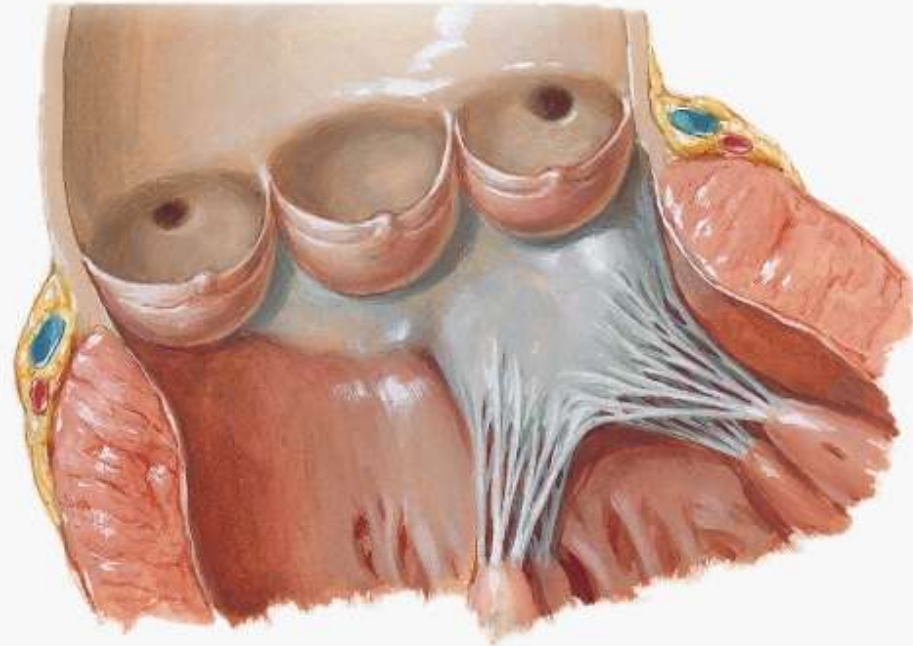
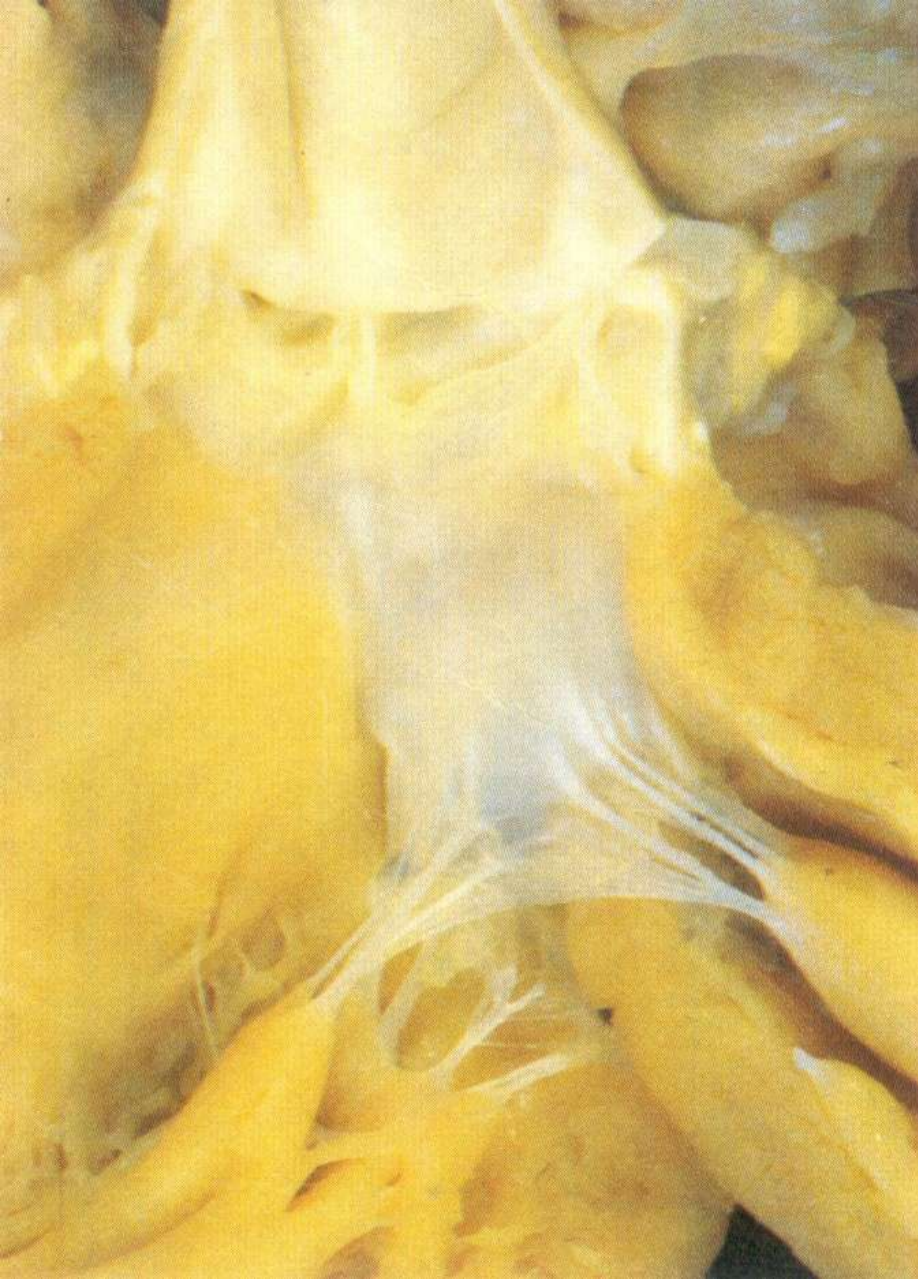Aortic Valve



Aortic Valve

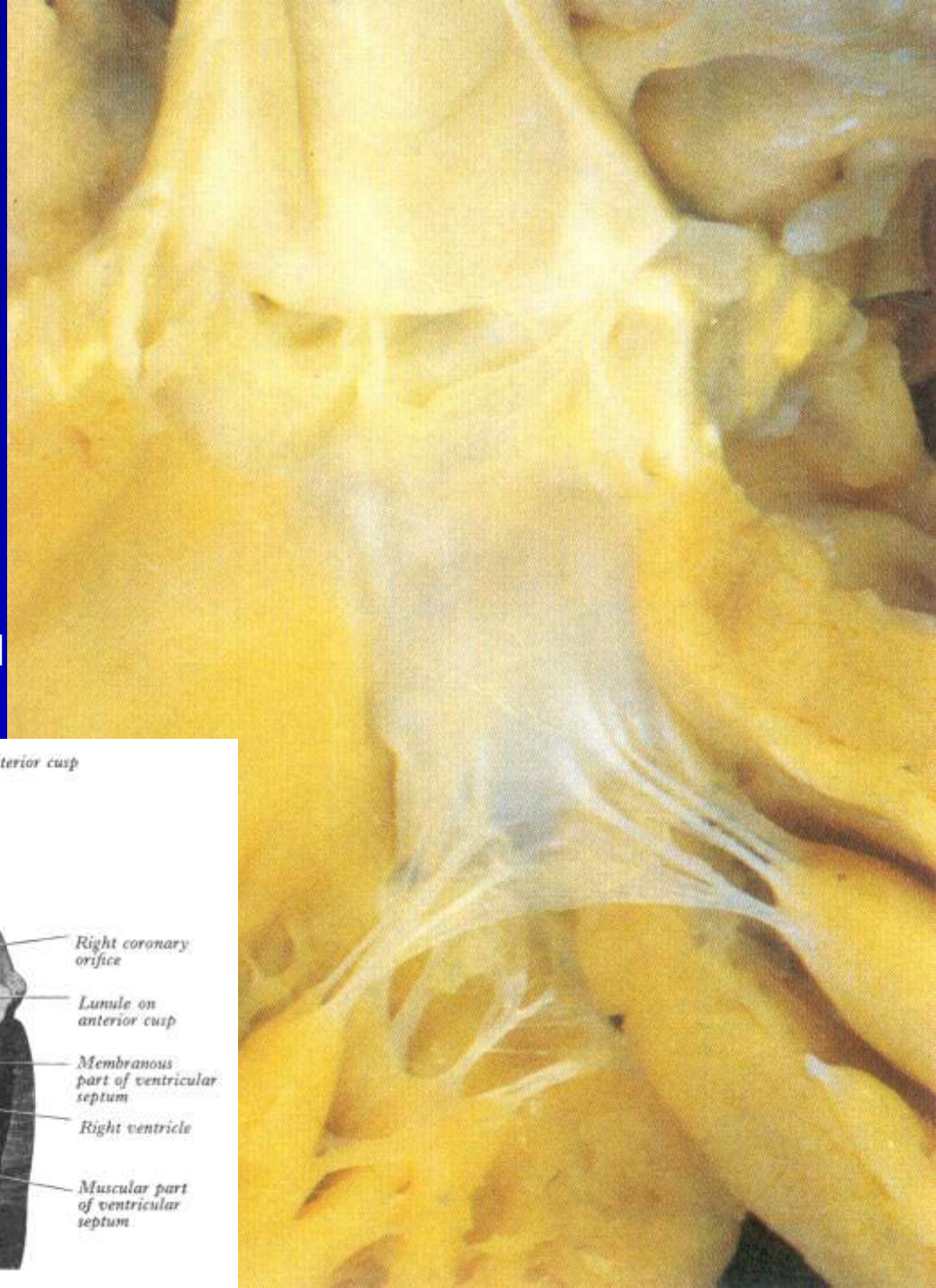
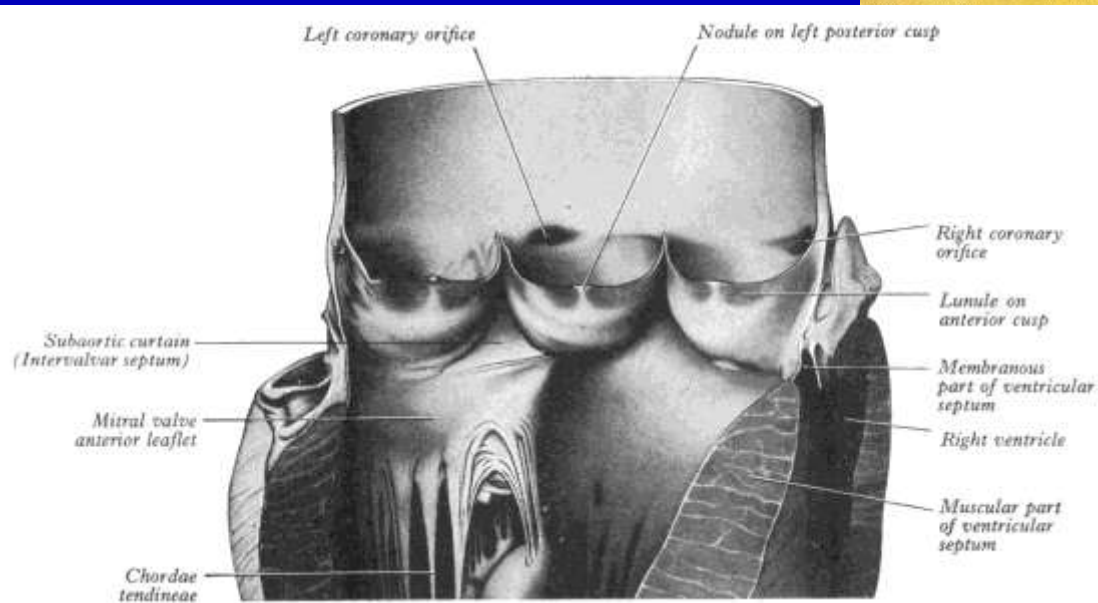


Aortic Valve

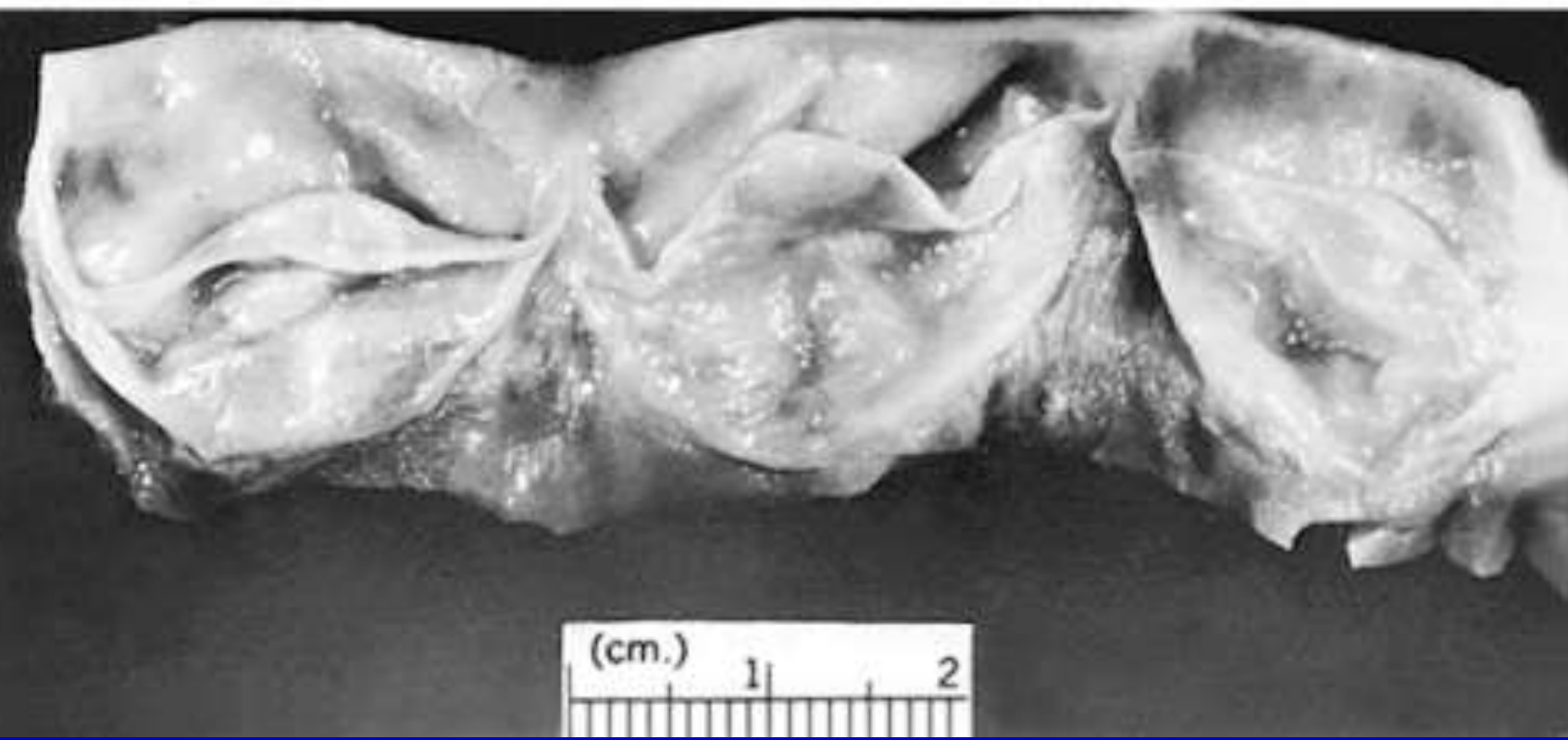
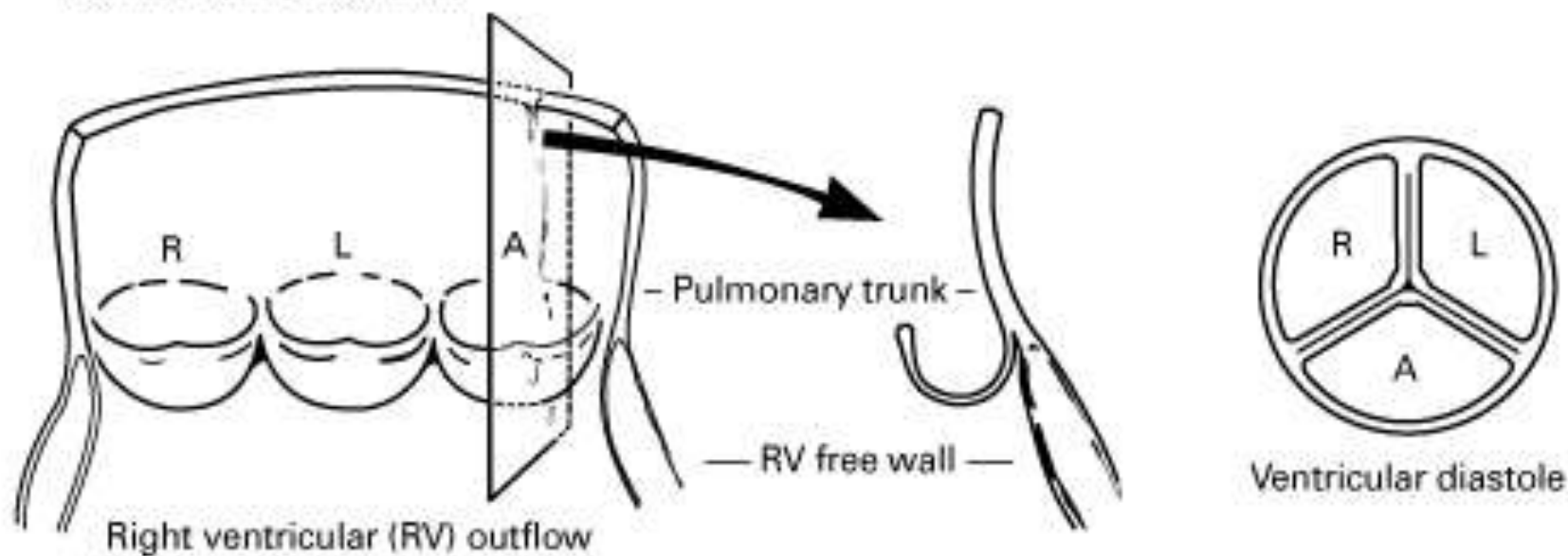


Aortic and Mitral Valve Relation

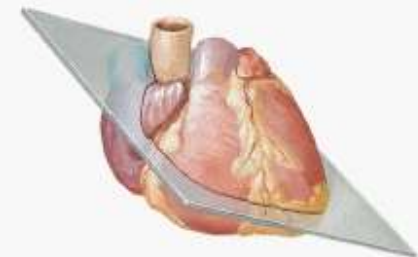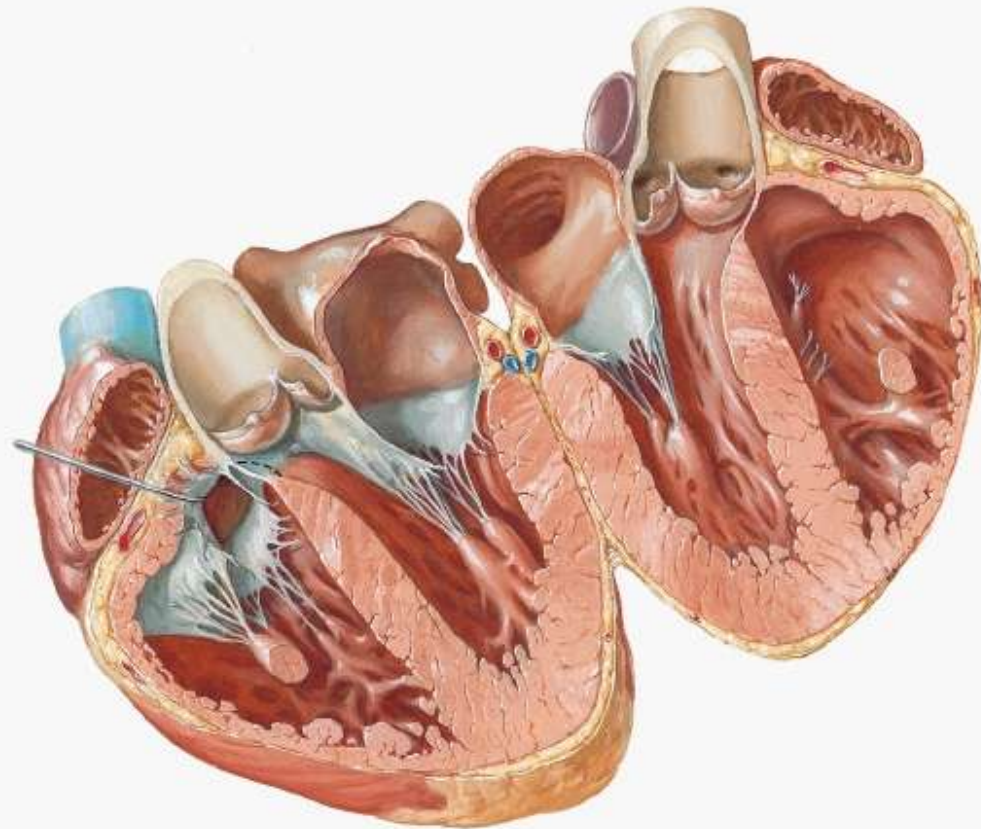
Gray's Anatomy, 38th ed. 1995. Churchill Livingstone; p. 1489, 90



Normal Pulmonic Valve



Atria, Ventricles and Interventricular Septum



b

Right brachiocephalic vein

Right lung

Arch of aorta

Right auricle

Right atrium

Diaphragm

Liver

Left lung

Pulmonary trunk

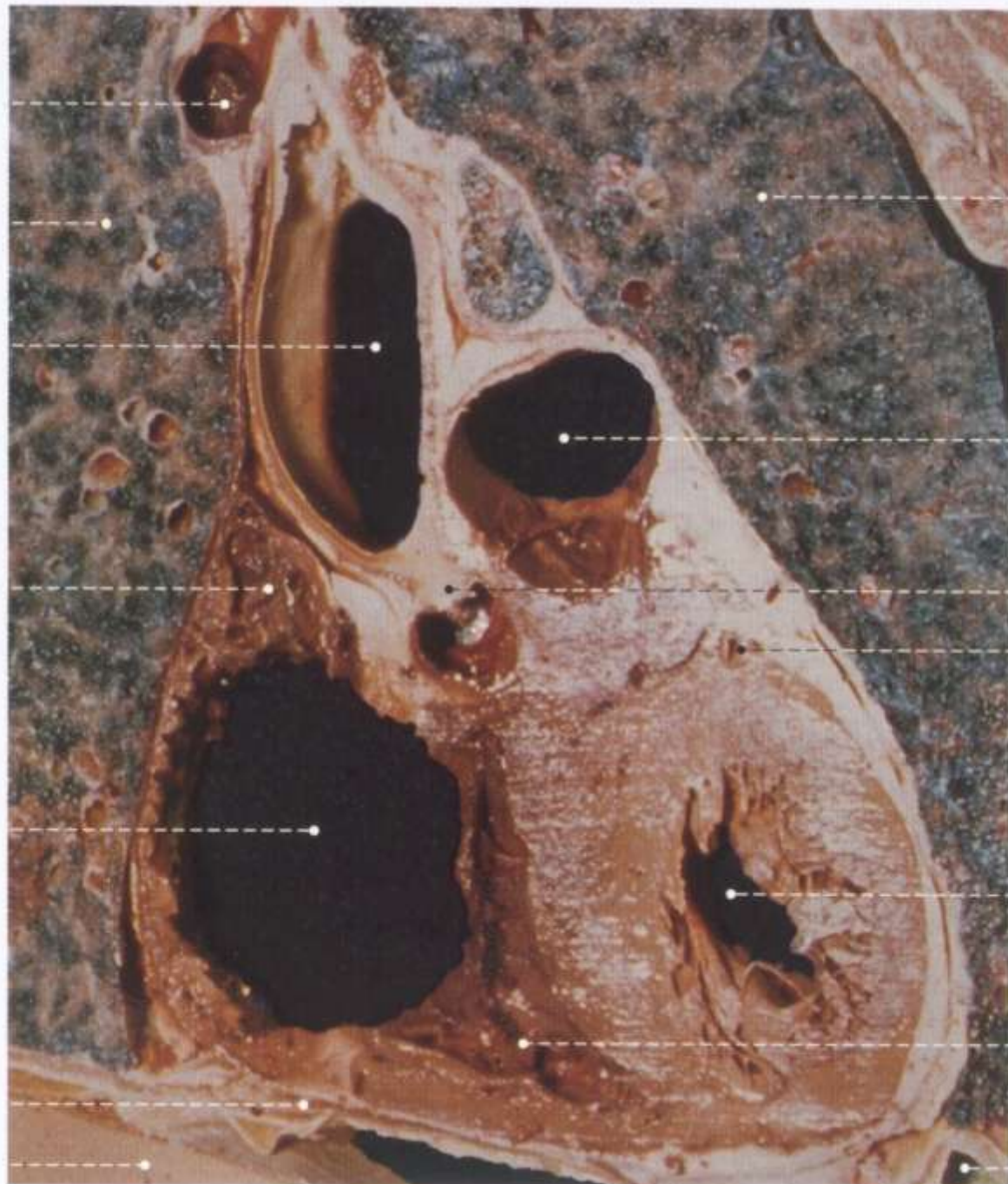Aortic valve

Circumflex branch
of left coronary artery

Left ventricle

Right ventricle

Fundus of stomach



b

Right brachiocephalic vein

Right lung

(Atherosclerotic plaque)

Ascending aorta

Right auricle

Superior vena cava

Semilunar cusps
of aortic valve

Right atrium

Right ventricle

Right coronary artery,
Small cardiac vein

Liver

Left lung

Arch of aorta

Pulmonary trunk

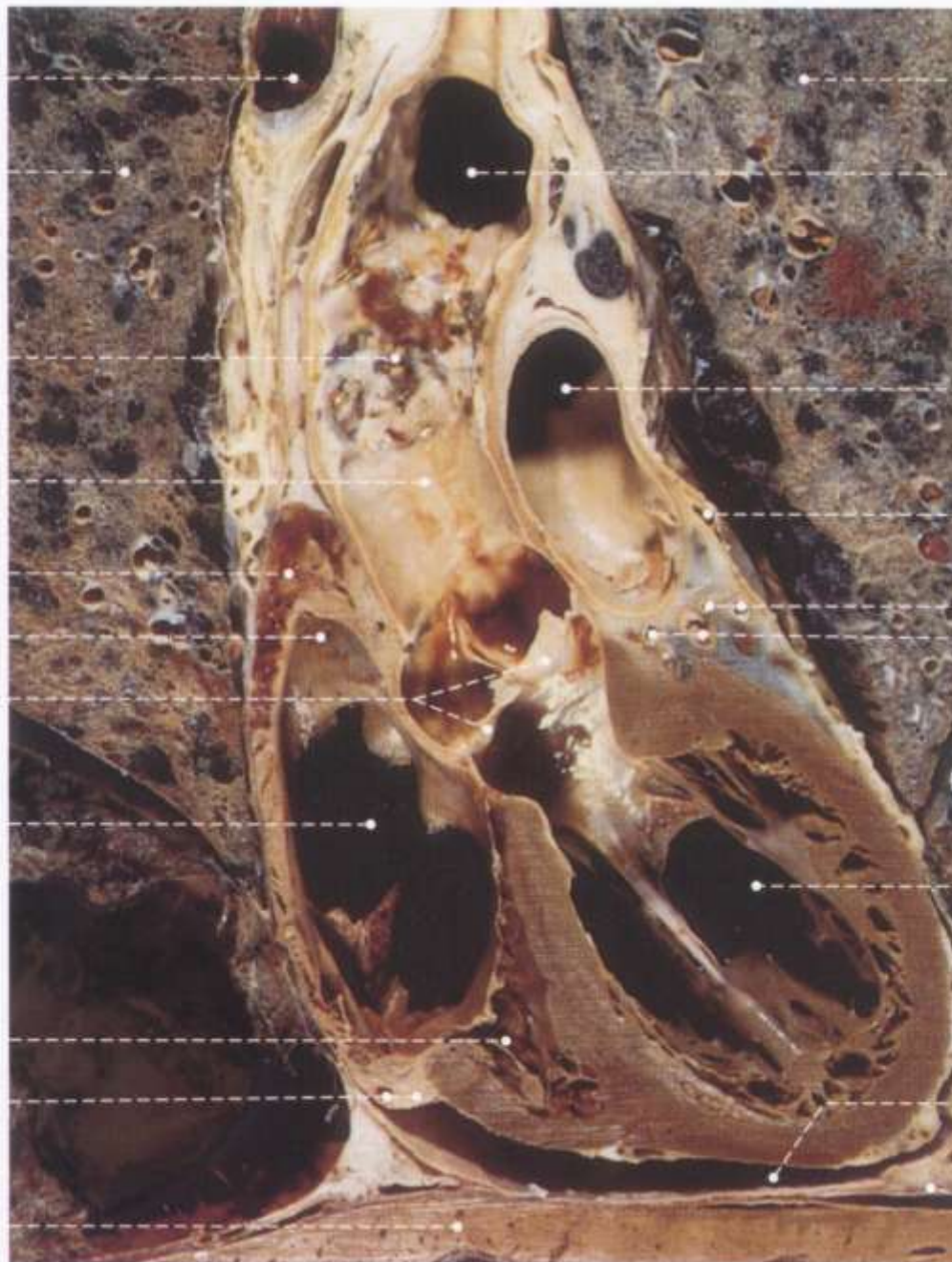
Left auricle

Left coronary artery, Great cardiac vein
– Circumflex branches
– Anterior interventricular branches

Left ventricle

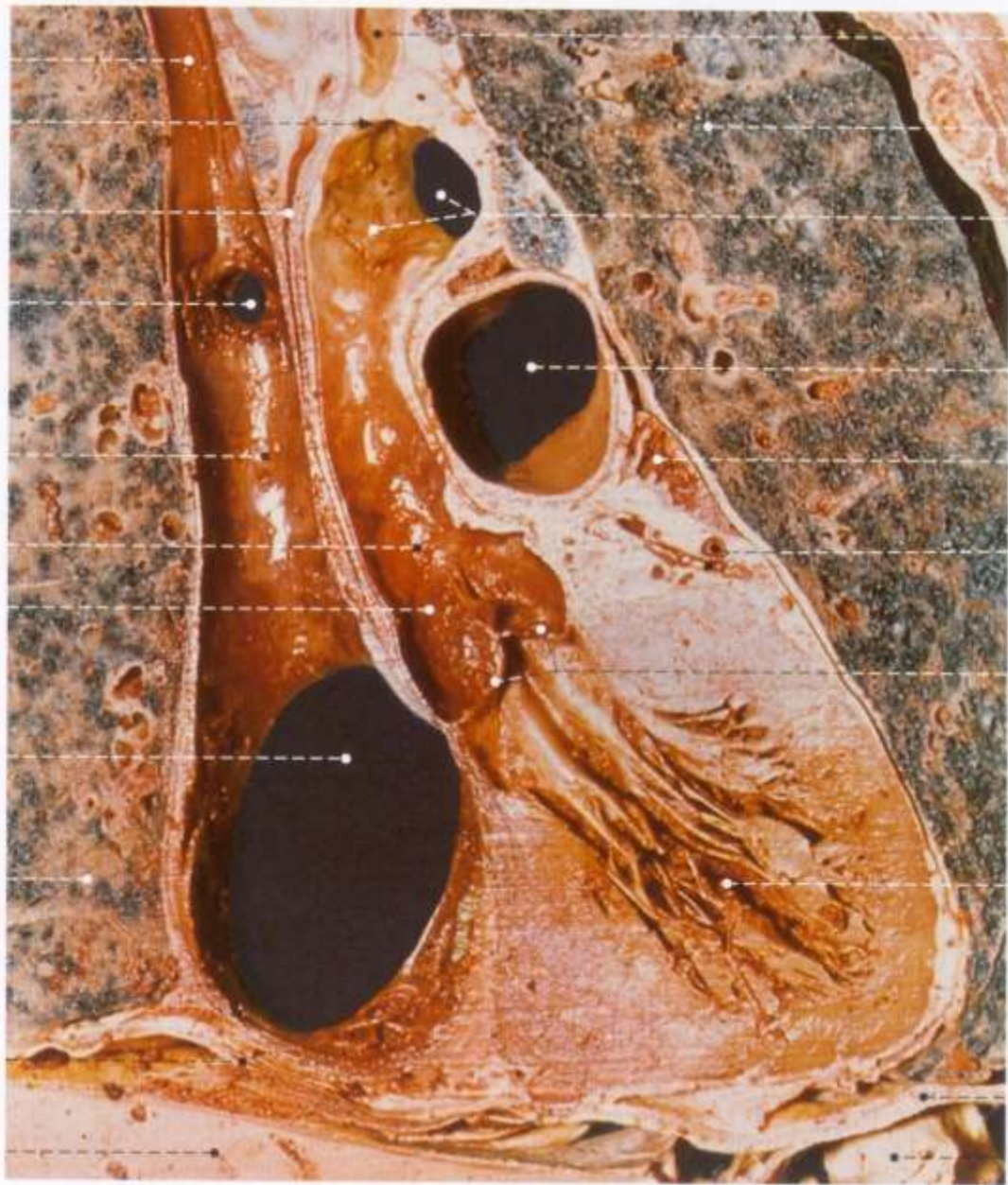
Pericardial cavity
(extended)

Diaphragm



b

Right brachiocephalic vein
Left subclavian artery
Transverse pericardial sinus
Azygos vein
(opening into superior vena cava)
Superior vena cava
Ascending aorta
Aortic bulb
Right atrium
Right lung
Diaphragm
Liver



Left common carotid artery
Left lung
Arch of aorta
Pulmonary trunk
Left auricle
Circumflex branch
of left coronary artery,
Great cardiac vein
Semilunar cusps
of aortic valve
Left ventricle
Diaphragm
Fundus of stomach

b

Right lung

Right pulmonary artery

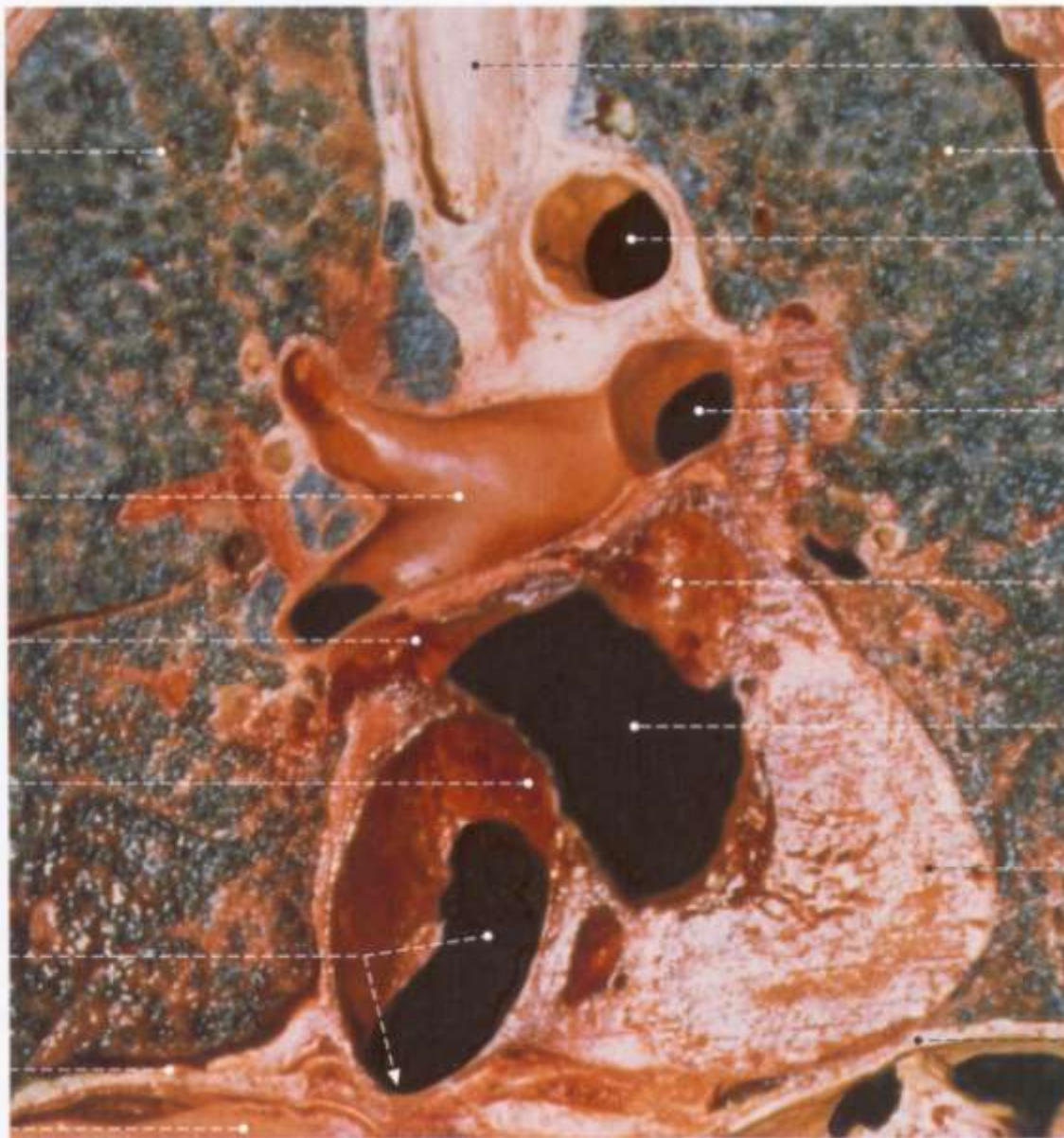Right superior pulmonary vein

Interatrial septum

Right atrium,
Inferior vena cava

Diaphragm

Liver



Trachea

Left lung

Arch of aorta

Left pulmonary artery

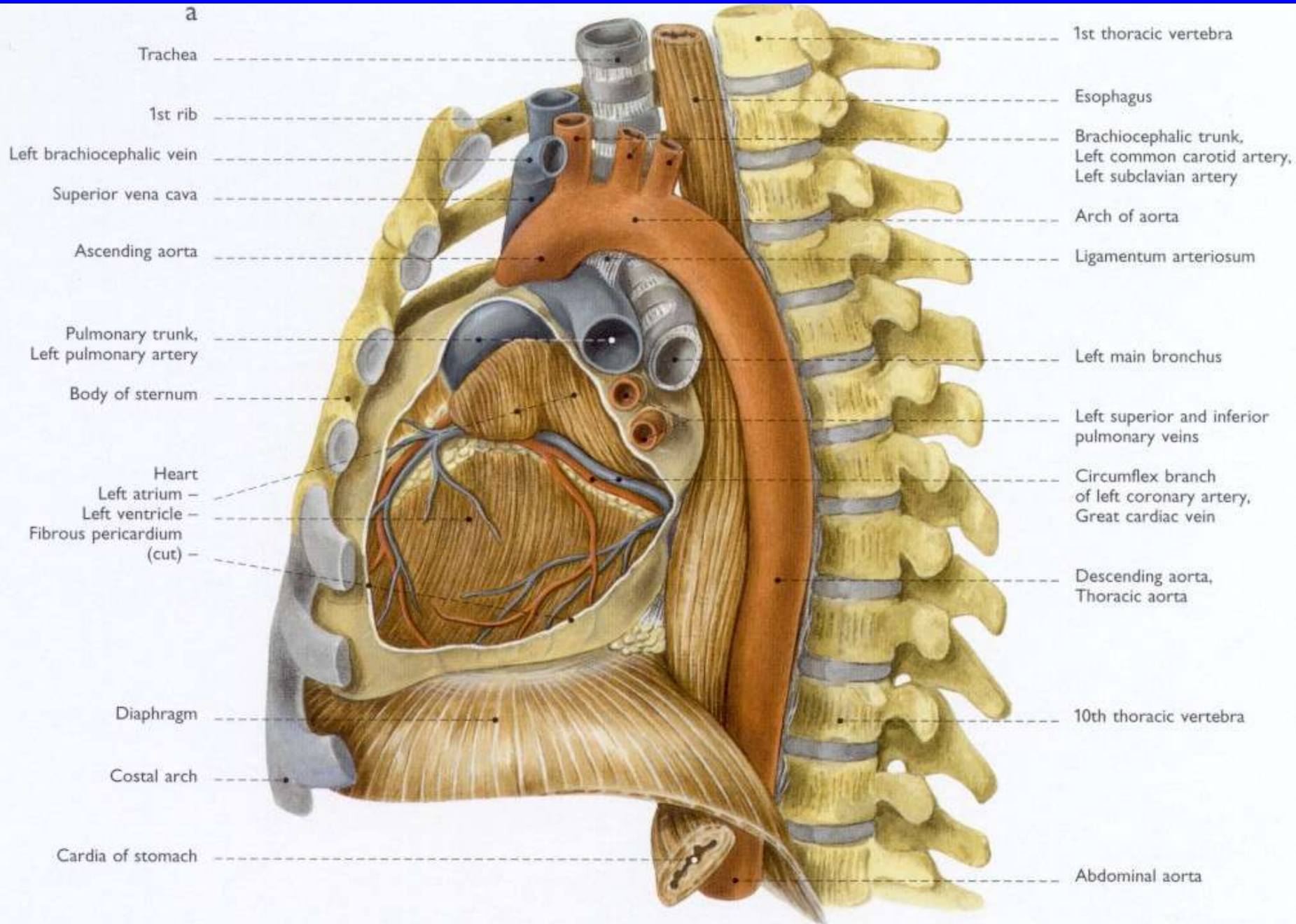
Left superior pulmonary vein

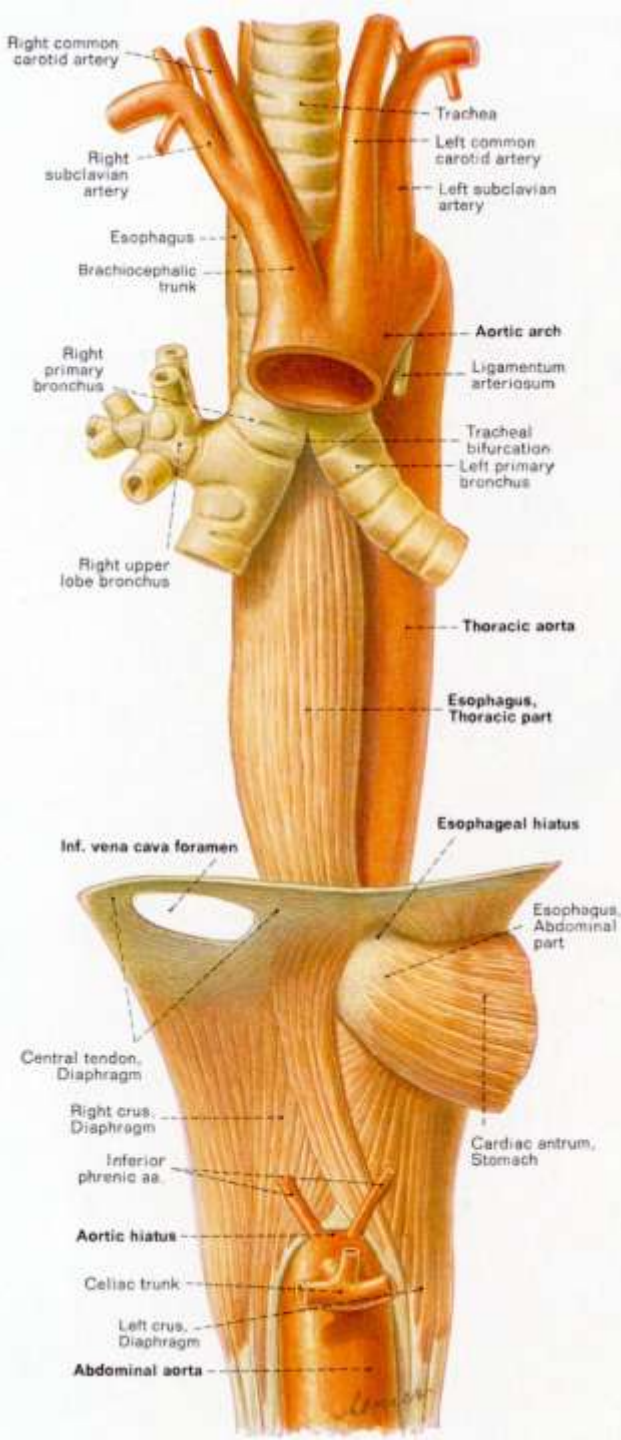
Left atrium

Myocardium of left ventricle

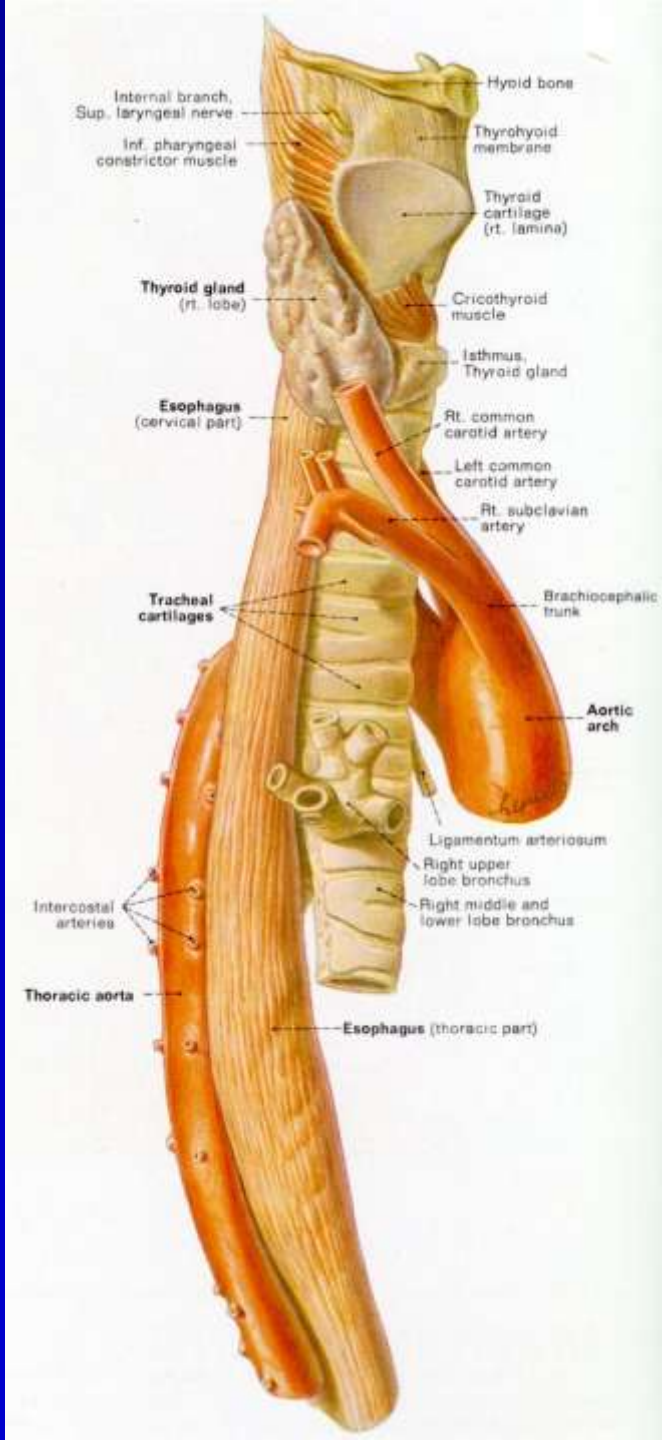
Diaphragm

Relationship of Esophagus to Heart and Aorta

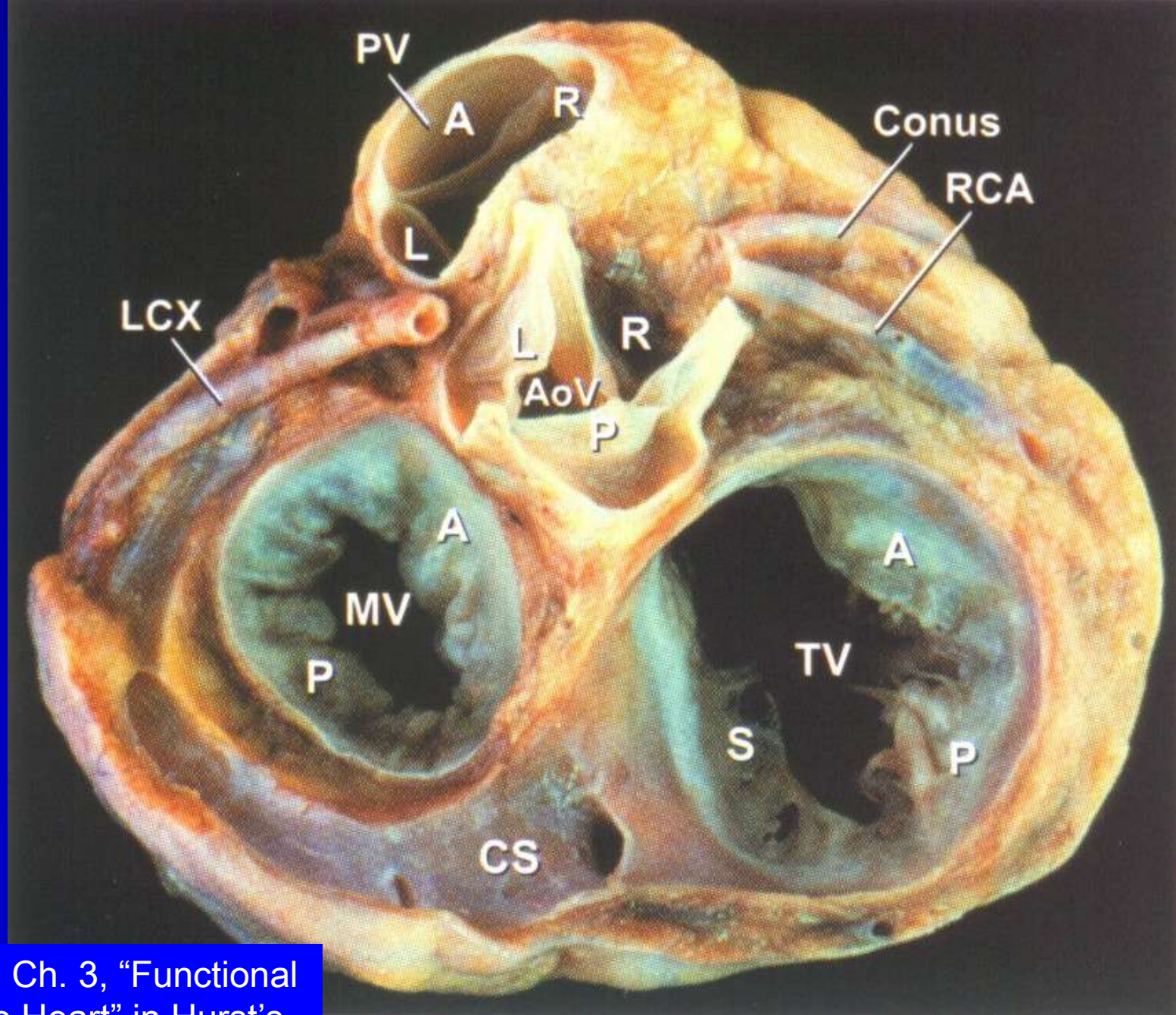




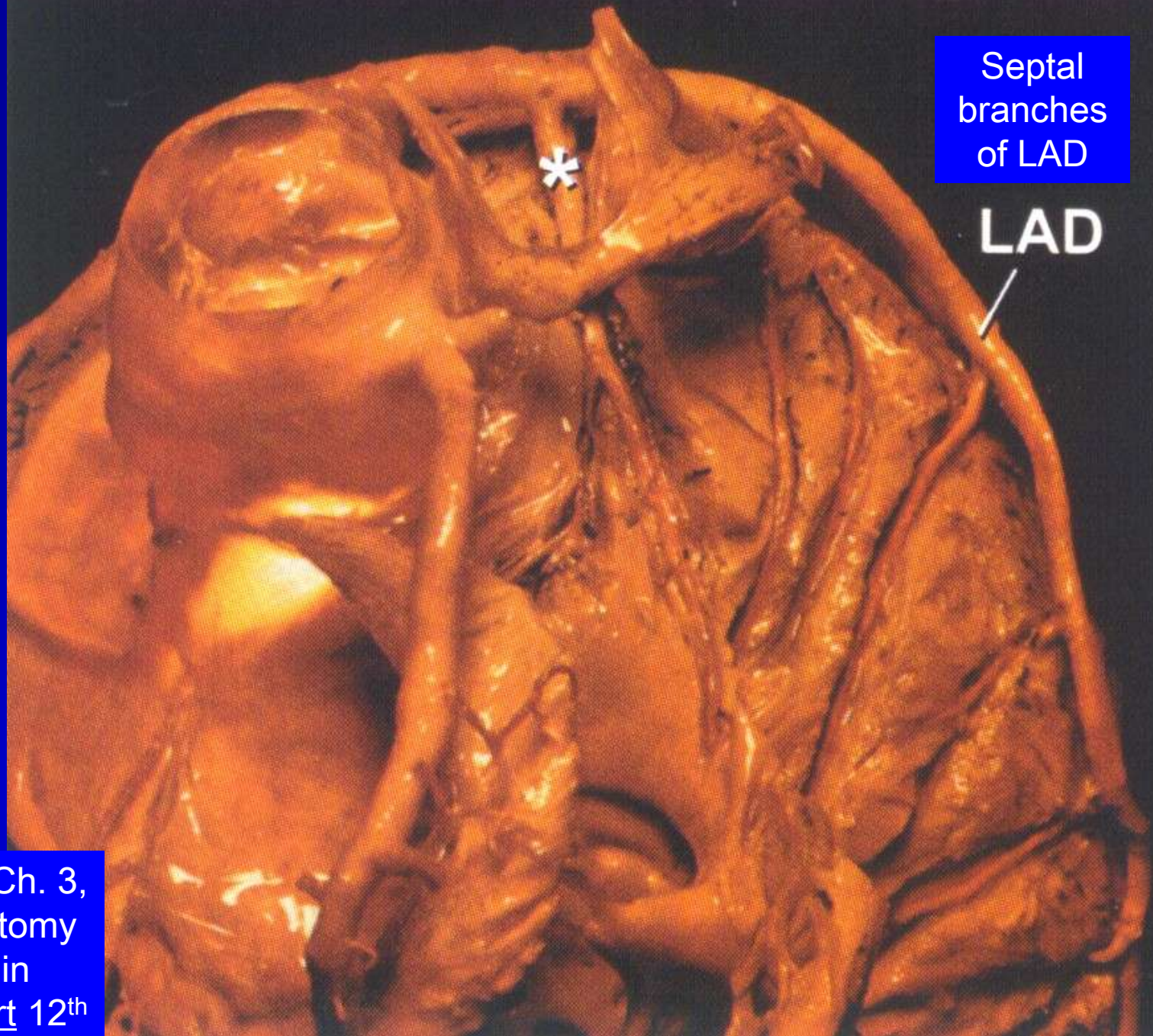
Relationship of Esophagus to Aorta



Clemente CD.
Anatomy
3rd Ed, 1987, fig
216, 7.



Malouf JF et al. Ch. 3, "Functional
Anatomy of the Heart" in Hurst's
The Heart 12th ed. 2008

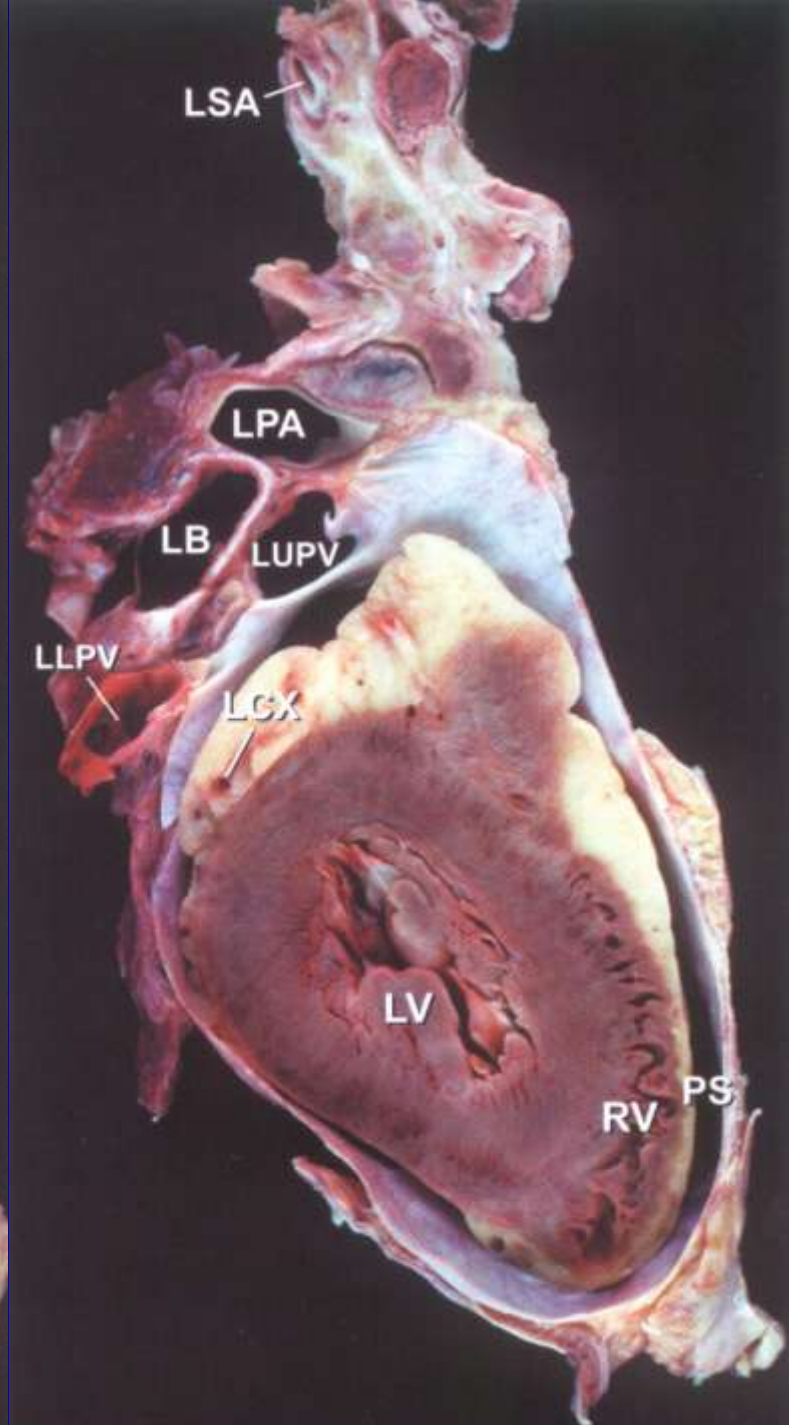
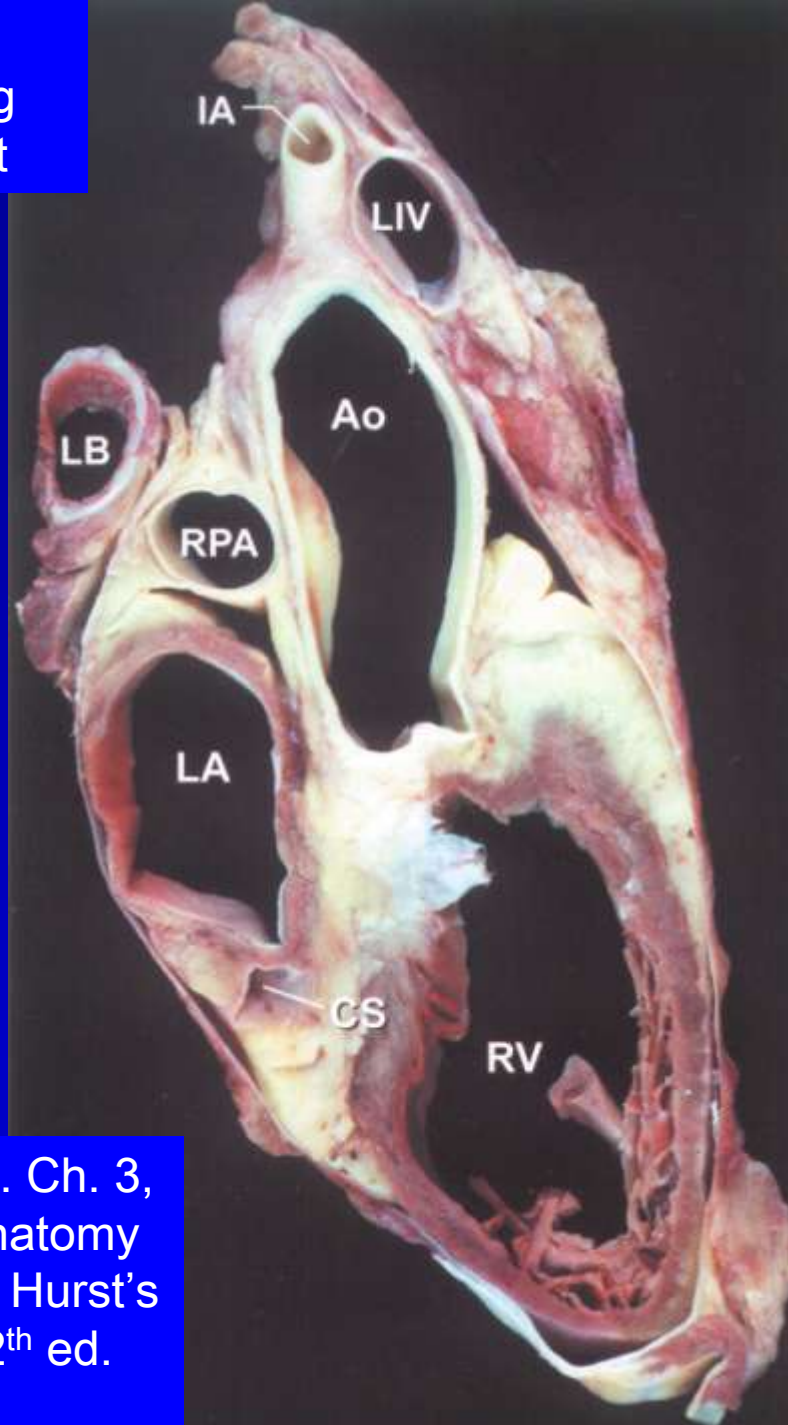


Septal
branches
of LAD

LAD

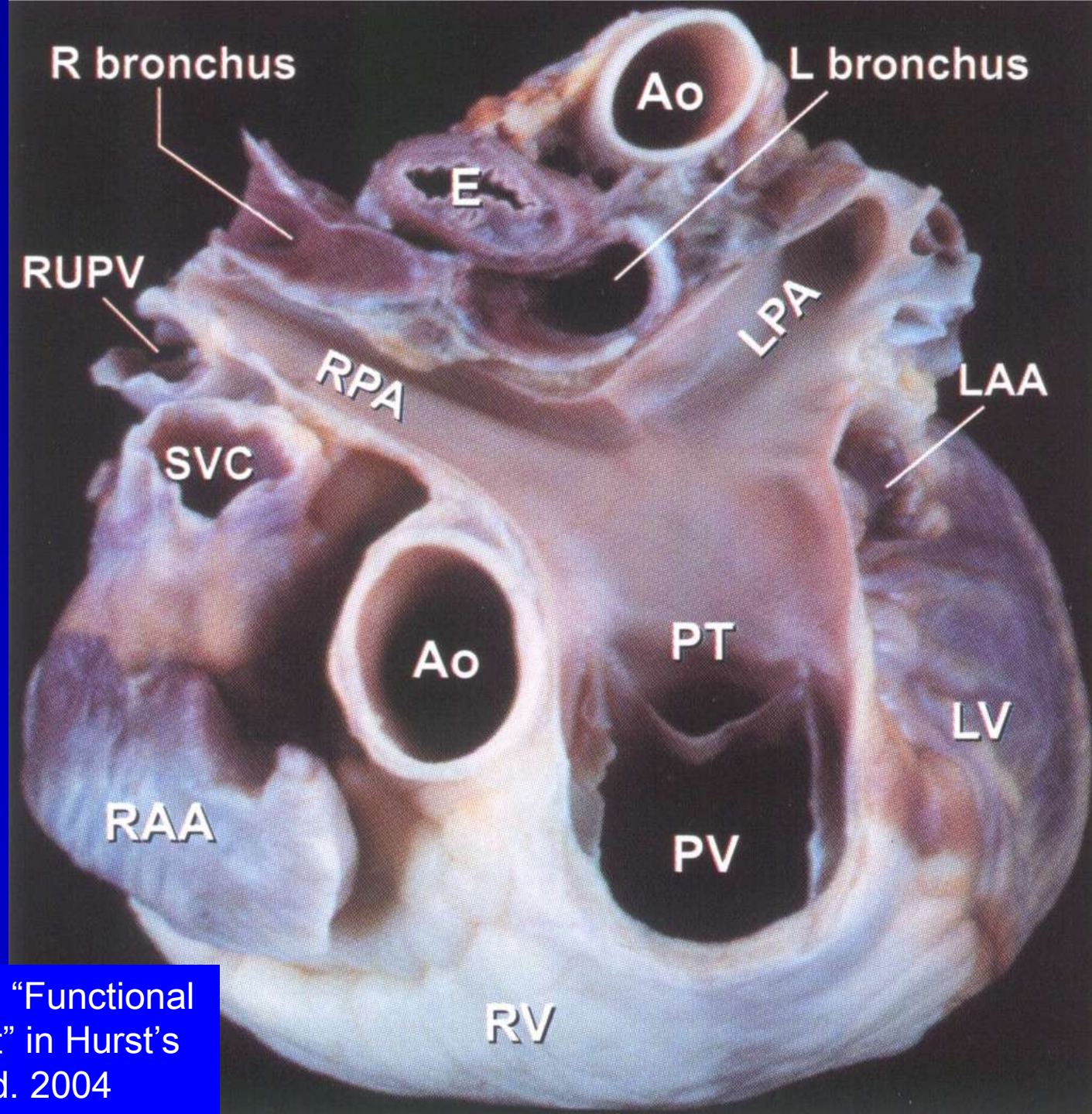
Malouf JF et al. Ch. 3,
"Functional Anatomy
of the Heart" in
Hurst's The Heart 12th
ed. 2008

Parasagittal
sections looking
from right to left



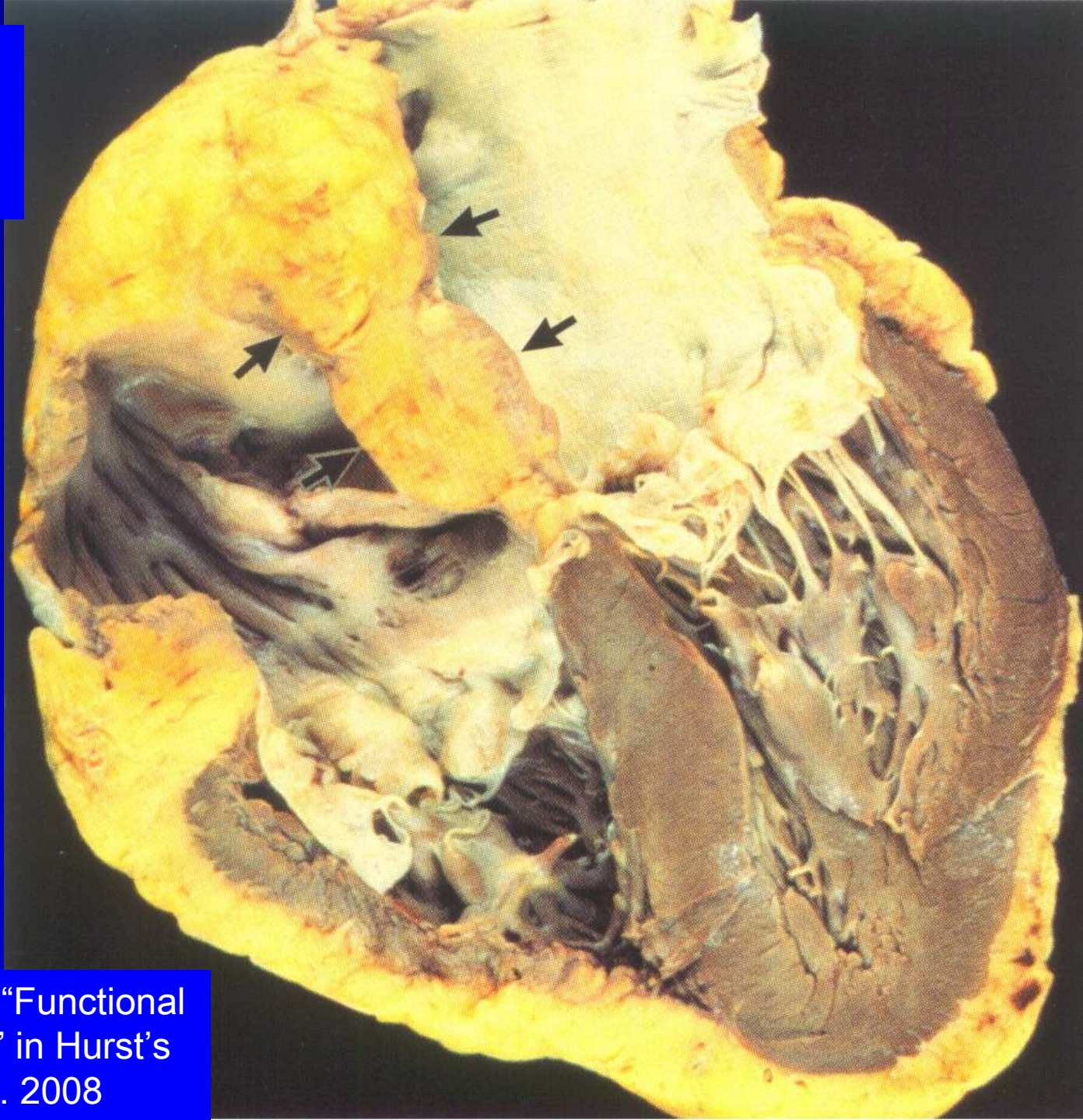
Malouf JF et al. Ch. 3,
“Functional Anatomy
of the Heart” in Hurst’s
The Heart 12th ed.
2008

Transverse section
looking from head to
feet at level of great
vessels



Malouf JF et al. Ch. 3, "Functional
Anatomy of the Heart" in Hurst's
The Heart 11th ed. 2004

4-chamber slice
showing lipomatous
hypertrophy of the
interatrial septum

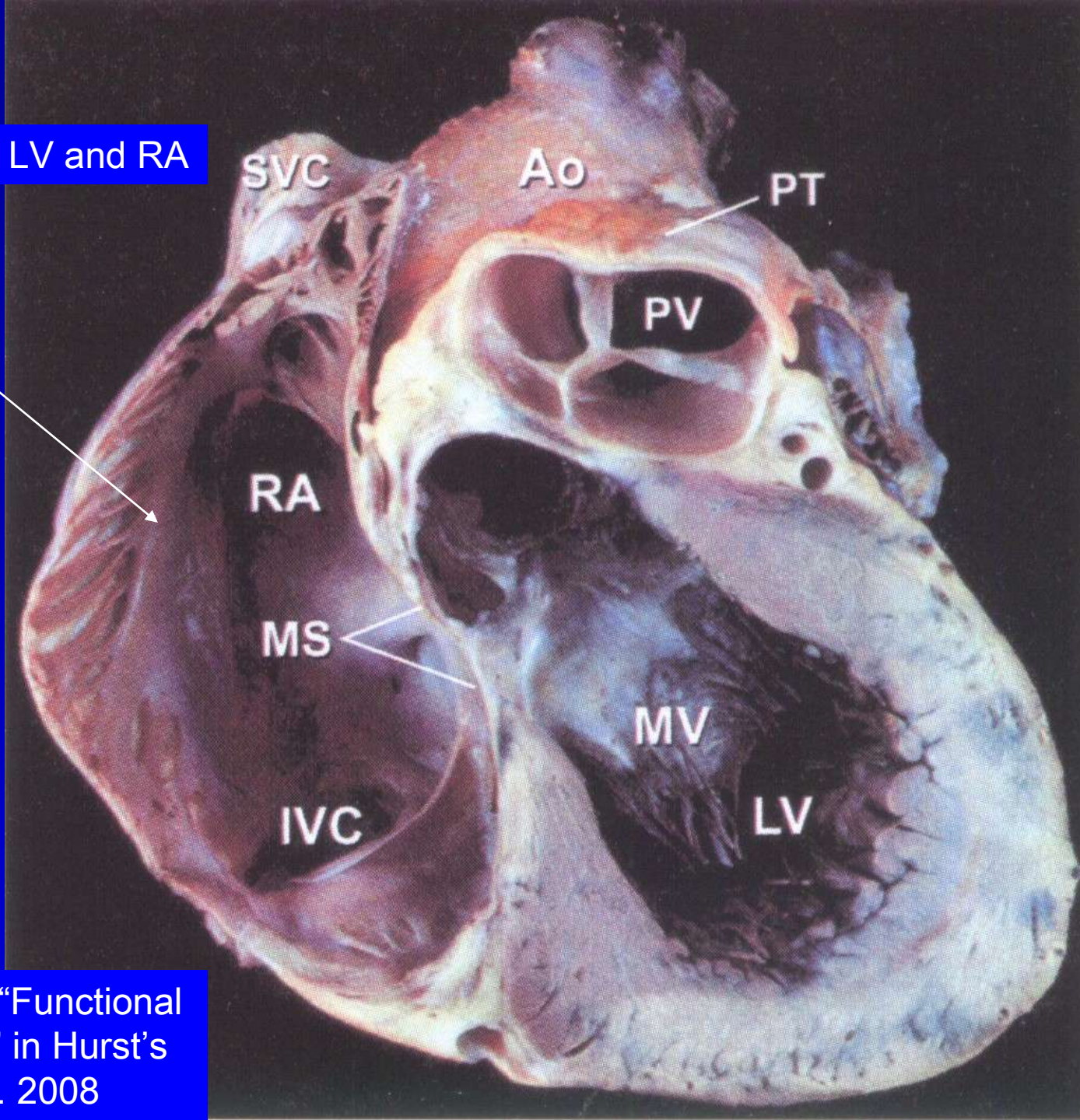


Malouf JF et al. Ch. 3, "Functional
Anatomy of the Heart" in Hurst's
The Heart 12th ed. 2008

Frontal section through LV and RA

Crista terminalis of
Wilhelm His, Jr.
(December 29,
1863 – November
10, 1934, Swiss
anatomist)

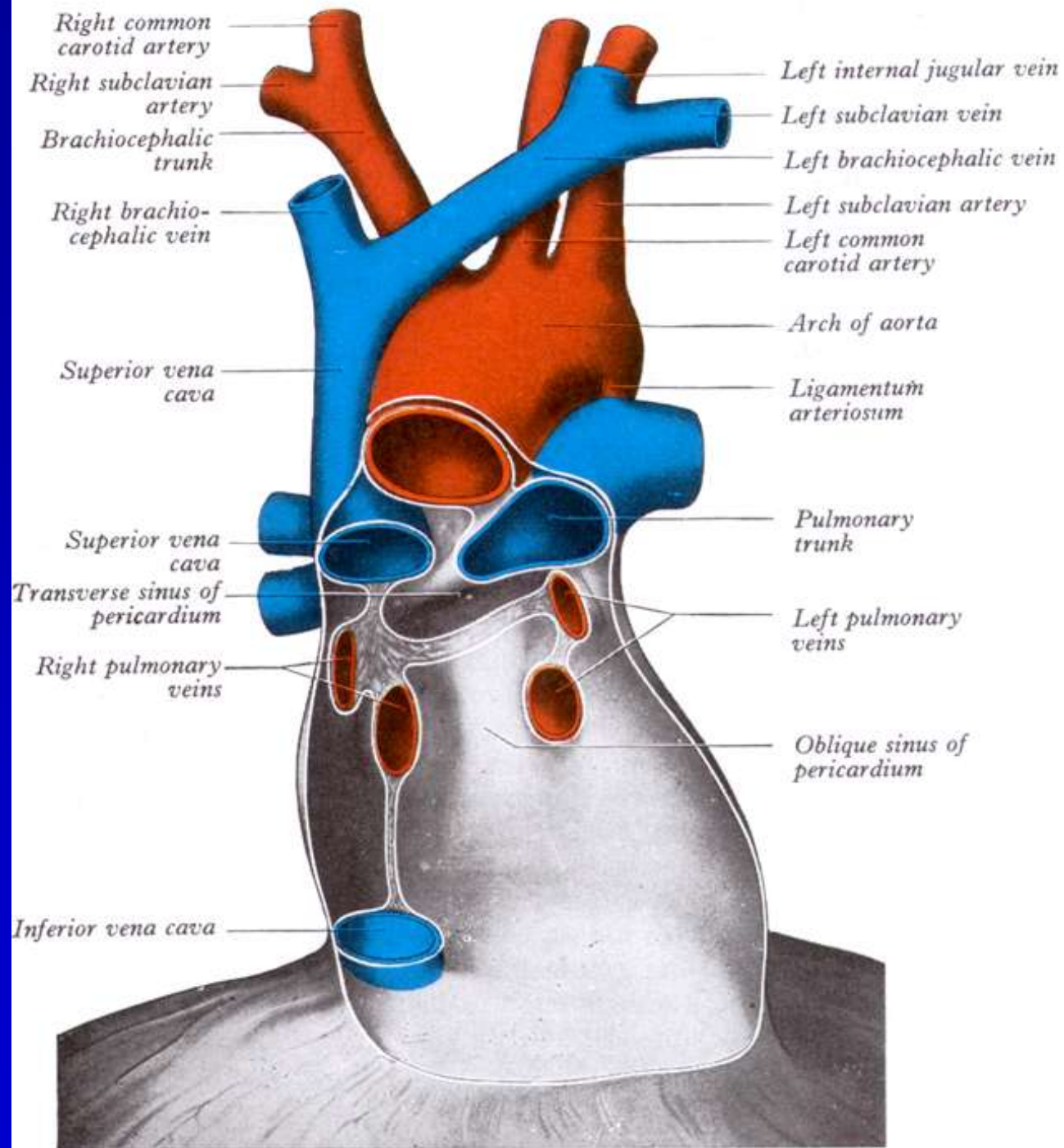
MS = membranous
septum

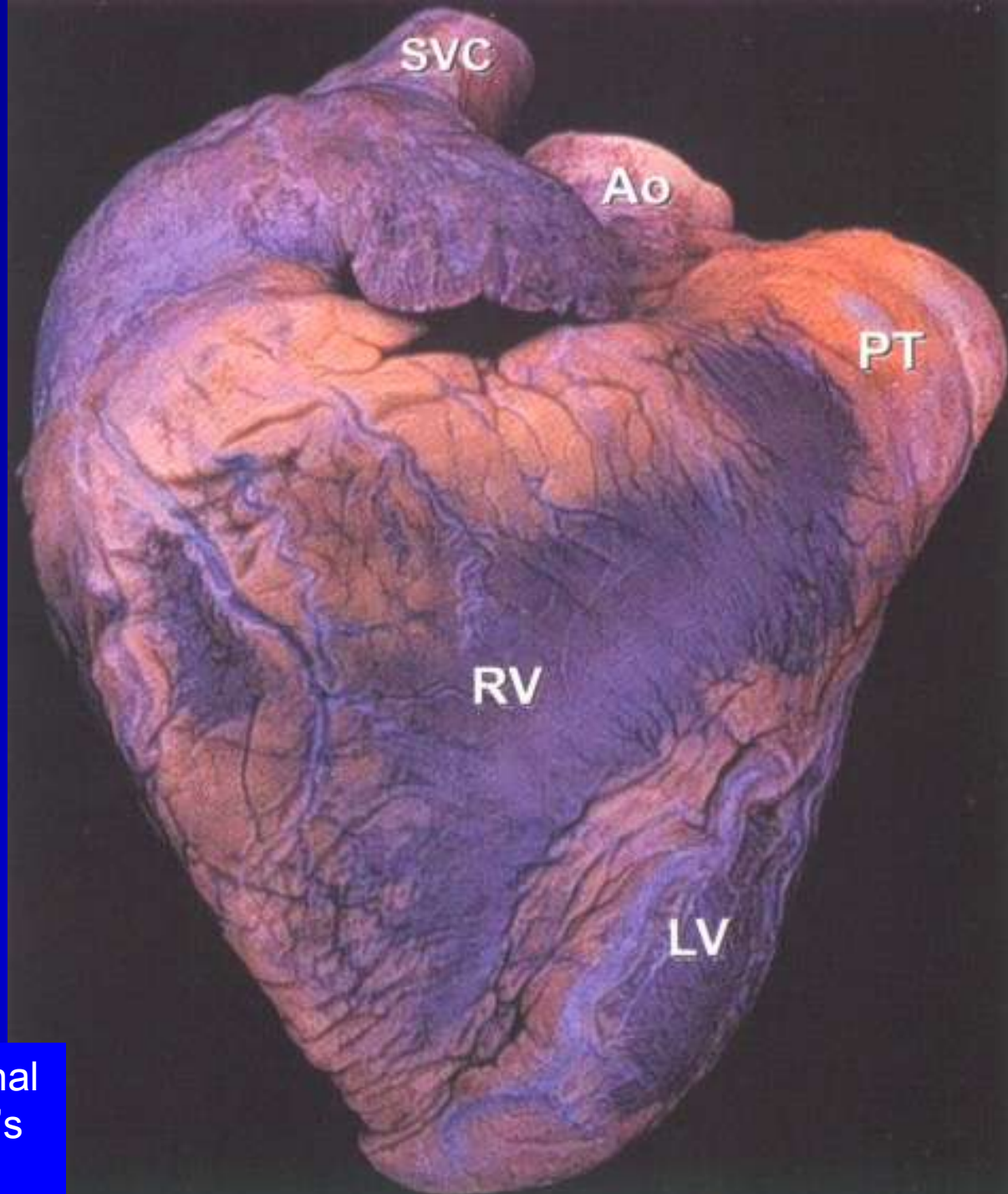


Malouf JF et al. Ch. 3, "Functional
Anatomy of the Heart" in Hurst's
The Heart 12th ed. 2008

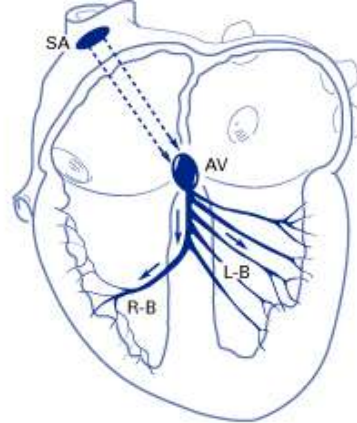
“Venous Cross”
Horizontal –
pulmonary veins
Vertical – systemic
veins

Westberg’s
space: the space
between the
parietal
pericardium and
the beginning of
the aorta
(Dorland’s Medical
Dictionary);
Friedrich Westberg,
19th century German
physician

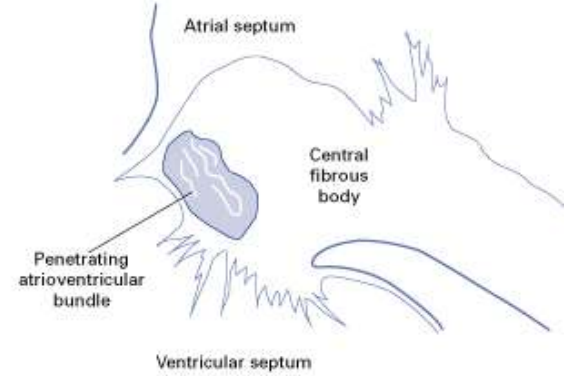




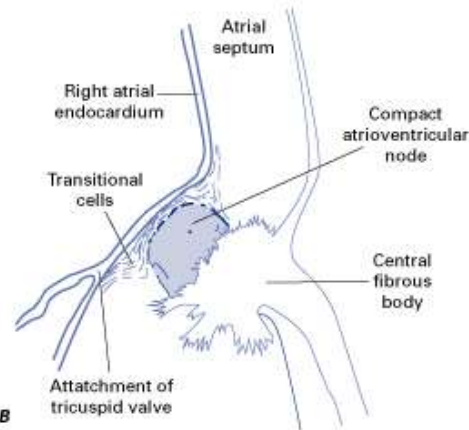
Malouf JF et al. Ch. 3, "Functional
Anatomy of the Heart" in Hurst's
The Heart 12th ed. 2008



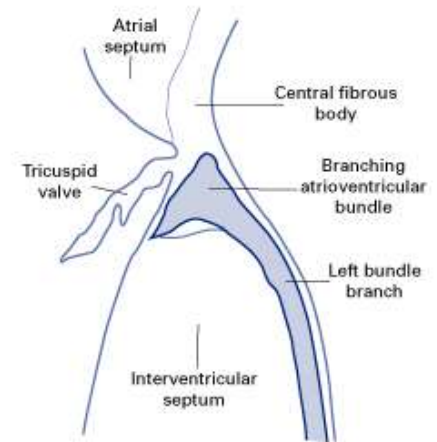
A



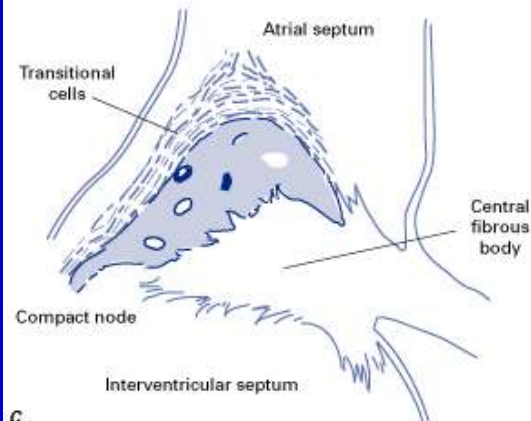
D



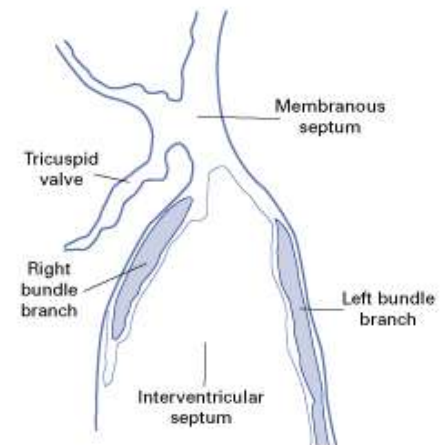
B



E



C



F