

Basic Interpretation of Electrocardiography

Joe M. Moody, Jr., MD

Introduction

1. ECG is only a test like any other test. It is always subservient to the clinical context created by the history and physical.
2. Text is Dubin (6th ed, \$35.50) only because students like it best, but Marriott's text (eleventh ed) by Wagner may be a little better, and is more complete. Probably the best book is Chou's, 6th edition by Surawicz, but it is expensive, and probably not worth the difference in cost to many non-Cardiologists. There are several other choices as well, generally all are fairly reliable.
3. This handout has more information than the test will cover. The testable material is underlined.
4. I need feedback to make the course better. I'm learning too. Send suggestions to me by email: moodyjm@uthscsa.edu

To do well in this course:

1. Start working on the practice ECG strips early; you are expected to have analyzed the first set before the first small group session. After the first two hours of lecture, you should be able to determine rate and intervals. After the second two hours of lecture, you should be able to determine the diagnosis of the axis.
2. The test is open book, open notes, but there is not enough time to look up every little detail, so you must have a strong working knowledge of the material. There will be about 30 to 35 questions, single best answer out of five choices.

Objectives: Given an ECG or rhythm strip, correctly identify the following features:

1. Normal ECG, atrial rate, ventricular rate, PR interval, QRS duration, QT interval
2. Identify whether the QRS axis is normal, left axis deviation or right axis deviation
3. Sinus rhythm, sinus bradycardia, sinus tachycardia, sinus arrhythmia
4. Ventricular subendocardial ischemia pattern
5. Ventricular transmural (subepicardial) ischemia pattern (inferior, anterior, lateral, or combination); and pericarditis
6. Acute or recent myocardial infarction pattern (inferior, anterior, lateral, posterior, or combination), old myocardial infarction pattern (inferior, anterior, lateral, posterior, or combination)
7. LV hypertrophy, RV hypertrophy, LA enlargement, RA enlargement
8. LBBB, RBBB, ventricular pre-excitation of the WPW type
9. Prolonged QT interval, hypokalemia pattern, hyperkalemia pattern
10. Premature atrial complexes (normally conducted, aberrantly conducted, and nonconducted), supraventricular tachycardia, atrial flutter (2:1 conduction, variable conduction), atrial fibrillation (slow, moderate or rapid ventricular response), multifocal atrial tachycardia, junctional rhythm

11. Premature ventricular complexes (uniform, multiform, couplets), ventricular tachycardia, ventricular fibrillation
12. First degree AV block, second degree AV block (Mobitz Type I or Wenckebach, and Mobitz Type II), third degree AV block (Complete AV block, or complete heart block)
13. Ventricular pacemaker

Section I: Basic Principles in ECG interpretation

Part A: Electrophysiology and Foundational Considerations

Action Potential, (this is an oversimplified generalization typical of a Purkinje cell, specific cardiac cell types vary in electrical properties; good ref is Braunwald's textbook of heart disease, 8th ed., 2008, pp 737-744)

Phase 0: rapid depolarization to about +30mV

Conductance is dominated by Sodium (opening of Na channels)

Inward Sodium current – channels open only for 1-2 msec

Faster rate of rise of Phase 0 means faster conduction velocity

Phase 1: brief rapid repolarization to about 0 mV

Due to inactivation of Sodium current and transient outward

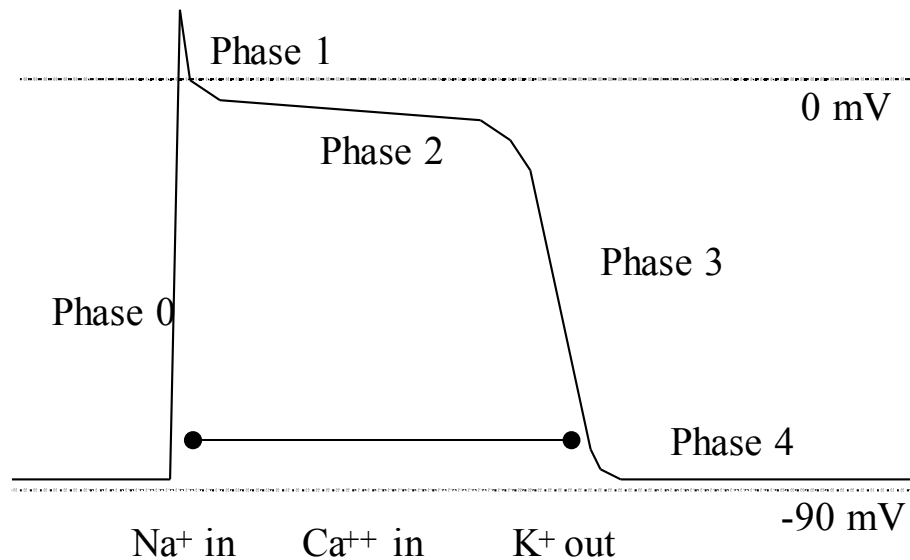
Potassium current

Phase 2: plateau of depolarization due to inward Calcium current

Phase 3: final repolarization due to outward Potassium current (required for any subsequent depolarization to occur)

Phase 4: Polarized state - resting potential, -90 mV (inside negative) due to conductance dominated by Potassium (leaking out) - this is the state of readiness of the membrane

Depolarization results in Contraction! No contraction without depolarization!



Important electrical characteristics:

Automaticity - the characteristic of a tissue with spontaneous generation of an action potential (due to phase 4 depolarization)

Conductivity - the characteristic of a tissue with transmission of an action potential through a tissue (related mainly to the steepness of phase 0 depolarization)

Conduction of the Cardiac Impulse - Cardiac Conduction System

Sinus Node (SA node, sinoatrial node):

Normal location of pacemaker of heart

High in the right atrium near the junction of the superior vena cava

On the ECG sinus node depolarization is not seen

Atrium - cell-to-cell conduction from the SA node, velocity of 1 m/sec

By atrial contractile muscle and/or specialized atrial conduction pathways

Results in depolarization and therefore contraction of the atria

On the ECG, atrial depolarization is the **P wave**

Presents the action potential to the AV node

AV node - slowest conducting tissue in the heart, as slow as 0.05 m/sec

Long refractory period protects ventricle from too many impulses

22mm long, 10mm wide, 3mm thick, near ostium of coronary sinus

Normally the only electrical connection between the atria and ventricles

Delay allows for time for blood to flow out of atrium into ventricles

Retrograde and reentrant conduction patterns can occur here

On the ECG: straight line between P wave and QRS ("**PR segment**")

Bundle of His (common bundle) - Purkinje fibers, conduct at 1-4 m/sec

Beginning of the His-Purkinje system, length about 10mm

On the ECG, depolarization of the bundle of His is not seen

Bundle branches - the rest of the His-Purkinje system, fibers are subendocardial

Right bundle branch

Left bundle branch (Anterior and posterior hemifascicles)

On the ECG, depolarization of the bundle branches is not seen

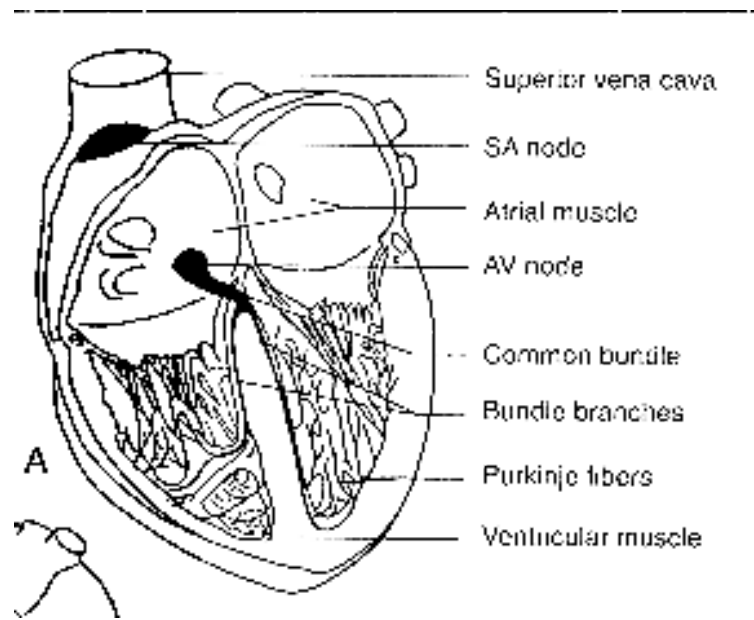
Ventricular myocardium - conducts at 0.3-0.4 m/sec, endocardium to epicardium

Ventricular depolarization causes ventricular contraction (arterial pulse)

On the ECG, ventricular depolarization is seen as the **QRS complex**

Repolarization: All these tissues must repolarize after each depolarization. The most important repolarization for ECG interpretation is repolarization of the ventricles.

On the ECG, repolarization of the ventricles is seen in the **ST segment and the T wave**



As the electrical impulse travels through the heart depolarizing first the atria then the ventricles, it creates an electrical dipole (voltage), which changes in magnitude and direction (in 3-D space) during depolarization and repolarization. This is recordable on the surface of the body. In this recording, the depolarization of the atria is called the P wave, the depolarization of the ventricles is called the QRS complex, and the repolarization of the ventricles is called the T wave. The ECG we study looks at the 3-D activity in 12 different standard 1-D projections, or from 12 different vantage points.

During depolarization and repolarization, the heart creates a detectable electric potential on the body surface, and the ECG machine simply records that voltage.

ECG machine – definition: a device that creates graph of voltage versus time. Time always moves from left to right (horizontal), and voltage is displayed up and down (vertical). Voltage is the electrical potential difference between 2 points (measured in millivolts (mV) on the ECG. All modern ECG machines automatically include on the tracing a standard mark. A standard mark is a square wave pulse of 1.0mV amplitude and 0.2 sec duration. A standard mark is usually 10 mm high and 5 mm wide, indicating:

Normal sensitivity of 10 mm/mV

Normal paper speed of 25 mm/sec

Machines may adjust automatically to half sensitivity, can be manually adjusted

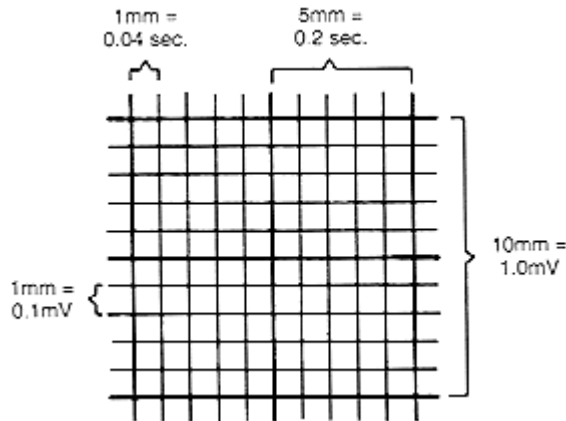
Other choices include quarter sensitivity (quarter standard) or double sensitivity (double standard), or double speed (50 mm/sec) or other speeds

ECG machine prints on graph paper with marks 1 mm apart

Heavier marks every 5 mm both horizontally and vertically

Standard horizontally (time): 1 mm=0.04 sec, 5 mm=0.20 sec, 25 mm=1 sec

Standard vertically (voltage): 1 mm=0.1 mV, 10 mm=1.0 mV



Waves of the ECG

P wave - wave indicating atrial depolarization, not very spiky

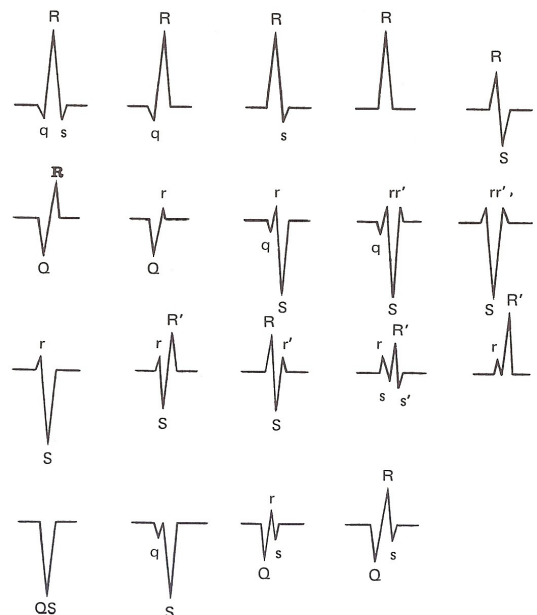
QRS complex - the group of waves indicating ventricular depolarization, usually very spiky

Q wave - an initial downward (below the baseline level) deflection of the QRS complex (may be absent)

R wave - the first upward (above the baseline level) deflection of the QRS complex (may be absent)

S wave - the first downward deflection of the QRS complex after an R wave

QS complex - a QRS complex which has an initial downward deflection (usually called a Q wave) and then NO deflection which goes above the baseline, (that is, no R wave), so that the QRS complex is all below the baseline.



qR complex - a QRS complex with a small Q wave followed by a large R wave

rS complex - a QRS complex with a small R wave followed by a deep S wave

R prime wave - the first upward deflection of the QRS complex after an S wave

J point - the point marking the end of the QRS complex

T wave - the wave after the QRS complex indicating ventricular repolarization, even less spiky than the P wave

U wave - the wave after the T wave indicating further repolarization (may be absent, due to slow repolarization of a special type of cell called the M cell)

Intervals of the ECG (measured as the longest duration in any limb lead; normal range in parenthesis)

P wave duration - from the beginning of the P wave to its end (0.06-0.10sec, or 1.5-2.5mm)

PR interval – from the onset of the P wave to the onset of the QRS complex (0.12-0.20sec, or 3-5mm), includes the P wave duration plus the PR segment

PR segment - from the end of the P wave to the beginning of the QRS complex

QRS duration - from the beginning of the QRS complex to its end (0.06-0.10 sec or 1.5-2.5mm)

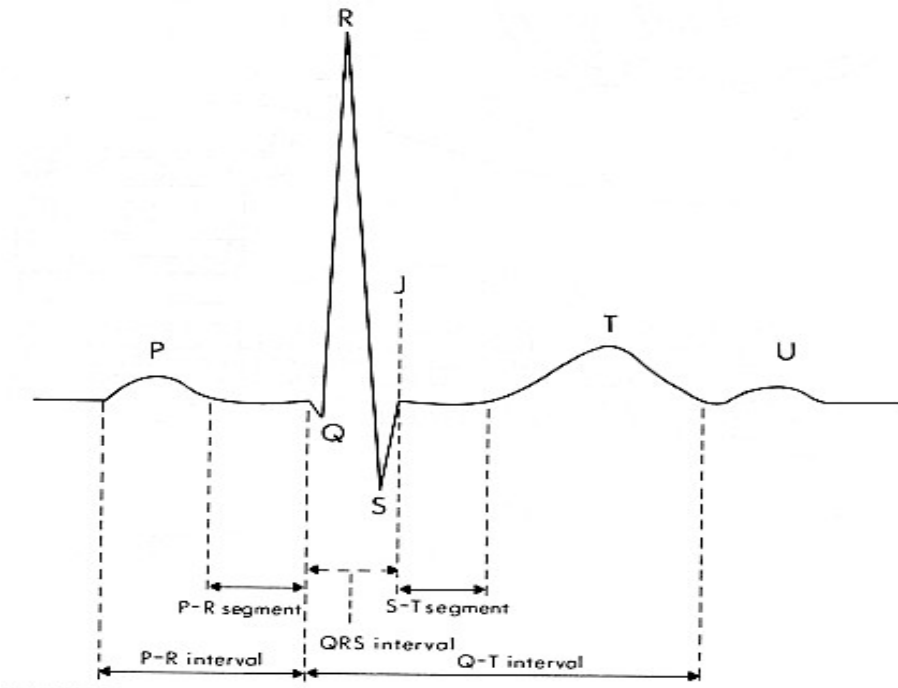
ST segment - from the end of the QRS to the beginning of the T wave

QT interval - from the beginning of the QRS to the end of the T wave (Varies with rate. If regular rhythm, should be 0.41sec corrected for rate)

T-P segment - from the end of the T wave to the beginning of the next P wave

P-P interval - from the beginning of one P wave to the beginning of the next P wave

R-R interval - from the beginning of one QRS to the beginning of the next QRS



Additional intervals sometimes helpful in arrhythmia analysis:

R-R-prime interval - from the beginning of a normal QRS to the beginning of an abnormal QRS, also called coupling interval

R-P interval - from the beginning of the QRS to the beginning of the next P wave

R-prime-R-prime interval - from one abnormal QRS (usually a PVC) to the next abnormal QRS, also called interectopic interval

Calculating the Rate - 3 methods, require normal paper speed of 25 mm/sec. If nonstandard speed, adjust calculations

Method 1: 6 second rule

Requires 6 seconds of recording

Does not require regular rhythm – NOTE: this is the ONLY method useful in irregular rhythm

--Count total number of complexes in 6 seconds and multiply by 10, result in rate/min (counting all the P waves gives the atrial rate; counting all the QRS complexes gives the ventricular rate; normally the atrial and ventricular rates are the same)

--Helpful hint: there are little vertical lines every 3 seconds on some ECG paper.

--Helpful hint: on the new ECG tracings, there are exactly 10 seconds of rhythm, so count all the QRS complexes and multiply by 6, a variation of the 6 second rule (call it the "10 second rule"?)

Method 2: Calculation by interval measurement

Does not require 6 seconds of recording

Requires regular rhythm

--Measure distance in mm between 2 adjacent complexes

--Divide 1,500 by the distance in mm, and result is rate in beats/min

Method 3: Estimating by nearest of the darker 5 mm markers

Fastest method, but not most accurate

Does not require 6 seconds of recording

Requires regular rhythm

--Find a wave beginning on or near a dark 5-mm marker

--Count subsequent 5-mm markers until the next wave of interest

--As counting markers, say, "300, 150, 100, 75, 60, 50 (, 42, 38, 33, 30)"

--When you get to the marker, you have the rate bracketed between 2 numbers

--Interpolate between the 2 bracketed numbers

The 12 leads, 12 standard pairs, 2 points each of electrical potential difference

Each of the 12 leads records from a different 2-D projection

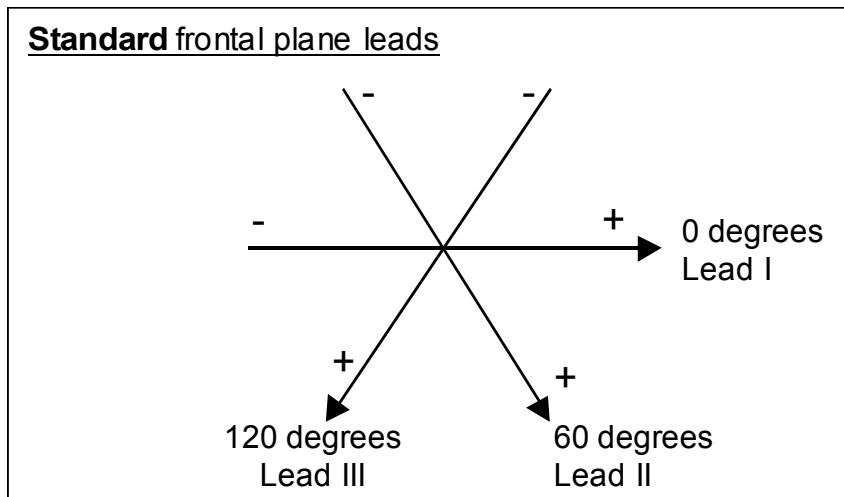
The first 6 leads are frontal plane (Limb leads - 3 standard and 3 augmented),

The other 6 are transverse plane (Chest leads)

Three standard limb leads (4 electrodes, right leg is electrical ground)

I - Right arm negative, left arm positive

II - Right arm negative, left leg positive



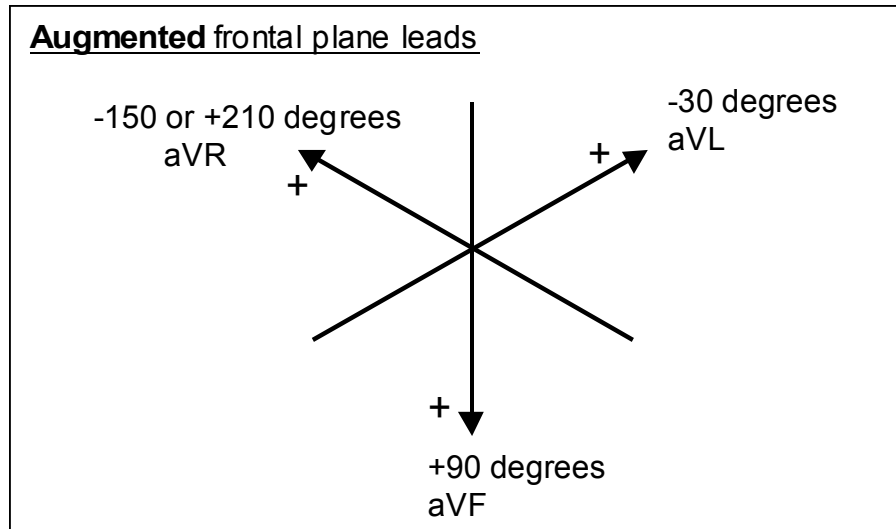
III - Left arm negative, left leg positive

Three augmented limb leads (between one lead and a "central terminal" from the other 2)

aV_R - Right arm positive, other 2 negative

aV_L - Left arm positive, other 2 negative

aV_F - Left leg positive, other 2 negative



Six chest leads (precordial leads, transverse plane leads)

(between one lead and a central terminal from all 3 limb electrodes)

V₁ - electrode in 4th Right intercostal space (ics) at sternal edge

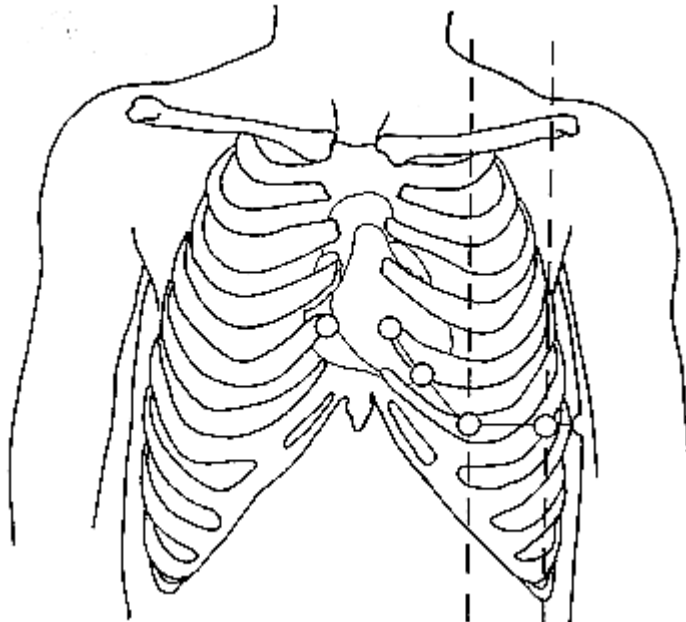
V₂ - electrode in 4th Left ics at sternal edge

V₃ - electrode halfway between V₂ and V₄

V₄ - electrode in 5th Left ics in the midclavicular line

V₅ - electrode in anterior axillary line, same plane as V₄

V₆ - electrode in mid-axillary line, same plane as V₄

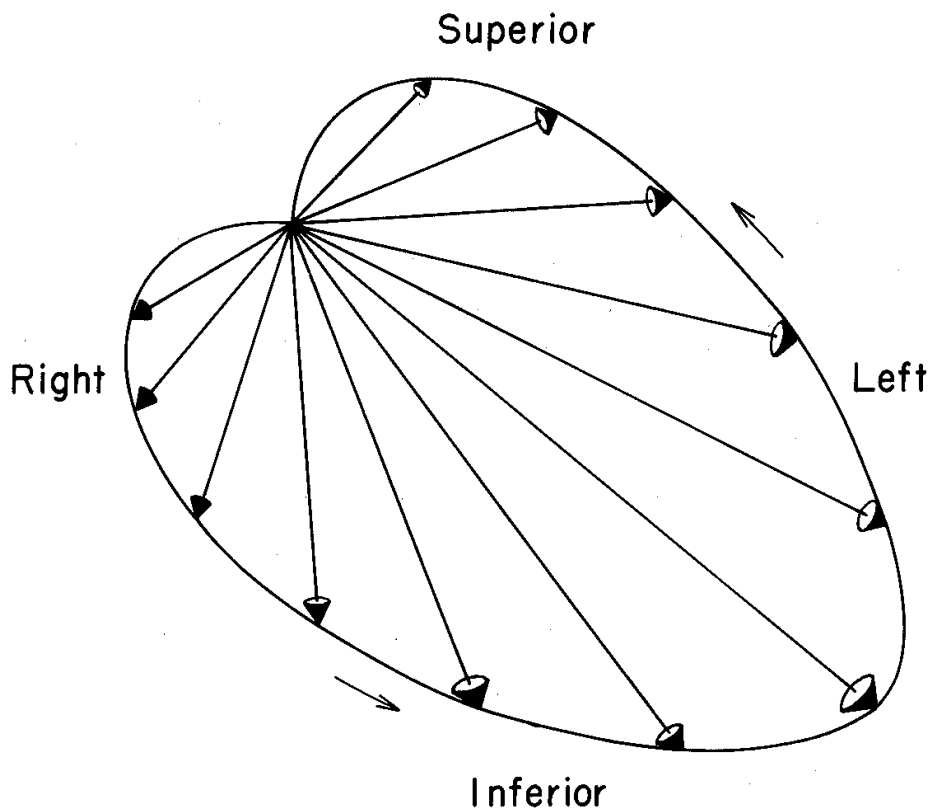


Determining the Axis

What is an Axis? When the heart depolarizes and repolarizes, the depolarization generally has a predominant direction in space. That predominant direction is the axis of the depolarization or repolarization. We generally focus our attention on the depolarization of the ventricle as represented in the QRS complex. The predominant direction of the ventricular depolarization is called the QRS axis. (The predominant direction of atrial depolarization is the P wave axis, and the predominant direction of ventricular repolarization is the T wave axis)

Background 1, once again, recall that the electrical activity is occurring as an electrical dipole (a voltage) which varies in amplitude and direction in 3-D space over time.

However, an



ECG lead is looking at only one-dimensional voltage. But the ECG has 12 leads which look at the one-dimensional voltage from 12 different fixed vantage points, 6 in the frontal plane (limb leads), and 6 in the transverse plane (chest leads). We generally analyze the axis only in the frontal plane. We most commonly analyze the axis of the QRS complex, but any wave or portion of a wave (such as the P wave or the T wave or even the initial forces of the QRS or the terminal forces of the QRS) may be analyzed using the same principles. We will focus on the axis of the QRS complex. By common agreement for many years, the frontal plane is divided into a circle of 360 degrees, and by definition, 0 degrees is directed to the left, and the number of degrees increases as the direction progresses clockwise. Therefore, directly inferior is 90 degrees, directly

rightward is 180 degrees, and directly superior is either 270 degrees or -90 degrees. Similarly, a direction to the left and inferior will be between 0 and 90 degrees, a direction to the right and inferior will be between 90 and 180 degrees, a direction to the right and superior will be between 180 and 270 degrees, and a direction to the left and superior will be between -90 and 0 degrees.

Background 2; realize that each of the 6 limb leads has a consistent vantage point, which is mapped to a constant direction in polar coordinates. You must memorize each lead's vantage point (see diagrams above of standard and augmented limb leads). Lead I is defined as 0 degrees and is directly leftward. Lead II is defined as +60 degrees and is directed clockwise 60 degrees from lead I, or leftward and inferiorly. Lead III is defined as +120 degrees and is directed another 60 degrees clockwise from lead II, and so is directed rightward and inferiorly. Lead aV_R is defined as toward the right shoulder, at +210 degrees or -150 degrees, and so is rightward and is 30 degrees superior to the horizontal. Lead aV_L is defined as toward the left shoulder, at 30 degrees above the horizontal, or minus 30 degrees, that is, 30 degrees counterclockwise from lead I. Lead aV_F is defined as directed inferiorly, 90 degrees clockwise from lead I, or at +90 degrees.

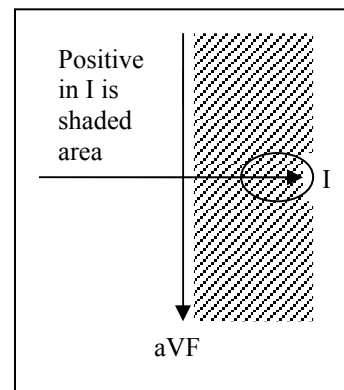
Background 3, Understand that determining an axis in the frontal plane requires determining for each limb lead whether the wave (for example the QRS complex) is positive, negative, or isoelectric.

The QRS complex is positive in a lead if the upward deflection is larger than the downward deflection in that lead.

The QRS complex is negative if the downward deflection is larger than the upward deflection.

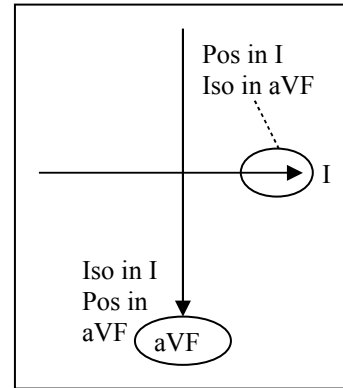
The QRS complex is isoelectric if the upward deflection is the same size as the downward deflection.

If the QRS complex is positive in a lead, then the QRS axis is not too different from the axis of that lead; specifically, the difference between the axis of the wave and the axis of the lead is less than 90 degrees (less than perpendicular). As a matter of fact, the more positive the QRS complex is in a lead, the closer the QRS axis will be to the axis of that lead (the angle between the QRS axis and the axis of the lead may be nearly 0 degrees). Conversely, if the QRS complex is negative in a lead, then the difference between the axis of the wave and the axis of the lead is more than 90 degrees (more than perpendicular). Again, the more negative the QRS complex is in a given lead, the farther away the QRS axis will be from the axis of that lead (the angle between the QRS axis and the axis of the lead may be nearly 0 degrees). Similarly, if a wave is isoelectric in a lead, then the difference between the axis of the QRS complex and the axis of the lead is 90 degrees (perpendicular). Given the three background points, the axis can be determined using the steps below.

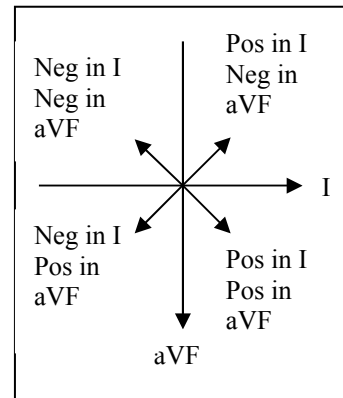


Step 1, look at the two perpendicular leads I and aV_F. Determine for each of these leads, whether the wave is positive (mainly above the baseline, upgoing), negative (mainly below the baseline, downgoing), or isoelectric (that the upgoing forces are balanced by equal downgoing forces) in that lead.

If the wave is positive in lead I (at 0 degrees), then the axis is to the left side of the patient (less than 90 degrees from lead I, which is directly leftward, i.e., between about -75 and +75 degrees). But if the wave is negative in lead I, then the axis is to the right side of the patient. If the wave is isoelectric in lead I, then the axis is perpendicular to lead I, or at either +90 degrees or -90 degrees.



If the wave is positive in lead aV_F (at +90 degrees), then the axis is below the horizontal (less than 90 degrees from lead aV_F, or between about +15 and +165 degrees). But if the wave is negative in aV_F, then the axis is above the horizontal. If the wave is isoelectric in lead aV_F, the axis will be perpendicular to lead aV_F, or at either 0 or +180 degrees.



Most normal axes are below the horizontal and to the left side of the patient, so are positive in both lead I and lead aV_F. The results of this analysis then tell you in which quadrant the axis lies. If the wave is positive in leads I and aV_F, the axis is in the left lower quadrant. If the wave is positive in lead I but negative in aV_F, the axis is in the left superior quadrant. If the wave is negative in lead I, but positive in aV_F, the axis is in the right lower quadrant, and if the wave is negative in both leads I and aV_F, the axis is in the right upper quadrant.

If either lead I or lead aV_F is isoelectric, then you can complete the determination of the axis with this step. If the wave is isoelectric in I and positive in aV_F, then the axis is +90 degrees. If the wave is isoelectric in I and negative in aV_F, then the axis is -90 degrees. If the wave is positive in I and isoelectric in aV_F, then the axis is 0 degrees, and if the wave is negative in I and isoelectric in aV_F, then the axis is +180 degrees. In this case, you have succeeded in determining the axis.

Step 2, If neither leads I or aV_F is isoelectric, then look for a lead in which the wave is isoelectric (equal magnitude of upward and downward deflections). If you find an isoelectric lead, the axis will be perpendicular from that lead, and so will be either 90 degrees greater than or 90 degrees less than the axis defined by that lead. Whether the 90 degrees should be added or subtracted depends on which quadrant contains the axis as found in step three above. Just select the direction that results in the correct quadrant.

Example 1: The wave is positive in leads I and aV_F, and it is isoelectric in lead aV_L. So the axis will be perpendicular to aV_L, which is defined as -30 degrees, so

it will be either -120 degrees or +60 degrees. Since +60 degrees falls in the correct quadrant (left lower quadrant since both leads I and aV_F are positive), the axis is +60 degrees.

Example 2: The wave is positive in leads I and aV_F , and it is isoelectric in lead III. Lead III is defined as +120 degrees, so the perpendicular is either +30 or +210, and since +30 is in the correct quadrant, it is the correct axis. So if there is an isoelectric lead, you are finished! So, if there is an isoelectric lead, the axis will be a multiple of 30.

Step 3, if there is no isoelectric lead, look for the two leads with the smallest net deflections (closest to isoelectric). Similar to step two, the axis will be between the perpendiculars of those two leads, (nearly perpendicular to the nearly isoelectric leads). If the lead is slightly negative, the axis will be slightly more than 90 degrees from the lead, and if the lead is slightly positive, the axis will be slightly less than 90 degrees from the lead.

Example 1: If the QRS is positive in leads I and aV_F and is also slightly positive in leads III and aV_L , the axis is slightly greater than +30 degrees (slightly less than perpendicular to III) and slightly less than +60 degrees (slightly less than perpendicular to aV_L), so call it +45 degrees, and you're finished!

Example 2: If the QRS is positive in leads I and aV_F , and is only slightly positive in lead I and slightly negative in lead aV_L , then the axis is slightly less than +90 degrees (slightly less than perpendicular to I) and slightly more than +60 degrees (slightly more than perpendicular to aV_L), call it +75 degrees, and you're finished again! So, when there is no isoelectric lead, the axis will be a multiple of 15, but not 30.

Step 4, additionally, for confirmation of your work, of the six limb leads, find the lead with the tallest wave. The axis of this lead is close to the axis of the wave you are assessing. So, if the tallest QRS complex is in lead I, the axis of the QRS complex is close to 0 degrees, or if the tallest QRS complex is in lead aV_L , the axis of the QRS complex is near -30 degrees. If the tallest P wave is in lead II, the P wave axis is close to +60 degrees. This gives you a way to confirm the axis you calculated by the three steps above.

Note 1: The reason we measure the axis of a wave is to assist in interpretation of the wave. There are normal limits to axis of a wave, so determining the axis helps determine whether a wave is normal. The normal axis of the QRS complex ranges from -30 degrees to +90 degrees. If the QRS axis is less than -30 degrees, then the QRS has left axis deviation, and that raises specific diagnostic possibilities, such as inferior wall MI or left anterior fascicular block. If the axis is more than +90 degrees, then the QRS has right axis deviation, and that raises the possibility of RVH or lateral wall MI or left posterior fascicular block. These aren't the only possibilities, but the first that should be considered. Likewise, if the P wave axis is -75 degrees, the P wave is likely a retrograde P wave, beginning from the AV node.

Note 2: The rate and intervals and axis form the "Vital Signs" of the ECG. The first step in evaluating an ECG is determining these numbers. If any of the

numbers is abnormal, they are clues to abnormalities on the ECG, and lead to the appropriate diagnoses.

Note 3 = Key Note: If the QRS complex is positive in both leads I and aVF, the QRS axis is in the left lower quadrant (between 0 and 90) and is normal. If the QRS complex is positive in both leads I and II, the QRS axis is between -30 and +90 degrees and is normal. If the QRS complex is positive in lead I and negative in lead II, there is left axis deviation. If the QRS complex is negative in lead I and positive in lead aVF, it is right axis deviation. If the QRS complex is negative in both I and aVF, the QRS complex is right superior axis (or “northwest axis”, very abnormal).

Diagnosis	Axis (degrees)	Lead projections
Normal	-30 to 90	Up in I, up in II
Left Axis Deviation	-90 to -30	Up in I, down in II
Right Axis Deviation	90 to 180	Down in I, up in aVF
Northwest Axis	180 to 270	Down in I, down in aVF

Part B: Steps to interpreting the ECG

1. Check the Standardization, then obtain the Vital Signs

- a) The standardization marker height and width should be 10 mm high and 5 mm wide
- b) The atrial and ventricular rates should be the same and should be between 60 and 100 per minute (15-25mm between successive waves)
- c) The PR, QRS, and QT intervals should be within the ranges listed above.
- d) Determine whether the QRS axis is normal, left axis deviation or right axis deviation
- e) Circle all abnormal vital signs, because they require a diagnostic explanation

Normal rate is between 60 and 100 /min, and

The rhythm should be generally regular

Rate below 60 is bradycardia by definition (or below 50, according to some)

Bradycardia may be normal in well-conditioned individuals or during sleep, or may be caused by medications such as beta-blockers or heart rate-lowering calcium blockers like verapamil or diltiazem

Rate above 100 is tachycardia by definition

Tachycardia usually indicates heart disease or excess sympathetic tone or both

2. P wave: ("cherchez le P", look for the P wave! from Marriott)

Normal P is uniform in configuration from beat to beat

Normal P wave is upright in leads I, II and aV_F

Normal P duration 0.06-0.10 sec

Normal P height usually less than 2.5mm (usually tallest in lead II)

In V₁, the P wave is usually biphasic (the initial part of the P goes up, and the terminal part goes down)

3. PR interval

From the beginning of the P wave to the beginning of the QRS, contains both the P wave and the PR segment (the short straight line between the P wave and the QRS complex)

Normally is constant from one beat to the next, and from 0.12-0.20 sec in adults (twice the normal P wave duration)

Normally the PR segment is at the same baseline level as the segment before the P wave (T-P segment)

4. QRS complex

Axis is normally between -30 and +90 degrees

Duration normally from 0.06-0.10 sec (same as P wave duration)

Q waves

Normally less than 0.03 sec (3/4 mm) wide in leads I, II, III, aV_L, aV_F, V₅ and V₆ and depth less than 25% of the height of the R wave

Normally less than 0.02 sec (1/2 mm) in lead V₄ and not deep

Normally absent in V₁ to V₃, definitely absent in V₂-V₃

R waves

Normally increase in size from V₁ to V₄, called R wave progression,

Deflection usually positive by V₄ (R greater than S),

usually negative in V₁ (S greater than R)

Normally none is greater than 20mm in limb leads

Normally none is greater than 30mm in chest leads

Normally at least one limb lead is over 5 mm in R+S voltage

Normally at least one chest lead is over 10 mm in R+S voltage

S waves

Normally increase from V₁, to V₂, then decrease from V₃ to V₆

5. ST segment

(during the plateau phase of the ventricular action potential)

Generally begins horizontally then curves gently into the T wave

Generally begins at the level of both the PR segment and the TP segment

May be displaced 1 mm in the direction of the following T wave (early repolarization)

6. T wave

Smooth, rounded, monophasic or diphasic, more gradual onset and more sudden offset.

Amplitude diminishes with age, larger in men, should be larger than U wave if present

Amplitude usually less than 5 mm in limb leads, and less than 10 mm in chest leads

Amplitude usually less than 3 mm in III and aV_L and less than 5 mm in V₁ and V₆

Direction similar to QRS, so if the QRS is upright, the T wave should usually be upright, and vice versa

Direction in transverse plane: variable in V₁, upright T in V₂ to V₆

Tall and peaked in hyperkalemia, small and flattened in hypokalemia

7. U wave

May be absent

Larger or more prominent in bradycardia, (if larger than T wave, indicates hypokalemia)

Same direction as T wave, but only about 10% of amplitude of T wave, less than 1 mm tall

8. QTc interval

A measure of duration of activation and recovery of ventricular myocardium

Normal QT interval varies inversely with heart rate, generally less than half the RR interval

QT interval corrected for heart rate is called QTc

QTc = QT/(square root of the R-R interval), called Bazett's formula.

Normal QTc is 0.41 seconds

Slightly longer in women and older people

Should be measured after a series of regular cycles

9. Analyzing the Rhythm

A) Rate and Regularity

1) The normal rhythm is normal sinus rhythm, with normal findings as noted above for P wave uniformity and rate and PR interval

2) Due to continual variation in autonomic tone the sinus node may normally vary its rate slightly, synchronous with respiration (inspiration gives increase in rate, called respiratory phasic sinus arrhythmia)

B) P wave morphology:

1) P wave axis in the left lower quadrant (between 0 and 90 degrees) indicates that the rhythm is originating in the sinus

node (SA or sinoatrial node), the normal pacemaker of the heart (normal sinus rhythm, or NSR, or sinus rhythm).

- 2) When a P wave is slightly upright in lead I but is inverted in II, III, and aV_F, the P wave is likely originating in the area of the AV node and is conducting retrograde through the atrium, indicating abnormal rhythm.

c) Finding the P wave:

- 1) In normal sinus rhythm, there is usually no problem finding the P wave displayed prominently in front of the QRS complex, but in other circumstances, the P may be hard to find
- 2) Hard P waves to find (this section is for future reference):
 - (a) Sometimes the rhythm is sinus, and the P wave is in front of the QRS, but the P wave may be very small. Other times, the rhythm is sinus, but the rate is fast, and the P wave in front of the QRS is riding on the downslope of the T wave of the preceding beat.
 - (b) In complete heart block, some P waves may be buried inside a QRS complex. To find these, note the usual distance between two successive P waves and "march" forward and backward from definite P waves to see if a P wave occurring at the usual distance would fall inside a QRS. All the P waves must be found so that the proper atrial rate may be determined.
 - (c) In second degree AV block, some P waves may occur during an ST segment or during a T wave, creating a distortion of the usual shape, like a "wart" on the ST segment or the T wave.
 - (d) Premature atrial complexes (PAC's) frequently occur during ventricular depolarization, also showing a distortion of the ST segment or the T wave. If the PAC is nonconducted, it will be only a distortion of the ventricular repolarization (again, a "wart" on the T wave or in the ST segment) without any QRS to provide a clue to its presence, but often a pause in the rhythm because the PAC resets the sinus node.
 - (e) In some instances of junctional rhythm, the P wave may be buried in the QRS for every beat, giving no definite atrial activity, so no P waves are seen at all. In such a situation, it is unsure whether the atrium is contracting. In other instances of junctional rhythm, the P wave may be after the QRS early in the ST segment or right at the end of the QRS (again, a "wart" on the T wave or in the ST segment), and will be inverted in II, III, and aV_F.

- (f) In patients with electronic pacemaker of the atrium ("electronic atrial pacemaker"), the P wave after the atrial pacing spike may be hard to see. The presence of such a P wave may be inferred with confidence if there is a constant and relatively normal PR interval between the spike of the atrial pacemaker and the beginning of the QRS complex.
 - (g) Difficulty also arises when trying to decide among the rapid atrial rhythms, such as multifocal atrial tachycardia and atrial fibrillation and atrial flutter, and the distinctions between these are explained elsewhere in this document.
- D) PR interval 0.12-0.20 sec
- 1) Short PR interval: <0.12 sec, causes include non-sinus atrial or junctional rhythm, and ventricular pre-excitation (WPW)
 - 2) Long PR interval: >0.20 sec, AV node is slow in conduction
 - 3) Variable PR interval: definitely abnormal, always indicating an interesting dysrhythmia
 - (a) Wenckebach-type second-degree AV block
 - (b) Complete heart block (third degree)
 - (c) AV dissociation with ventricular rate faster than atrial rate
- E) QRS complex: morphology which may predispose to dysrhythmia
- 1) Slurred onset of QRS complex with short PR interval suggests pre-excitation (WPW)
 - 2) Normal QRS complex with short PR interval suggests pre-excitation (not WPW)
 - 3) Wide QRS (> 0.10 sec duration) indicates one of many abnormalities (LBBB, RBBB, IVCD, WPW, electronically paced QRS or QRS originating from the ventricle itself), may predispose to dysrhythmia
- F) Repolarization morphology which may predispose to dysrhythmia
- 1) ST segment elevation (indicating acute transmural ischemia or injury, probably myocardial infarction, also can indicate hyperkalemia) or depression (indicating possible acute subendocardial ischemia or injury or possibly infarction or secondary change from a depolarization abnormality such as ventricular hypertrophy or bundle branch block)
 - 2) Increase in T amplitude - may indicate hyperkalemia or hyperacute phase of myocardial infarction
 - 3) Decrease in T amplitude - may indicate electrolyte imbalance such as hypokalemia or ischemia
 - 4) Prolonged QTc - risk for ventricular arrhythmias, most likely due to pharmaceutical or ischemia, electrolyte imbalance, congenital problem, or wide QRS

- 5) Increase in U wave amplitude - electrolyte imbalance, specifically hypokalemia

Section II: Abnormalities of the ECG

Part A: Chamber Hypertrophy or Enlargement

Atrial abnormalities

Usually accompanied by LVH or RVH or both

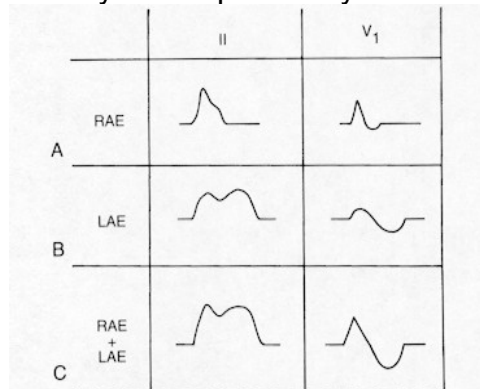


Figure 4.1. The changes in P wave morphology, typical of atrial enlargement as they appear in leads II and V₁. **A.** Right atrial enlargement (RAE). **B.** Left atrial enlargement (LAE). **C.** Biatrial enlargement (RAE + LAE).

RAE (Right atrial enlargement or right atrial abnormality, also "P pulmonale")

Peaked P wave in lead II, over 2.5mm tall, P duration <0.12 sec
P axis often >70 degrees

Also in lead V₁, the P initial force is often tall and peaked

LAE (Left atrial enlargement or left atrial abnormality, also "P mitrale")

Wide notched P in lead II, over 3 mm wide

Best criterion: P terminal force (end of the P wave)

At least 1 mm (0.10mV) deep and 1 mm (0.04sec) wide in lead V₁

Also, 0.04 sec distance between the peaks of the notch in lead II

LAE can come and go day by day, depending on LA pressure

Therefore the appearance of LAE might signal worsening CHF

LVH -

- I) When the left ventricular mass increases in response to a stimulus (usually pressure or volume overload), the electrical forces of the left ventricle also increase. This increase is seen on the ECG by larger QRS complexes. Since the left ventricle is located on the left and inferior and somewhat posterior portion of the heart, the larger voltage in the QRS is directed posteriorly and leftward and inferiorly. That means that the QRS complex will be deeper in V₁₋₂, taller in 2, 3, and F, and taller in V₅₋₆. When the ventricle becomes thicker, the depolarization takes longer to be

conducted, so the QRS duration prolongs slightly. Repolarization is frequently disturbed by the LVH, with the T wave often directed away from the main QRS direction (called "discordant"). So, if the QRS is tall, the T will often be inverted, and if the QRS is deeply negative, the T will often be tall and positive. Likewise, the ST segment may be displaced in a direction similar to the discordant T wave. Additionally, the left atrium is frequently stressed by LVH, so left atrial abnormality is often present, with criteria as described above. These findings in LVH are formalized in an assessment algorithm that follows:

- II) Criteria: Use a point score system and add up the points. A total of 5 points is LVH and 4 points is probable LVH. The most important of the criteria is voltage. Second is left atrial enlargement. Here are the Romhilt-Estes Criteria:
- A) Voltage criteria (any one of these)- 3 points
 - 1) R or S in any limb lead at least 20mm (2.0mV) OR
 - 2) [S in V1 or V2] or [R in V5 or V6] at least 30 mm (3.0mV)
 - 3) Other criteria you may see:
 - (a) Cornell criteria, described in III. below
 - (b) [S in V1 or V2] plus [R in V5 or V6] at least 35 mm (0.35mV)
 - (c) R in aVL at least 11 mm or 13 mm
 - (d) Sokolow-Lyon criterion, R in I plus S in III over 25 mm
 - B) Repolarization abnormality - (if on digitalis, only 1 point) 3 points
ST segment and T wave discordant from QRS complex especially in V5-V6 with ST depression and T wave inversion
 - C) Left atrial enlargement in V1 (criteria above) - 3 points
 - D) QRS duration 0.09 to 0.10 sec - 2 points
 (if longer, consider another diagnosis, like LBBB)
 - E) Left axis deviation superior to -30 degrees (don't use) 2 points
 - F) Intrinsicoid deflection in V5 or V6 longer than 0.05 sec 1 point
 - 1) Measure from onset of QRS to the peak of the R wave
 - 2) Also called "R peak time"
- III) Cornell voltage Criteria
- A) Women: R wave in aVL + S wave in lead V3 >2.0mV
 - B) Men: R wave in aVL + S wave in lead V3 >2.8mV
- IV) The voltage criteria do not apply to young people, since they were studied in patients over 40 years old, and if applied to young athletic people, can erroneously diagnose LVH

RVH -

- I) ECG diagnosis is tougher than LVH, because the normal ECG is dominated by the LV, so the RV has to hypertrophy dramatically to overcome LV forces and manifest on the ECG. RV forces are normally anteriorly and rightward. So, at its best, the sensitivity of the ECG for RVH is probably only about 20%, and specificity is maybe 80%, depending on

- which criteria and patient populations are involved. Since the right ventricle is the anterior and rightward portion of the heart, hypertrophy of the right ventricle is seen in amplification of rightward and anterior forces, and diagnosis is made using the criteria below.
- II) Criteria often used (there is not a generally accepted point score system)
- A) Right axis deviation >110 degrees
 Note: Other causes of right axis deviation besides RVH in patients without prolonged QRS duration: normal variant in young adults, COPD without cor pulmonale, lateral myocardial infarction, and left posterior hemiblock. Also, a technician error with reversal of the left and right arm leads, which can be recognized by the inverted P wave seen in lead I in arm lead reversal.
 - B) Prominent anterior forces: R/S in V1 >1 (R wave larger than S wave in V1), also abnormal is R/S is greater than 1 in V3R, a lead that is in the position of V3, but on the right side of the sternum.
 Note: Other causes of prominent anterior forces besides RVH in patients without prolonged QRS duration: normal variant in young adults, true posterior myocardial infarction, pulmonary disease, WPW pattern (the latter with QRS widening)
 - C) Prominent anterior forces: R in V1 > 7 mm
 - D) S in V1 < 2 mm
 - E) qR pattern in V1 (little Q wave then big R wave)
 - F) r-S-R-prime in V1 with R-prime > 10 mm
 - G) Supporting: ST depression and T inversion in V1-V2

Part B: Intraventricular Conduction Abnormalities

LBBB - Left Bundle Branch Block, the delay is a leftward posterior mid-QRS conduction delay

- I) QRS duration ≥ 0.12 sec AND
- II) Broad R in I, V5, and V6, usually notched or slurred, no good sharp peak, because there is a mid-QRS delay
- III) Absent Q waves in I, V5, and V6, because the normal septal activation from the left septal surface to the right septal surface from the left bundle is absent, so the septum is activated from right to left.
 - A) Therefore the initial forces are directed leftward.
 - B) Since the initial forces are distorted by LBBB, old myocardial infarctions cannot be diagnosed in the presence of LBBB
- IV) Delay of onset of the intrinsicoid deflection (R peak time) in V5 and V6 to 0.06 sec
- V) ST segment and T wave are directed opposite to the main QRS deflection.

- A) Generally, any depolarization abnormality will have a characteristic consequent repolarization abnormality.
- B) Since the ST segment and the T wave are distorted by the depolarization abnormality, the ST segment is not interpretable for treadmill tests in LBBB
- VI) Although not a criterion, it is helpful to note that there is a broad deep S wave in V1... a big one
- VII) INCOMPLETE LBBB - as for complete LBBB except QRS duration only 0.10-0.11

RBBB - Right Bundle Branch Block, the delay is a rightward anterior terminal conduction delay (contrast with LBBB above)

- I) QRS duration ≥ 0.12 sec AND
- II) rsR-prime wave in V1 or V2 (the R-prime is the terminal delay) with R-prime larger than initial R wave (so the second rabbit ear is taller than the first). The width of the R prime in V1 is often 0.06 sec. NOTE: if the patient has lost the initial small R wave in V1, and the QRS in V1 begins with a Q wave, then the terminal delay in V1 will be a qR pattern instead of a rsR-prime. The important thing is that the terminal forces (the final forces at the end of the QRS) are positive in V1, and slurred, with a width of 0.06 sec or so
- III) Intrinsicoid deflection in V1 or V2 later than 0.05 sec (remember that intrinsicoid deflection is also called "R peak time", and is duration from the onset of the QRS forces to the peak of the R wave)
- IV) Wide (slurred) S wave in I, V5, and V6, often with a very distinct onset
- V) Since the initial forces are not disturbed in RBBB, old myocardial infarctions may be diagnosed in the presence of RBBB
- VI) Repolarization:
 - A) the ST segment is generally normal (except maybe depressed in V1 or v2), and
 - B) The T wave is directed opposite the terminal delay (down in V1-V2, up in I, V5, and V6).
 - C) Since the ST segment is normal, the treadmill test can be used for diagnosis of ischemia using ST depression in leads V5 and V6 (but not V1 and V2)
- VII) INCOMPLETE RBBB - as for complete RBBB except QRS duration only 0.09-0.11, and terminal delay is shorter, so width of R prime is less
- VIII) Distinguish from Normal Variant R-S-R-prime in V1-V2, where the QRS duration is normal and the R prime is less than 6 mm tall, and the R prime is brief, without real delay, and there are no criteria for RVH

Fascicular Blocks (Hemiblocks)

- I) Left anterior fascicular block (left anterior hemiblock, LAFB): all of the first three criteria must be present
 - A) Left axis deviation -45 to -90 degrees (-30 to -45 degrees is probable or possible, not definite)
 - Other causes of left axis deviation:
 - B) A qR complex or an R wave in leads I and aVL; and an rS complex in leads II, III, and aVF
 - C) Normal or slightly prolonged QRS duration
 - D) Usually poor precordial R wave progression and often persistent S waves in V5 and V6
 - E) Repolarization: T usually upright in II, III, and aVF and precordial leads, resulting in a wide angle between the QRS axis and the T axis, with the QRS axis about -45 degrees and the T wave axis about $+75$ degrees
- II) Left posterior fascicular block (left posterior hemiblock, LPFB, these are rare): all of the first three criteria must be present
 - A) Right axis deviation $+90$ to $+180$ degrees, better if $+110$ or greater
 - B) S in I and Q in III
 - C) Normal or slightly prolonged QRS duration
 - D) Repolarization: T usually more superiorly displaced, often inverted in II, III, and aVF
- III) Combinations of Conduction abnormalities
 - A) Bifascicular blocks
 - 1) RBBB plus LAFB, the criteria are additive; usual criteria of RBBB, and the first half or first 0.06 sec of the QRS complex have an axis of -30 to -90 degrees in the frontal plane, with an initial r in II, III, and aVF
 - 2) RBBB plus LPFB, the criteria are additive
 - B) Trifascicular block - bifascicular block plus first or second degree AV block

IVCD, Peri-infarction blocks -

- I) IVCD (intraventricular conduction delay or defect)
 - A) QRS duration 0.11 sec or more without LBBB or RBBB criteria
 - B) Also called nonspecific or diffuse IVCD
 - C) A small notch in the QRS with normal QRS duration is insignificant and is best not called an IVCD but rather ignored (for completeness, the diagnosis of minor IVCD may be added)
- II) Peri-infarction block - after a transmural myocardial infarction, especially an inferior or lateral infarction, there may be a mild terminal delay directed toward the infarcted area. This will be seen as a slurred downstroke of the R wave in a lead with a pathologic Q wave

- WPW - (Wolff-Parkinson-White Syndrome, also called Pre-excitation)
- I) Original description was 1930 and included
 - A) Short PR interval
 - B) Wide QRS complex with slurred initial forces (initial force is "delta wave")
 - C) Paroxysmal tachycardia (usually supraventricular)
 - II) Every beat is a fusion beat
 - A) DEFINITION: A fusion beat is a beat caused by simultaneous transmission of impulses from more than one focus resulting in a hybrid complex, some of the ventricular cells depolarized from one focus and the rest of the cells from the other focus, so the QRS form is intermediate in morphology between the morphology of either of the single focus complexes
 - B) Part of the QRS is caused by conduction through the AV node and His-Purkinje system
 - C) Part of the QRS is caused by conduction through the accessory AV connection (called "Bundle of Kent") from atrial muscle to ventricular muscle
 - D) The relative contribution of each conduction pathway determines how wide the QRS is and how large and prominent the delta wave is, and how short the PR interval is. The more abnormal the QRS, the more "pre-excited" the ventricle.
 - III) Tachycardias are often due to electrical activity traveling in a circular pathway that includes the atrium, the ventricle, and the AV node and the accessory pathway. This circular electrical activity is called circus movement tachycardia, and it is specifically called atrioventricular reciprocating (or reentrant) tachycardia (AVRT) when the pathway includes all 4 of these structures.
 - IV) Criteria for WPW pattern (for the "WPW syndrome", must have paroxysmal supraventricular tachycardias)
 - A) PR interval less than 0.12 sec
 - B) QRS duration at least 0.11 sec
 - C) Initial slurring of QRS, delta wave - the most important criterion
 - D) Secondary ST segment and T wave abnormality
 - E) Frequent association of paroxysmal tachycardia
 - F) The manifestations of pre-excitation may be intermittent

Part C: Ischemia, Injury and Infarction, and Repolarization Abnormalities

- I) Review of physiology of infarction: Coronary blood supply must meet the demands of the myocardium (supply-demand balance)
 - A) Oxygen extraction of coronary flow is maximal at rest, so any increase in oxygen delivery must come from reserve in coronary flow volume, which normally can increase about four-fold

- B) Oxygen demand of myocardium is increased by mainly by increases in heart rate, contractility, chamber diameter, and systolic pressure
 - C) Oxygen supply to myocardium is impaired by obstruction to coronary flow, but also potentially by problems in oxygen carrying capacity of the blood from anemia, hypoxia, or hemoglobin abnormalities
 - D) Infarction generally requires total absence of blood supply for at least 45 min or so, and infarction is first seen in the more vulnerable subendocardium and spreads toward the epicardium as the absence of blood supply persists
- II) Ischemia, Injury, Infarction definition and ECG findings
- (a) T wave abnormalities are not generally specific, so are often called nonspecific T wave abnormality. They could be from ischemia, hypertrophy, electrolyte abnormality or a host of other things_
 - B) Ischemia - Generally a clinically significant imbalance in supply/demand than ischemia, is seen on ECG as ST segment abnormalities
 - 1) ECG: ST elevation points toward the area of transmural ("subepicardial") ischemia or injury, that is, ST elevation in the affected leads - so ST elevation localizes the problem area
 - (a) Usually elevation is at least a full 1 mm or more, sometimes 10-15 mm, often is concave downward, called "coving"
 - (b) A mere 1 or 2 mm elevation seen in V2, also possibly V1 and V3, in the setting of normal deep S waves is usually normal, and especially in the setting of LBBB or LVH
 - (c) Transmural injury pattern is very important in management: in an appropriate clinical setting of chest pain or other symptoms suspicious for myocardial infarction, this pattern constitutes an indication for either thrombolytic therapy or emergent cardiac catheterization for locating and opening an occluded coronary artery ("STEMI")
 - 2) ECG: ST depression means subendocardial ischemia or injury, and does not localize to any particular segment of the LV, only indicates injury somewhere (may have ST depression in "NSTEMI")
 - C) Infarction - Irreversible loss of myocardial cells, replaced by electrically silent scar tissue
 - 1) ECG: initial forces of QRS complex are directed away from the area of the infarction, that is, loss of R wave or abnormal Q wave in the affected leads
 - 2) Pathologic Q wave is usually 0.04 sec wide and 25% (some say 33%) of the height of the R wave
 - 3) The diagnosis of a Non-Q MI cannot be made on a single ECG, whereas the diagnosis of a Q wave MI can. The ECG

criterion for diagnosis of a non-Q MI (NQMI) is an abnormality which is limited to repolarization change which persists and evolves over a period of at least 24-72 hours

- III) Localization of Ischemia or Infarction by affected leads - This mainly applies to Q waves of infarction and transmural injury (ST segment elevation). Generally Q waves are the most localized, and ST segment elevation is somewhat more widespread.
- A) Inferior - II, III, aVF
 - B) Inferolateral - II, III, and aVF and abnormal in V4 - V6
 - C) Anteroseptal - V1 - V3, sometimes V4 too
 - D) Anterior - one or more of leads V2 - V4 (an anterior infarction can also be diagnosed without a Q wave in these leads if there is a reversal of the normal R wave progression such that the R wave gets smaller and/or the R/S ratio gets smaller from V2 to V3 or V3 to V4, and so on)
 - E) Anterolateral - V5 - V6 and sometimes V4 too, with I and aVL
 - F) Extensive anterior - nearly all of V1 - V6, also maybe I and aVL
 - G) High lateral, or just "lateral" - I, aVL
 - H) True posterior - TRICKY - there are no leads directed posteriorly, so you must look at the anterior leads upside down to see the analogous QRS and ST and T abnormalities. When looking at the leads upside down, be careful not to reverse the time sequence.
 - 1) Wide tall R wave in V1 or V2 (>0.04 sec and taller than S wave) is the pathologic "Q" wave
 - 2) ST depression in V1 or V2 is the transmural injury pattern
 - 3) Tall peaked T waves in V1 or V2 are the ischemic "T wave inversion"
 - 4) To determine whether a wide tall R wave in V1 or V2 is due to a true posterior MI or to RVH, look for the company it keeps
 - (a) If the limb leads show right axis deviation with an rS in lead I or RAE with peaked P in lead II, then the large R in V1 is probably RVH
 - (b) If the limb leads show no right axis deviation or RAE, but show pathologic Q's in II, III, and aVF, then the large R in V1 is probably a true posterior MI
 - (c) If neither of these is present, but there are deep S waves in V5-6, the large R in V1 is probably RVH
 - (d) If none of these is present, including (c), then the large R in V1 is probably a true posterior MI
 - I) Inferoposterior - criteria for inferior and posterior
 - J) Posterolateral - criteria for posterior and for anterolateral
- IV) Time course of infarction in the absence of reperfusion (The time course of ECG changes may be altered drastically when early intervention is successful in reperfusion of the myocardium)

- A) Hyperacute T wave is a peaked T wave pointing toward the area of infarction, only the first few minutes of infarction, infrequently seen
- B) ST depression, doesn't localize, generally means "Non-Q MI", usually normalizes in 24-72 hours in NQMI
- C) ST elevation does localize, KEY FEATURE, begins in minutes and is maximal for the first 7-12 hr, and is the best ECG criterion for quick intervention in an acute MI, with either thrombolysis or direct angioplasty of the culprit vessel
- D) Q wave formation - Begins at 6-12 hrs, may be permanent, a minority will shrink over months to years
- E) T wave inversion - Begins after a day or a few days, normalizes in months to years, variable
- F) ST segment normalizes in 2 to 8 weeks, unless LV aneurysm has developed which has persistent elevation
- G) Criteria for infarction age:
 - 1) Acute MI - ST elevation, with upright T wave and pathologic Q wave
 - 2) Recent MI - pathologic Q wave with ST elevation and T wave inversion
 - 3) Old MI - pathologic Q wave without ST elevation or T inversion
 - 4) MI, age indeterminate - pathologic Q wave without ST elevation, with T inversion
- V) Examples of Readings from Abnormalities
 - A) ECG that has ST elevation and no Q wave and upright T wave in II, III, and aV_F is acute inferior wall transmural injury and needs immediate attention (fibrinolysis or PCI).
 - B) ECG that has abnormal Q waves in V5-V6 with no ST deviation and upright T wave is old lateral MI.
 - C) ECG that has very large and wide R waves in V1-V2 and abnormal Q waves in II, III, and aV_F and upright T waves and no ST deviation is old inferoposterior MI. If this ECG had T inversion in the inferior leads it would be inferoposterior MI, age indeterminate.
 - D) ECG that has ST depression in II, III, and aV_F and V5-V6 is Subendocardial injury (cannot localize).
- VI) Other Repolarization abnormalities -
 - A) Pericarditis – Interesting trivia: the pericardium is electrically silent, so the ECG changes actually reflect subepicardial injury from the adjacent epicardium
 - 1) PR segment discordant displacement (PR segment depressed in leads with tallest P waves or elevated in aVR)
 - 2) HALLMARK: Diffuse ST segment elevation in almost all leads, usually not much more than 4 to 5 mm, often only 1 to 2 mm, often associated with lowish voltage T waves, and generally the shape of the ST segment is concave upward. To distinguish this ST elevation from transmural injury is

usually not difficult. The ST elevation in transmural injury usually is much more localized, and there is usually associated "reciprocal ST depression" in transmural injury. To distinguish this ST elevation from normal variant, early repolarization may be very difficult or impossible. If there is PR segment depression, then likely the diagnosis is pericarditis. If there is a little positive terminal delay (notch) in the QRS complex in V5-6, then likely the diagnosis is early repolarization. If the T wave is tall, then likely the diagnosis is early repolarization.

- 3) T wave inversion, usually generalized and discordant from the QRS, happens usually later, after a couple of weeks or so, and represents a phase in evolution of the process. These inversions are generally less deep than in evolving MI. In pericarditis, often the ECG returns to normal over a month or so.
- 4) Generally the ST segment returns to baseline before the T wave starts to invert, in contrast to MI
- 5) Generally there is no change in the QRS complex, in contrast to MI

B) Electrolyte abnormalities

- 1) Hypokalemia - T wave becomes low amplitude and U wave enlarges, so U may be as large as T wave, also predisposition to atrial and ventricular arrhythmias
- 2) Hyperkalemia - first, T wave becomes tall and with sharp peak ("peaked T waves"), then first degree AV block and smaller voltage P wave, then QRS complex widens progressively till it looks like a sine wave. Hyperkalemia can also look like acute MI with ST elevation, so it can mimic both MI and Pericarditis.
- 3) Hypercalcemia - decrease in QTc interval is proportional to ionized Calcium level, due to shortening of the ST segment, with generally preserved T wave shape and duration
- 4) Hypocalcemia - increase in the QTc interval is proportional to ionized Calcium level, due to lengthening the ST segment
- 5) Hypermagnesemia or hypomagnesemia - changes are subtle. Hypomagnesemia may look like hypokalemia

C) QT prolongation

- 1) Congenital long-QT syndrome is a series of congenital abnormalities of action potential currents, which result in repolarization abnormalities and QTc of >460 msec. Several gene defects have been discovered affecting currents of Potassium and Sodium. Different gene defects produce different ECG abnormalities, and the specifics of these differences are just recently being clarified. The T wave may be broad or low amplitude or cleft, or show T wave

- alternans, and sudden cardiac death or family history of sudden cardiac death are the hallmarks of this syndrome
- 2) Metabolic abnormalities producing QT prolongation, especially medication-induced changes, such as by antiarrhythmic agents as well as other medications such as some antihistamine-antibiotic combinations, and these may also produce sudden cardiac death
 - 3) Ischemia and hypertrophy produce QT interval prolongation as a secondary repolarization abnormality
- D) CNS abnormalities may give diffuse T wave inversion and striking QT prolongation
- E) Normal variant, Early Repolarization
- 1) Often seen in healthy asymptomatic young persons
 - 2) ST elevation similar to pericarditis, but stable over time, and usually with tall T waves rather than lowish voltage T waves, so the T wave height is at least 4 times the ST elevation height
 - 3) Often a little terminal notch in the QRS (sometimes called a J wave, since it is at the J point)
 - 4) No PR segment depression
- F) Normal variant, persistent juvenile pattern - T wave inversion in V1-V3 in normal young adult, will be stable for months to years
- (a) Nonspecific ST-T wave abnormality
 - 2) Indicates that ST segment and T wave are not normal, but the cause is not apparent
 - 3) Example: flat T waves or slightly inverted T waves or mild ST depression of less than a millimeter
 - 4) Causes include ischemic heart disease, hypertrophy, pericardial abnormalities, drug effects or electrolyte or metabolic abnormalities, myocarditis, as well as even abdominal problems
- G) Secondary repolarization abnormalities - every depolarization abnormality has a consequent repolarization abnormality – these are discussed in the sections describing the depolarization abnormalities
- 1) Hypertrophy: LVH, RVH
 - 2) Conduction abnormality: LBBB, RBBB, LAFB, LPFB, WPW

Section III: Normal and Abnormal Rhythms

- I) Sinus Rhythms
- A) NSR (normal sinus rhythm) - Needs all of the following:
 - 1) Rate 60-100 (some say 50-100)
 - 2) P wave axis 0-70 degrees (upright in I and II)
 - 3) PR interval 0.12-0.20 sec.
 - 4) P wave uniformity

- 5) P-P interval regularity
- B) Sinus arrhythmia - NSR (that is, all P waves are uniform with normal P wave axis) but with P-P interval irregular (PP interval varies by 0.16 sec) with gradual changes in PP interval
- 1) Respiratory-phasic sinus arrhythmia
 - (i) normal in youth and healthy due to vagal tone fluctuation
 - (ii) increase in rate with inspiration due to increase right heart filling
 - 2) Non-respiratory phasic sinus arrhythmia - in older patients
 - 3) Ventriculophasic sinus arrhythmia - in AV block only (the P-P interval after an intervening QRS complex is longer than the P-P interval not after a QRS) - interesting to speculate on mechanism, possibly due to brief vagal discharge provoked by the arterial pulse caused by the QRS
- C) Sinus tachycardia - same as NSR but rate >100
- D) Sinus bradycardia - same as NSR but rate <60
- E) Sinus or SA arrest or pause - failure of SA node to initiate impulse, so pause occurs with no P wave, with pause not a multiple of the basic P-P interval
- F) Sinus or SA exit block - looks like sinus pause, but pause IS a multiple of the basic P-P interval, caused by on-time firing of the sinus node, but the impulse dies without depolarizing the atrium
- (i) Atrial Rhythms
- G) Wandering atrial pacemaker - gradually and progressively varying P wave morphology and P-P interval, and also to a lesser extent PR interval, which remains ≥ 0.12 sec
- H) Ectopic atrial rhythm - like sinus rhythm, but P wave axis and morphology not normal
- I) Ectopic atrial tachycardia (also called atrial tachycardia)- like ectopic atrial rhythm, but rate over 100
- 1) Can be automatic or reentrant in mechanism
 - 2) Can conduct 1:1 (one QRS for every P wave), or can show some level of AV block, usually when atrial rate is fast (150-250 beat/min)
- J) PAC (Premature atrial complex) - early different P wave, usually with normal PR interval
- 1) Look carefully for these P waves! "Cherchez le P" - they may look like a wart on a T wave
 - 2) PAC with normal conduction - normal QRS - the most common, the atrial impulse is early, but ventricle is ready
 - 3) PAC with aberrant conduction - aberrant (wide) QRS - atrial impulse comes so early that the ventricle is partially refractory, most often in a RBBB pattern

- 4) Nonconducted PAC – P wave not followed by QRS - atrial impulse comes so early that the ventricle is completely refractory
 - (a) Can be tricky - must distinguish from second degree heart block or sinus pause (but in neither of these does the P wave come early and different like occurs in PAC)
 - (b) The commonest cause of a pause
- K) Atrial flutter
 - 1) organized atrial rhythm at rate 250-350 waves per minute, will be consistent throughout the entire rhythm strip
 - 2) atrial flutter waves usually best seen in II, III, and aVF, look like sawtooth
 - 3) ventricular response (QRS complexes)
 - (a) May be half of atrial rate and regular - watch out for regular rate of 150!
 - (b) may alternate 2:1 with 4:1
 - (c) may be irregular
- L) Atrial fibrillation
 - 1) Disorganized (chaotic) atrial rhythm, with average rate of fibrillation waves faster than 350-360 - IMPORTANT: even if the waves start to look organized for a few seconds, they will look disorganized in a later portion of the strip, and this variability distinguishes it from atrial flutter which is always organized
 - 2) Atrial fibrillatory waves are usually best seen in lead V1
 - 3) Ventricular rate - Moderate is 70-110, slow is slower and rapid is faster.
 - 4) Ventricular regularity (R-R interval)
 - (a) Irregularly irregular (chaotic, no clear pattern) when conducted through AV Node, the usual expected pattern
 - (b) If regular, means no conduction through the AV Node, but QRS comes from a lower escape or usurping rhythm
- M) MAT (Multifocal atrial tachycardia) - rate over 100 beats/min
 - 1) With variable P morphology and P-P interval and PR interval
 - 2) Not gradually and progressively variable distinguishing from wandering atrial pacemaker
 - 3) Variable in a jerky unpredictable fashion, requires 3 different P wave shapes and PR intervals and rate over 100
 - 4) Often indicates severe end-stage cardiac or pulmonary decompensation
- II) AV Junctional Rhythms
 - A) Junctional beat

- 1) P wave if seen has a left axis deviation, inverted in II, III, and aVF, called "retrograde P wave"
 - 2) PR interval is short, or there is no P wave preceding the QRS, in fact the P wave may occur immediately or shortly after the QRS (with R-P interval of <0.20 sec)
 - 3) QRS is generally the same as a normal sinus beat, usually narrow
- B) Junctional rhythm - also called junctional escape rhythm, all junctional beats, very regular, usually 40-50 or up to 59 beats/min
- 1) Happens because of default of the normal sinus mechanism or impairment of AV conduction
 - 2) Criteria
 - (a) P waves either not visible (hidden inside the QRS) or very close before the QRS with short PR interval, or very close after the QRS
 - (b) P waves inverted in II, III, and aVF, called "retrograde P wave"
 - (c) Rate 40-59/min
- C) Accelerated junctional rhythm - junctional rhythm but with rate usually 70-130 beats/min
- D) Junctional escape complexes - junctional beat which occurs after a pause
- E) Junctional premature complexes - junctional beat which occurs early, before the next expected sinus beat
- F) Supraventricular tachycardia (SVT, or PSVT with P indicating "paroxysmal")
- 1) Rate about 140 to 220
 - 2) Regular tachycardia with narrow or normal QRS pattern (in a patient with pre-existing bundle branch block, the QRS will be wide and will be identical to the pre-existing QRS)
 - 3) No sinus P waves present (excludes sinus tachycardia), possibly no P waves present
 - 4) Unable to determine specific mechanism of supraventricular tachycardia by the ECG tracing
 - 5) May include AVNRT and AVRT as well as other atrial tachyarrhythmias
- G) AVNRT (A-V Nodal reentrant tachycardia), reentrant circuit in the AV node
- 1) The most common form of paroxysmal supraventricular tachycardia
 - 2) Onset and termination are abrupt, may last seconds, minutes, hours, or days
 - 3) Initiation is usually by a PAC with a long PR interval, but this may have happened earlier and not be on the ECG you see
 - 4) Rate usually 140-220 beats/min

- 5) P waves have retrograde character, inverted in II, III, and aVF
 - 6) QRS usually normal or same as baseline sinus conducted QRS, but also may be aberrantly conducted due to high rate
 - 7) The AV node has 2 functionally distinct conduction pathways, slow and fast
 - (a) Common type of AVNRT is antegrade conduction down the slow pathway and retrograde conduction up the fast pathway, giving a P wave that is usually buried in the QRS or is immediately at the end of the QRS (R-P interval less than the P-R interval). So in half of these, no P is found, and in half, the P is right at the end of the QRS, giving a "pseudo S wave"
 - (b) Uncommon type of AVNRT is antegrade conduction down the fast pathway and retrograde conduction up the slow pathway, giving a P wave that is very late after the QRS, and closer to the following QRS (R-P interval greater than the P-R interval)
- H) AVRT (Atrio-ventricular re-entrant tachycardia), always with accessory AV (atrioventricular) pathway ("bundle of Kent", discussed in section on ventricular pre-excitation), comes in 2 types
- 1) Orthodromic - the impulse is conducted down the AV node and normal His-Purkinje system and retrogradely through the bypass tract, so the QRS is normal in duration and appearance - this is the most common occurrence with heart rates in the range of 140-250 beats/min. In this situation, the ECG will look very similar to the common type of AVNRT, but the retrograde P wave will be AFTER the QRS, not in it or at the end of it.
 - 2) Antidromic - the impulse is conducted retrogradely up the AV node and antegradely down the bypass tract, so the QRS is wide and abnormal, looks just like ventricular tachycardia
- III) Ventricular rhythms
- A) Ventricular beat
 - 1) No preceding premature P wave (but if the PVC is not very premature, there could be a preceding normal sinus P wave)
 - 2) QRS wide and different from native QRS, often >0.12 sec, even >0.14 sec
 - 3) May have a following P wave (retrograde conduction or V-A conduction), or may not interrupt the normal atrial rhythm
 - B) PVC (Premature ventricular complex)
 - 1) Early different QRS complex (not preceded by early different P wave)
 - 2) QRS usually wide >0.12 sec, with discordant ST segment and T wave

- 3) Often has a compensatory pause, because the conduction of the impulse from the ventricle retrogradely through the AV node may not occur at all or fast enough to reset the SA node, so the SA node fires on time, giving a pause which precisely compensates for the prematurity of the PVC
- 4) Specifics
 - (a) If each fourth beat is a PVC, this is "ventricular quadrigeminy"
 - (b) If each third beat is a PVC, this is "ventricular trigeminy"
 - (c) If every other beat is a PVC, this is "ventricular bigeminy"
 - (d) If all the PVC's look alike, they are called unifocal
 - (e) If all the PVC's don't look alike, they are called multifocal
 - (f) If a PVC occurs very early after the preceding beat, so that it begins near the peak of the preceding T wave, it is called "R-on-T phenomenon", and is considered by some to pose increased risk for sudden death. This definitely occurs in cases of prolonged QT interval, especially in bradycardic situations
 - (g) If 2 PVC's occur together without an intervening normal beat, they are called a couplet or a ventricular couplet
 - (h) If 3 PVC's occur together without an intervening normal beat, they are called a triplet or a ventricular triplet, or a short burst of ventricular tachycardia
- C) VT (Ventricular tachycardia)
 - 1) Succession of 3 or more PVC's without intervening sinus beats
 - 2) Shorter than 30 seconds - nonsustained, longer than 30 seconds - sustained
 - 3) Rate usually 140-200
 - 4) Regular or slightly irregular
 - 5) Abrupt onset and termination (some say "paroxysmal VT")
 - 6) AV dissociation, capture beats, fusion beats (Dressler beats)
 - 7) If rate less than 110, called accelerated idioventricular rhythm
 - 8) If all the QRS complexes are alike, called monomorphic VT
 - 9) If the QRS complexes are not alike and are jerkily variable, called polymorphic VT (usually in setting of acute ongoing ischemia)
 - 10) Torsades de pointes (turning of the points) - special type of polymorphic ventricular tachycardia where there is a gradual change from beat to beat of the morphology of the QRS

complexes, from having sharp points upward to having sharp points downward

- (a) Always in setting of long QT interval - medication-induced, electrolyte disturbances, intrinsic heart disease, CNS disease, congenital QT prolongation, liquid protein diet
 - (b) Rate often 200-250 beats/min
- D) Ventricular flutter - regular rhythm, like ventricular tachycardia, but QRS complexes are no longer identifiable - this diagnosis is rarely made, usually choose between VT and VF
- E) Ventricular fibrillation - irregular rhythm, chaotic, with deflections varying in amplitude and contour, rate of deflections 150 to 500. No P wave, QRS complex, or T wave visible
- F) Ventricular escape rhythm
- 1) Series of ventricular beats
 - 2) Requires default of sinus rhythm and AV junctional escape rhythms
 - 3) Usually rate is 30-40 beats/min
 - 4) Usually requires prompt attention since these rhythms may not be reliable to persist, and since the rate is so slow that there are usually symptoms
- G) Asystole - no P wave or QRS - also no pulse!
- H) Wide complex tachycardia (WCT): DIFFERENTIATING VENTRICULAR TACHYCARDIA FROM SUPRAVENTRICULAR TACHYCARDIA WITH ABERRANT CONDUCTION
- 1) Both are relatively regular, wide-QRS tachycardias
 - 2) CLINICAL CONTEXT: if the patient has a history of organic heart disease, such as coronary artery disease, myocardial infarction, or cardiomyopathy, the dysrhythmia is more likely ventricular tachycardia, but this is uncertain
 - 3) Try to obtain a 12-lead ECG during tachycardia
 - (a) Look hard for a P wave. If there is a sinus P wave before every QRS and a constant PR interval, then it is sinus tachycardia with a wide QRS. If there is AV dissociation, then it is probably VT. For further distinctions, see below under "AV dissociation" and "QRS morphology"
 - 4) Find a previous ECG
 - (a) If QRS is wide and the same on a previous ECG in sinus rhythm, it is probably supraventricular
 - (b) If the prior tracing has aberrantly conducted supraventricular beats with the same morphology as the wide QRS tachycardia, it is probably supraventricular

- (c) If the prior tracing has PVC's with the same morphology as the wide QRS tachycardia, it is probably ventricular
- (d) If there is a prior tracing with narrow complex tachycardia, and the rate is identical to the wide QRS tachycardia, it is probably supraventricular
- 5) Onset
 - (a) If onset is with PAC, probably supraventricular
 - (b) If onset is with PVC, probably ventricular
- 6) AV dissociation
 - (a) Presence of AV dissociation favors ventricular, but not conclusive
 - (i) If there is an interruption in the regularity of the tachycardia with one beat occurring early, and being more normal or narrower QRS complex, the beat is a fusion (Dressler) beat or a capture beat, and means that the tachycardia is ventricular. Reason: if an aberrant beat is conducted earlier, it should be more aberrant rather than more normal.
 - (b) Presence of 1:1 AV relationship favors supraventricular, but not conclusive
 - (i) If the R-P interval is 0.10 sec or less, then the tachycardia is likely junctional tachycardia with aberrancy and 1:1 retrograde conduction... the P wave will be retrograde in morphology
- 7) Morphology of the QRS complex - this is uncertain
 - (a) All QRS concordant in V1-V6, either all positive or all negative, favors ventricular
 - (b) QRS duration 0.14 sec or greater in RBBB pattern or 0.16 sec or greater in LBBB pattern favor ventricular
 - (c) Left axis deviation, and right superior axis, favor ventricular
 - (d) Monophasic or biphasic RBBB type of QRS in V1 favors ventricular (VT)
 - (e) LBBB pattern with rightward axis favors ventricular (VT)

Summary of characteristics of types of beats:

TYPE OF BEAT	P WAVE	PR INTERVAL	QRS COMPLEX
Sinus	Normal	Normal	Usually Normal
Atrial	Abnormal	Normal	Usually Normal
Junctional	Retrograde	Short or absent	Usually Normal
Ventricular	None	None	Abnormal

Atrioventricular Blocks, Pacemakers

- I) Atrioventricular Blocks - failure of a P wave to be followed appropriately by a QRS
- A) HINT: To diagnose AV blocks, first the regularity of the P-P interval should be established. If the P-P interval is irregular, that must be explained separately, and the pauses may not be AV block, but something else, like non-conducted PAC's
- B) First degree AV block - all beats conduct (i.e. every P wave is followed by a QRS complex), but PR interval is too long (>0.20 sec)
- C) Second degree AV block - some beats conduct but some don't, so there are more P waves than QRS's
- 1) Mobitz I (also called Wenckebach) AV Block
- (a) Progressive prolongation of the PR till the dropped beat
 - (b) Shortest PR interval is after the dropped beat
 - (c) Usually subtle progressive shortening of the RR interval till the dropped beat
 - (d) The RR interval of the dropped beat is less than twice the unblocked RR interval
 - (e) Usually block is at the AV node or junction because that is the tissue with the property of decremental conduction
 - (f) So, usually the QRS is narrow, unless the prior ECG showed wide QRS in unblocked sinus rhythm
- 2) Mobitz II AV Block
- (a) PR interval is constant (normal or slightly long) for the conducted beats
 - (b) Usually block below the AV node in the His-Purkinje system, where there is no decremental conduction
 - (c) So the QRS is usually wide
- 3) 2:1 AV block
- (a) Half the P waves don't conduct
 - (b) Could be from either Mobitz I or Mobitz II AV block mechanism
 - (c) Can't tell whether Mobitz I or Mobitz II absolutely, but if QRS is wide, more likely Mobitz II and if QRS is narrow, more likely Mobitz I
- D) High grade AV block - AV block more than 2:1, maybe 3:1, with some evidence of AV conduction, but not third degree AV block (one definition of high grade AV block is "more than 2 sequential nonconducted P waves)
- 1) The PR interval may be constant at 3:1 block
 - 2) The RR interval may be irregular, because the ventricular escape rhythm may be interrupted by early and conducted QRS complexes

- E) Third degree AV block (also called complete heart block or complete AV block)- no beats conduct, more P waves than QRS's
- 1) The P-R interval is variable and random
 - 2) The P-P interval is constant (atrial rate is regular)
 - 3) The R-R interval is constant (ventricular rate is regular)
 - (a) The ventricular rhythm may be wide QRS (ventricular escape rhythm rate 30-40) or narrow QRS (junctional escape rhythm, rate 40-50)
 - (b) Some mild irregularity of the RR interval is possible, but no irregularity due to the presence of conducted P waves

Type of Block	PR interval	RR interval	QRS complex	Which P waves cause QRS complexes
First degree	Constant and long	Regular	Usually narrow	All
Second degree, Mobitz I (Wenckebach)	Variable, progressive prolongation	Grouped beating	Usually narrow	Some
Second degree, Mobitz II	Constant for conducted beats	Irregular	Usually wide	Some
Second degree, 2:1	Constant	Regular	Wide or narrow	Some
Third degree	Variable, random	Regular	Wide or narrow	None

- II) Atrioventricular Dissociation (AV dissociation)
- A) Loss of the normal relationship between P and QRS
- 1) Different from AV block (not AV block), because in AV dissociation there are not more P waves than QRS's. There are at least as many QRS's as P's, and often more QRS's than P's
 - 2) AV dissociation is always a secondary problem, meaning that there is a more fundamental primary problem, one of the following:
 - (a) Abnormally slow atrial activity (Default)
 - (b) Abnormally fast ventricular activity (Usurpation)
 - 3) Default
 - (a) Upper rhythm is too slow
 - (b) Lower rhythm is normal escape rhythm (junctional escape or ventricular escape rhythm)
 - 4) Usurpation
 - (a) Upper rhythm is normal

- (b) Lower rhythm is too fast (such as junctional or ventricular tachycardia)
 - B) Special cases
 - 1) Isorhythmic AV dissociation - there is one P for each QRS, but the PR interval is variable, due to the fact that the atrial and ventricular rates are effectively equal. All other AV dissociations have more QRS's than P waves
 - (a) If the isorhythmic dissociation is stable, it is called synchronization
 - (b) If the isorhythmic dissociation is transient, it is called accrochage
 - 2) Complete AV dissociation - the atrial and ventricular rates are quite constant, and no effect of a P causing a QRS or a QRS causing a P can be seen
 - 3) Incomplete AV dissociation (also "interference dissociation") - although there are more QRS's than P's, evidence can be found of occasional conduction of a P to make a QRS early, or a QRS to make a P early
- III) Pacemaker Hints
 - A) Pacemaker spikes are unnaturally short, actually only about 1 msec or less, and about 1 volt or more (not millivolt) in strength, so they appear as very narrow spikes on the ECG, and their height is variable from very low to very large
 - B) Pacemaker terminology - CODE, usually 3 or 4 letters
 - 1) First letter is chamber paced
 - (a) V-Ventricle
 - (b) A-Atrium
 - (c) D-Dual chamber, a lead in both atrium and ventricle
 - 2) Second letter is chamber sensed
 - (a) Same letter code as first letter
 - (b) O- no chamber sensed
 - 3) Third letter is mode of interaction
 - (a) O-no mode of interaction
 - (b) I-pacer inhibited by interaction
 - (c) D- dual mode of interaction, inhibited or triggered
 - (d) T-triggered
 - 4) Fourth letter is special function
 - (a) R-rate-responsive
 - 5) Rarely a fifth letter is seen
 - (a) Anti-tachycardic
 - (b) Shocking (like implantable defibrillator)
 - 6) Examples
 - (a) VVI paces the ventricle, senses the ventricle and is inhibited by sensing

- (b) VOO paces the ventricle, and doesn't sense - the original pacemaker, no longer used except in magnet mode for testing
 - (c) DDD paces both atrium and ventricle, senses both atrium and ventricle, and both is triggered or inhibited, depending on what is appropriately programmed
 - (d) VVIR - a VVI with rate modulation based on a physiologic sensor, such as activity
 - (e) DDD-R does everything a DDD does, and also has rate modulation based on a physiologic sensor, such as activity
- C) Pacemaker firing
- 1) See a pacemaker spike on the ECG - a pacemaker spike is very spiky. It is a deflection that lasts only 1/4 mm on the ECG. It is so sharp and quick that it couldn't possibly be a physiologic wave of the heart itself. The truth is that the spike delivered to the heart by the pacemaker is on the order of 2 volts (not millivolts) and only 1 millisecond.
 - 2) Should occur after a pause that is appropriate for the settings of the particular pacemaker
 - 3) Failure to fire would be a pause with no spike showing up even after the programmed time (usually no more than 1 second or 1.2 seconds)
- D) Pacemaker sensing
- 1) Normally there is no pacemaker spike occurring shortly after the heart chamber depolarizes because the pacemaker is supposed to notice (sense) a depolarization, and reset to wait a while before firing
 - 2) Failure to sense would be a pacer spike shortly after the chamber depolarization
- E) Pacemaker capture
- 1) See that a pacemaker spike is immediately followed by the depolarization of the paced chamber
 - 2) Failure to capture would be a pacer spike followed by no P or QRS