

Bradycardias, AV Block and AV Dissociation

July 2010

Joe M. Moody, Jr, MD
UTHSCSA and STVAHCS

Mechanisms of Bradycardia

- Failure of impulse formation
(automaticity failure)
- Failure of impulse conduction
(conduction failure)


Mechanisms of Bradycardia

- Failure of impulse formation (automaticity failure) – not enough P waves
- Failure of impulse conduction (conduction failure) – not enough QRS complexes

Symptoms in Arrhythmia

- “Because it may be difficult for both patients and their physicians to attribute ambiguous symptoms such as fatigue to bradycardia, special vigilance must be exercised to acknowledge the patient’s concerns that may be caused by a slow heart rate.*”
- Palpitations: an unpleasant awareness of the forceful, irregular, or rapid beating of the heart
 - Thumping, flip-flopping sensation, fullness in the throat, neck or chest, a pause “as if my heart stopped”

Symptoms in Bradycardia

- Syncope or near syncope, transient dizziness or lightheadedness, or confusional states resulting from cerebral hypoperfusion
 - Fatigue, exercise intolerance, and congestive heart failure
- 
- At rest
or with
exertion
- Definite correlation of symptoms with a bradyarrhythmia is required.
 - NOT physiological sinus bradycardia (as in highly trained athletes)

More History in Bradycardia

- Syncope
 - Arrhythmic syncope is often rapid onset and brief duration without aura, not followed by postictal confusional state, maybe associated with injury; seizure activity is uncommon, as is tongue-biting or incontinence, may be flushed and tachycardic afterward
 - Neurocardiogenic syncope may be preceded by nausea, abdominal cramping, diarrhea, sweating, or yawning, and may be followed by bradycardia, pallor, sweat and fatigue
- Inquire about: medications, predisposing or precipitating factors

Indications for Temporary Pacemaker

- Hemodynamically significant bradyarrhythmias, generally symptomatic
 - Reversible (OD B-blocker or Ca-blocker)
 - Irreversible (may wait for perm, unless signific sx)
- Acute MI
 - IMI with sinus bradycardia, try atropine, but if repeated drug therapy needed, pacer may be preferable
 - IMI with late (>2d) CHB may respond to methylxanthines (aminophylline 240 mg/10 min repeat in 1 hr); pacer if sx or vent arrhyth or rate <40
 - Ant MI with CHB need pacer, mort high
 - Ant MI with new bifascicular BBB (+/- RBBB)

Indications for Temporary Pacemakers

- Transcutaneous pacing (poor stepchild; painful; only for brief use or prophylaxis)
- Transvenous pacing
 - Generally for sinus bradycardia (<50) with hypotension ($SBP < 80$) and sx unresponsive to drug therapy
 - Mobitz II second degree AV block
 - Third degree AV block

Indications for Temporary Pacemakers

- Less invasive means (e.g., pharmacologic agents and antidotes, transcutaneous cardiac pacing) have been tried without success or that success is judged to be short-lived
- The patient is experiencing profound symptomatology (e.g., severe chest pain, dyspnea, or altered state of consciousness; hypotension; shock; pulmonary edema; or acute myocardial infarction)

Recommendations for Treatment of Atrioventricular and Intraventricular Conduction Disturbances During STEMI

INTRAVENTRICULAR CONDUCTION		Atrioventricular Conduction												
		First degree AV block				Mobitz I second degree AV block				Mobitz II second degree AV block				
		Normal		ANTERIOR MI		NON-ANTERIOR		ANTERIOR MI		NON-ANTERIOR		ANTERIOR MI		NON-ANTERIOR
Normal	ACTION	CLASS	ACTION	CLASS	ACTION	CLASS	ACTION	CLASS	ACTION	CLASS	ACTION	CLASS	ACTION	CLASS
	Observe	I	Observe	I	Observe	I	Observe	IIb	Observe	IIa	Observe	III	Observe	III
	A	III	A	III	A	III	A*	III	A	III	A	III	A	III
	TC	III	TC	IIb	TC	IIb	TC	I	TC	I	TC	I	TC	I
	TV	III	TV	III	TV	III	TV	III	TV	III	TV	IIa	TV	IIa
Old or New Fascicular block (LAFB or LPFB)	Observe	I	Observe	IIb	Observe	IIb	Observe	IIb	Observe	IIb	Observe	III	Observe	III
	A	III	A	III	A	III	A*	III	A	III	A	III	A	III
	TC	IIb	TC	I	TC	IIa	TC	I	TC	I	TC	I	TC	I
	TV	III	TV	III	TV	III	TV	III	TV	III	TV	IIa	TV	IIb
Old bundle branch block	Observe	I	Observe	III	Observe	III	Observe	III	Observe	III	Observe	III	Observe	III
	A	III	A	III	A	III	A*	III	A	III	A	III	A	III
	TC	IIb	TC	I	TC	I	TC	I	TC	I	TC	I	TC	I
	TV	III	TV	IIb	TV	IIb	TV	IIb	TV	IIb	TV	IIa	TV	IIa
New bundle branch block	Observe	III	Observe	III	Observe	III	Observe	III	Observe	III	Observe	III	Observe	III
	A	III	A	III	A	III	A*	III	A	III	A	III	A	III
	TC	I	TC	I	TC	I	TC	I	TC	I	TC	IIb	TC	IIb
	TV	IIb	TV	IIa	TV	IIa	TV	IIa	TV	IIa	TV	I	TV	I
Fascicular block + RBBB	Observe	III	Observe	III	Observe	III	Observe	III	Observe	III	Observe	III	Observe	III
	A	III	A	III	A	III	A*	III	A	III	A	III	A	III
	TC	I	TC	I	TC	I	TC	I	TC	I	TC	IIb	TC	IIb
	TV	IIb	TV	IIa	TV	IIa	TV	IIa	TV	IIa	TV	I	TV	I
Alternating left and right bundle branch block	Observe	III	Observe	III	Observe	III	Observe	III	Observe	III	Observe	III	Observe	III
	A	III	A	III	A	III	A*	III	A	III	A	III	A	III
	TC	IIb	TC	IIb	TC	IIb	TC	IIb	TC	IIb	TC	IIb	TC	IIb
	TV	I	TV	I	TV	I	TV	I	TV	I	TV	I	TV	I

A, and A*: atropine administered at 0.6 to 1.0 mg intravenously every 5 minutes to up to 0.04 mg/kg

Temporary Pacemakers in STEMI

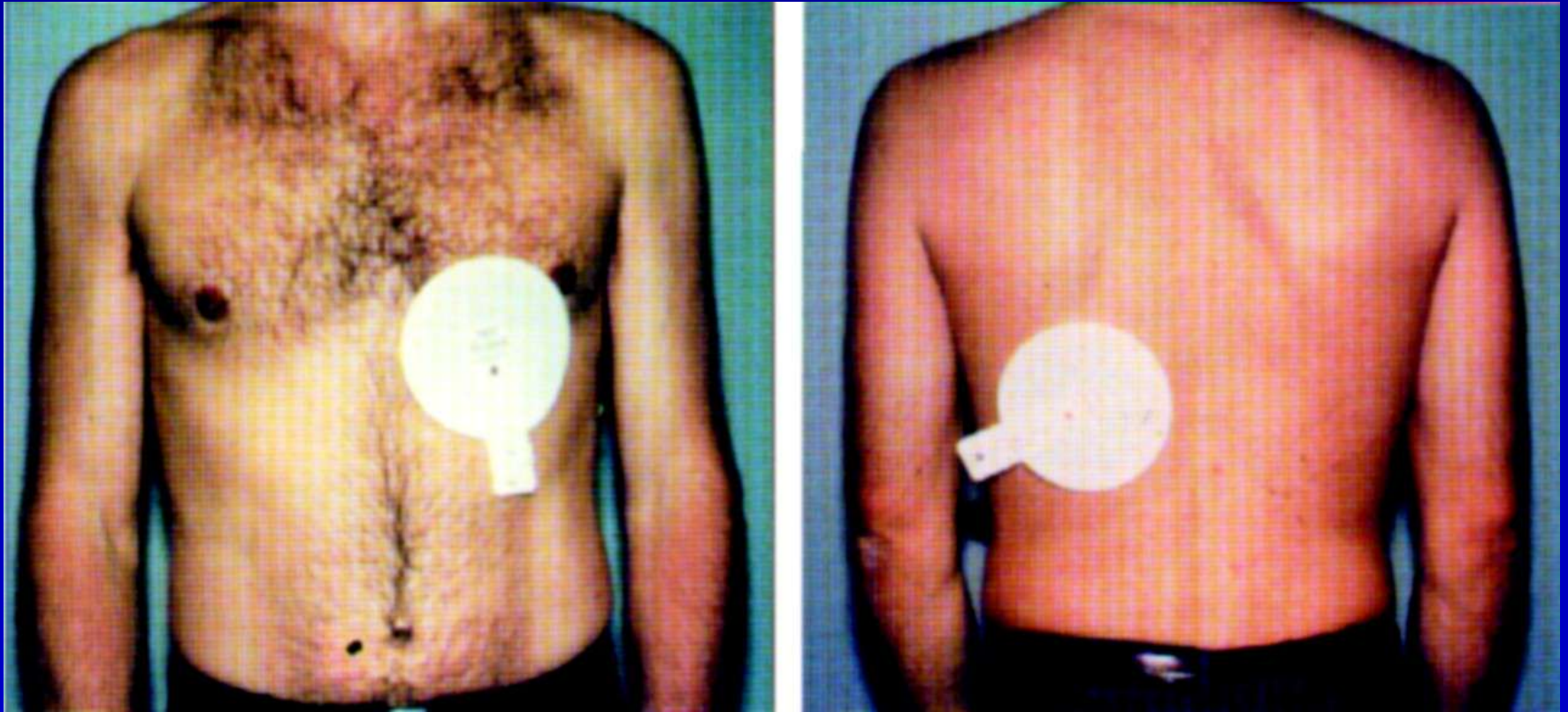
- Transcutaneous Class I:
 - Mobitz I or II second degree AV block, any MI type
 - Hemiblock with either first degree and anterior MI or Mobitz I or II and any MI type
 - Old BBB with either first degree or Mobitz I or II and any MI type
 - New BBB or bifascicular block (RBB and hemiblock) with nl PR or first degree or Mobitz I and any MI type (TV for Mobitz II)
- Transvenous Class I: Any MI and alternating BBB, and Mobitz II with new BBB or bifascicular block

Defibrillator with pacemaker function and transcutaneous pacemaker pads



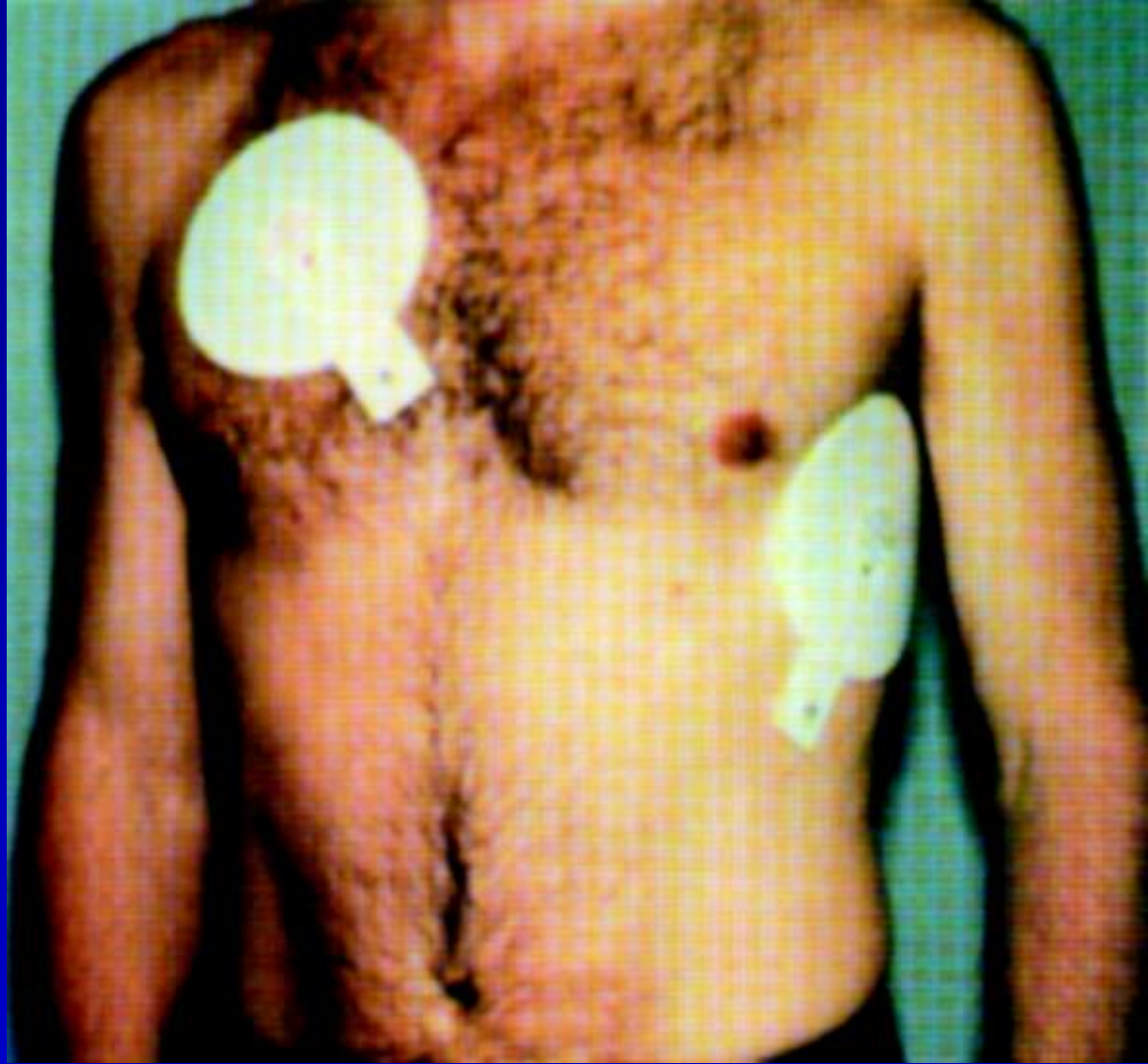Gammage, M. D Heart 2000;83:715-720

Typical anteroposterior positioning of transcutaneous pacing electrodes



Gammage, M. D Heart 2000;83:715-720

The anterolateral
position for
transcutaneous
pacing electrodes



Gammage, M. D Heart 2000;83:715-720

Temporary Transvenous Pacemaker Insertion

- Call the cardiology fellow
- Emergent:

Temporary Pacemaker Insertion

Pacemaker generator.

(A) Pacing indicator.

(B) Sensing indicator.

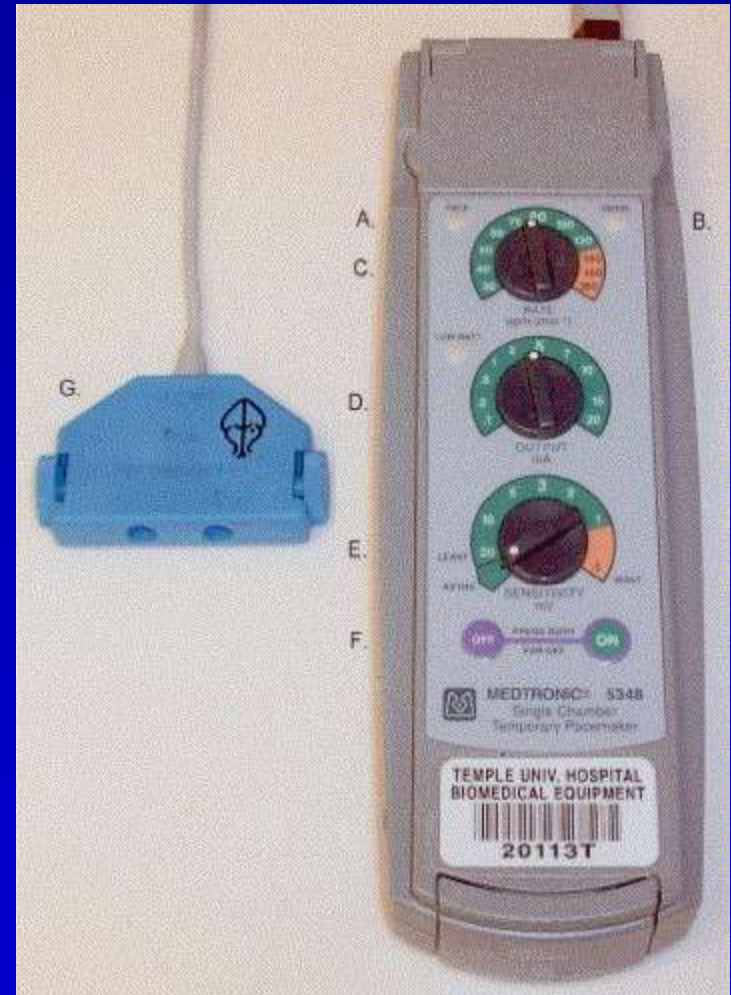
(C) Rate control knob.

(D) Pacing output control knob.

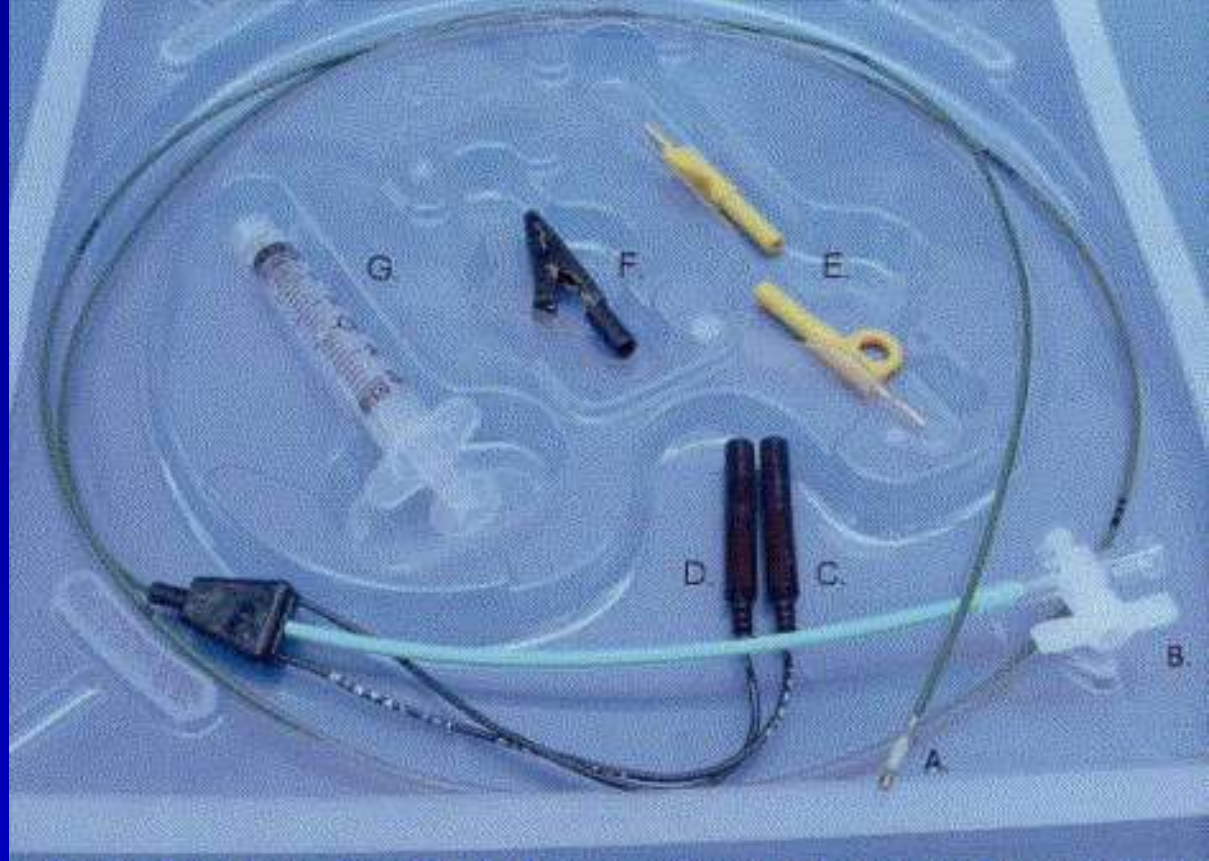
(E) Sensitivity control knob.

(F) On/off control.

(G) Adaptor for connection to pacing electrode



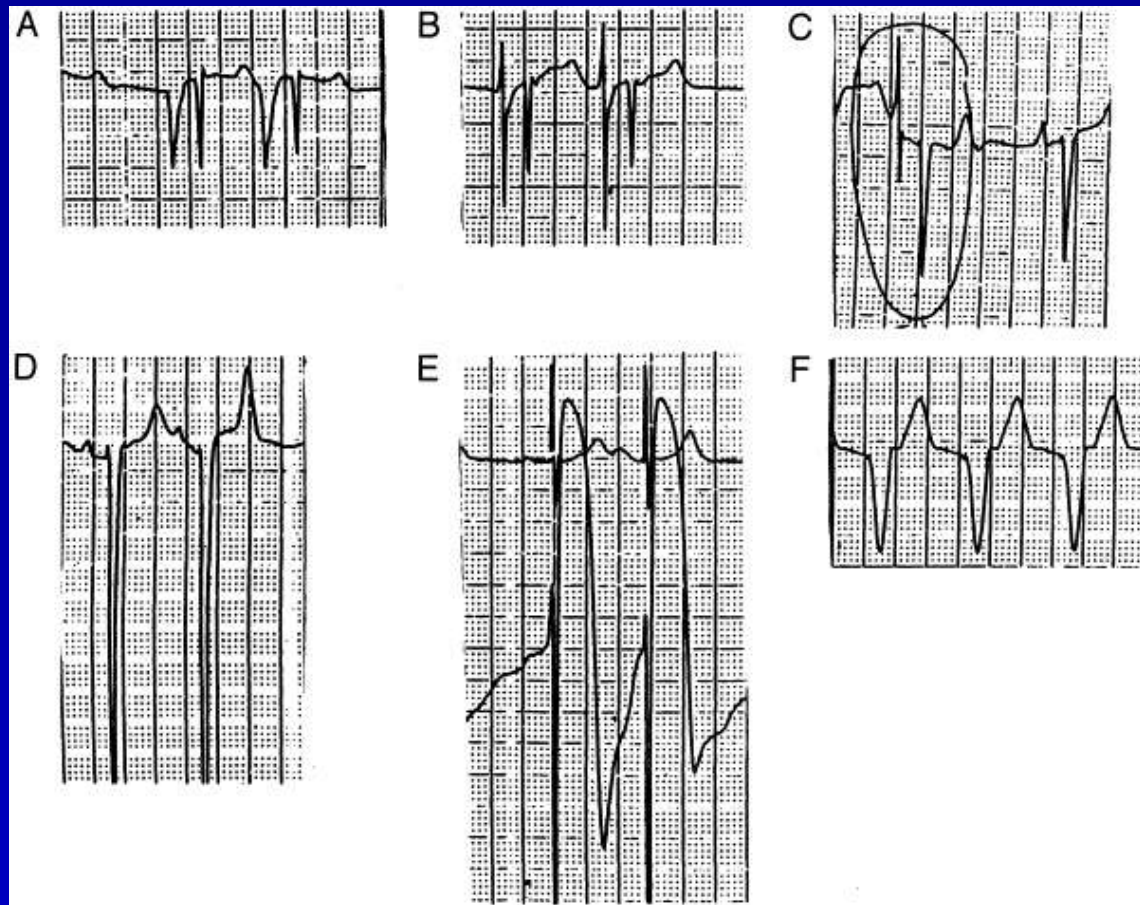
Temporary Pacemaker Insertion



Transvenous pacemaker catheter. (A) Catheter tip with balloon; (B) balloon inflation port; (C) negative electrode; (D) positive electrode; (E) adapters to attach electrodes to external pacing generator; (F) alligator clip to attach negative electrode to ECG V lead; and (G) syringe for balloon inflation.

Temporary Pacemaker Insertion

ECG recordings from within the right heart during transvenous pacemaker placement.

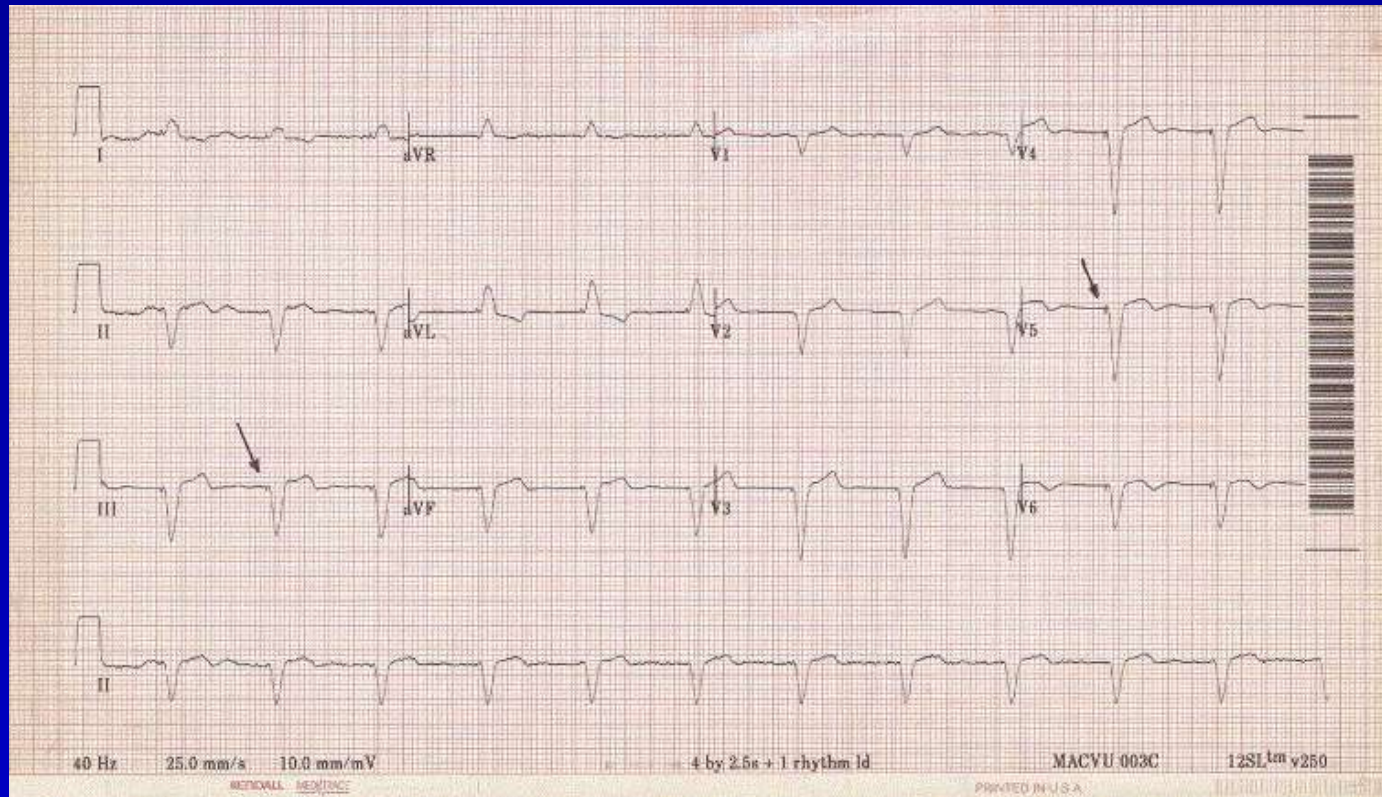


(A) High right atrium; (B) mid-to-low right atrium; (C) low right atrium-to-tricuspid annulus; (D) right ventricle; (E) contact with right ventricular endocardium; and (F) surface ECG demonstrating pacemaker capture. Reprinted with permission from (2): Wald DA. Therapeutic

procedures in the emergency department patient with acute myocardial infarction. Emerg Med Clin North Am 2001;19:451-67.

Harrigan RA et al. J Emerg Med. 2007;32:105.

Temporary Pacemaker Insertion



Note the characteristic wide-QRS complexes preceded by narrow pacemaker spikes (arrows). V1–V3 resemble a classic LBBB, yet V4–V6 differ in that the QRS complexes maintain a principally negative deflection. Also note the leftward (superior) frontal plane QRS axis deviation

Harrigan RA et al. J Emerg Med. 2007;32:105.

Temporary Pacemaker Thresholds

- Pacing threshold = minimum current for capture.
- Start with high level of current output and pacing rate at least 10 beats/min above the native rate.
- Slowly reduce output until capture is lost.
- Repeat several times to verify threshold value.
- Set current to roughly 2–2.5 times the threshold.
- Ideal pacing threshold is < 1 mA, so the pacing output is usually set to no more than 2–3 mA;
- Reposition electrode if threshold is above 5–6 mA

Few Temporary Pacer Tips

- Hemodynamic compromise or syncope are the principal indications
- Prefer right side of neck (save left for permanent pacing site)
- Set energy at 3x threshold, hopefully threshold is 0.1 mA
- Check at least daily
- Paced 12-lead ECG should be LBBB and LAD
- Prevent migration and loss of capture
 - Use suture to attach electrode to cordis
 - Create a loop with the electrode to prevent its being pulled out

Sinus Bradycardia Mechanisms

- Vagal tone
- Decreased sympathetic tone
- Medications
- Anatomic SA node changes

Pathologic Sinus Bradycardia Causes

- Eye surgery
- Coronary arteriography
- Meningitis
- Intracranial tumors
- Increased intracranial pressure
- Cervical and mediastinal tumors
- Severe hypoxia
- Myxedema
- Hypothermia
- Fibrodegenerative changes
- Convalescence from some infections,
- Gram-negative sepsis
- Mental depression
- Vomiting, vasovagal syncope

Pathologic Sinus Bradycardia

Medication Causes

- Parasympathomimetic drugs
- Lithium
- Amiodarone
- Beta-blockers
- Clonidine
- Propafenone (sotalol)
- Calcium antagonists
- Conjunctival beta blockers for glaucoma

Relationship between AV block and AV dissociation



AV Block

AV Dissociation

AV Block: atrial rate is faster

AV Dissociation: ventricular rate is faster



AV Dissociation

AV Block

AV Block: subset of AV Dissociation where AV Node fails to conduct

AV Dissociation: Any condition where PR interval is not normal and constant

AV Block: Outline

- Review of anatomy of conduction system
- Description of types of AV block
- Other considerations
 - Distinguishing from AV dissociation without block
 - Information from the QRS
 - Escape mechanism
 - Morphologic information: Injury, Electrolyte
 - Effects on the Atrium
 - Ventriculophasic sinus arrhythmia

AV Node Anatomy

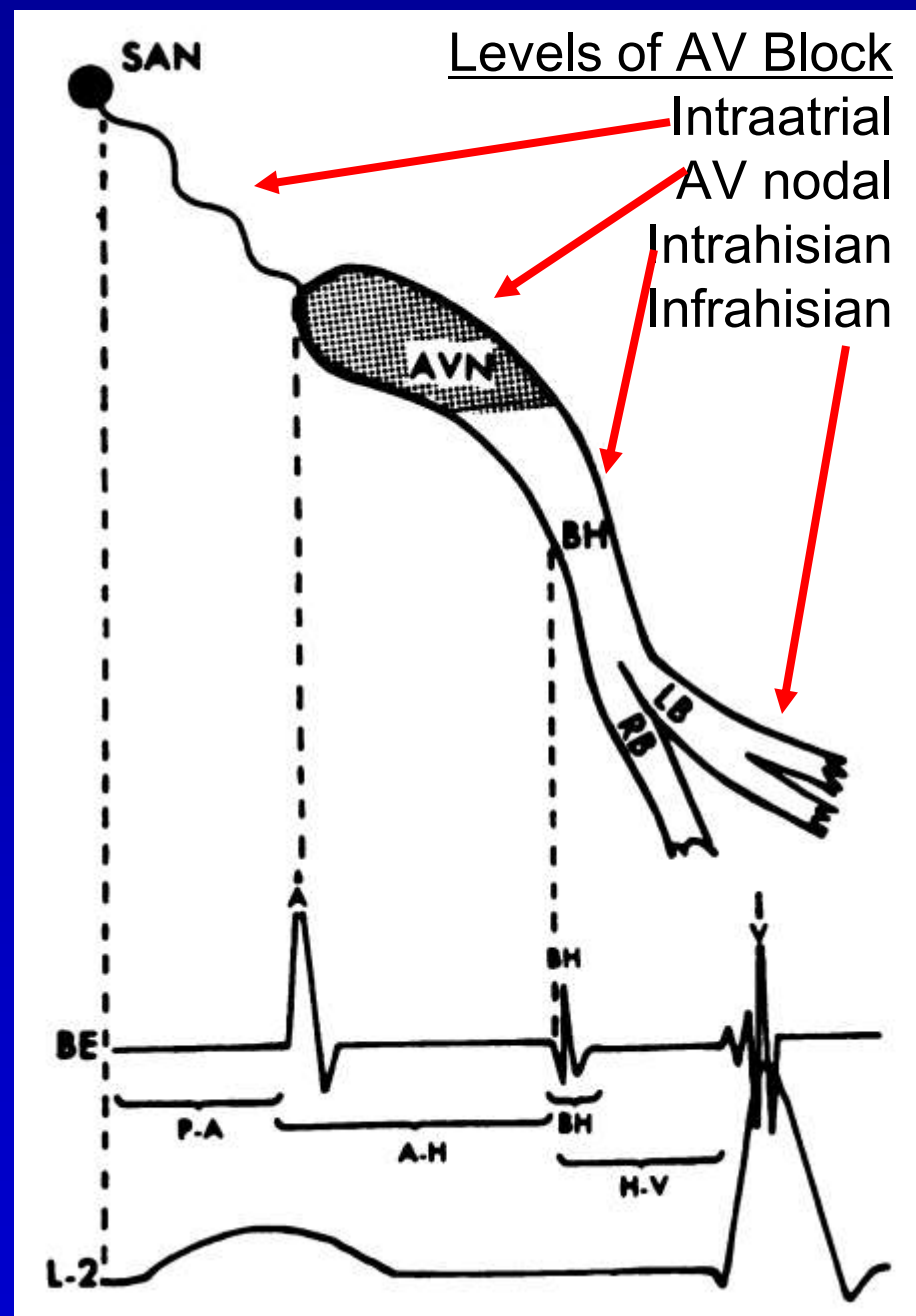
Intervals

PR	0.120-0.200 sec
PA (HRA-LRA)	0.025-0.045 sec
AH (LRA-HB)	0.050-0.130 sec
BH (intraHis)	0.015-0.020 sec
HV	0.035-0.055 sec
Sum	0.110-0.230 sec

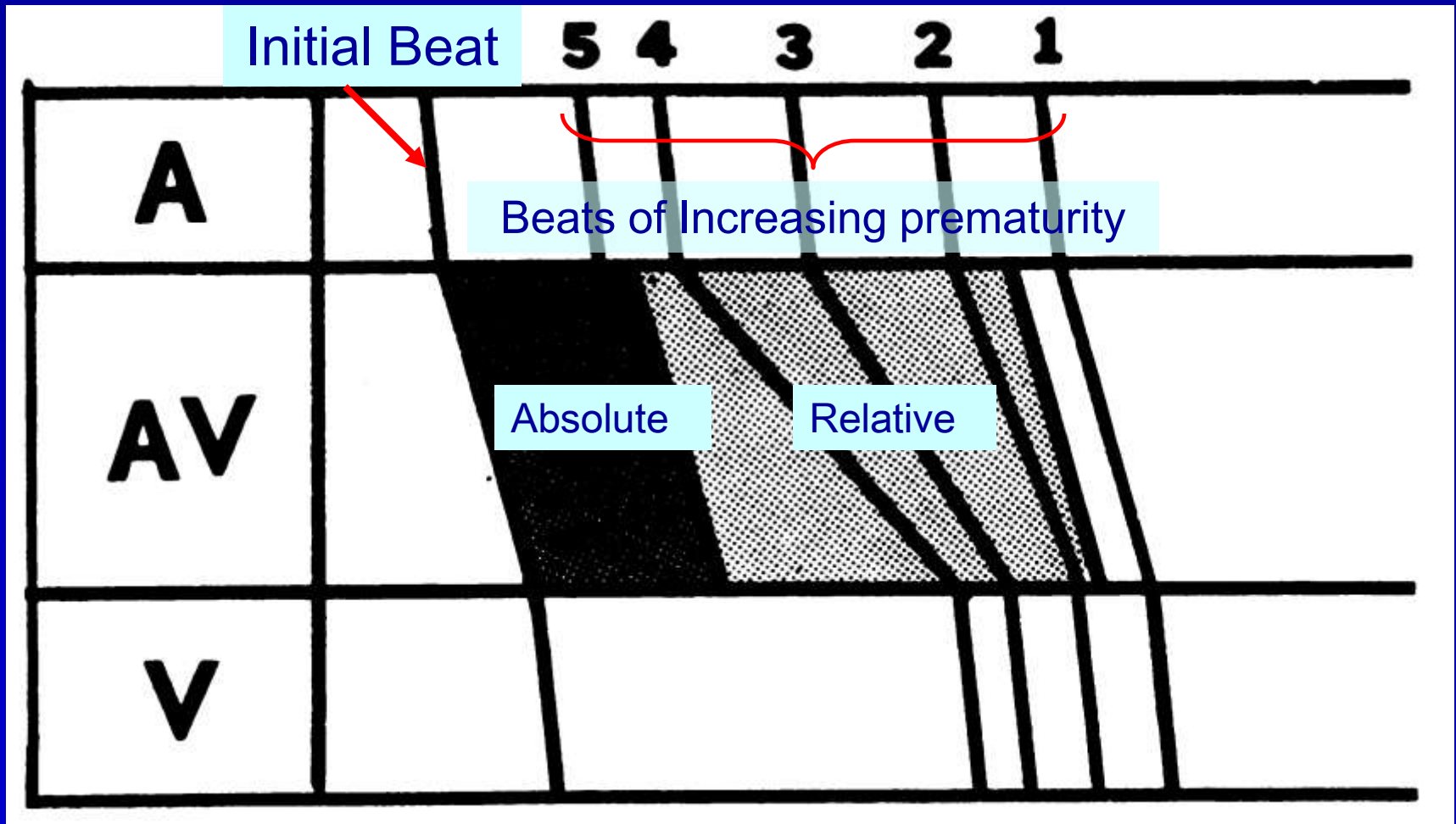
Conduction Velocity

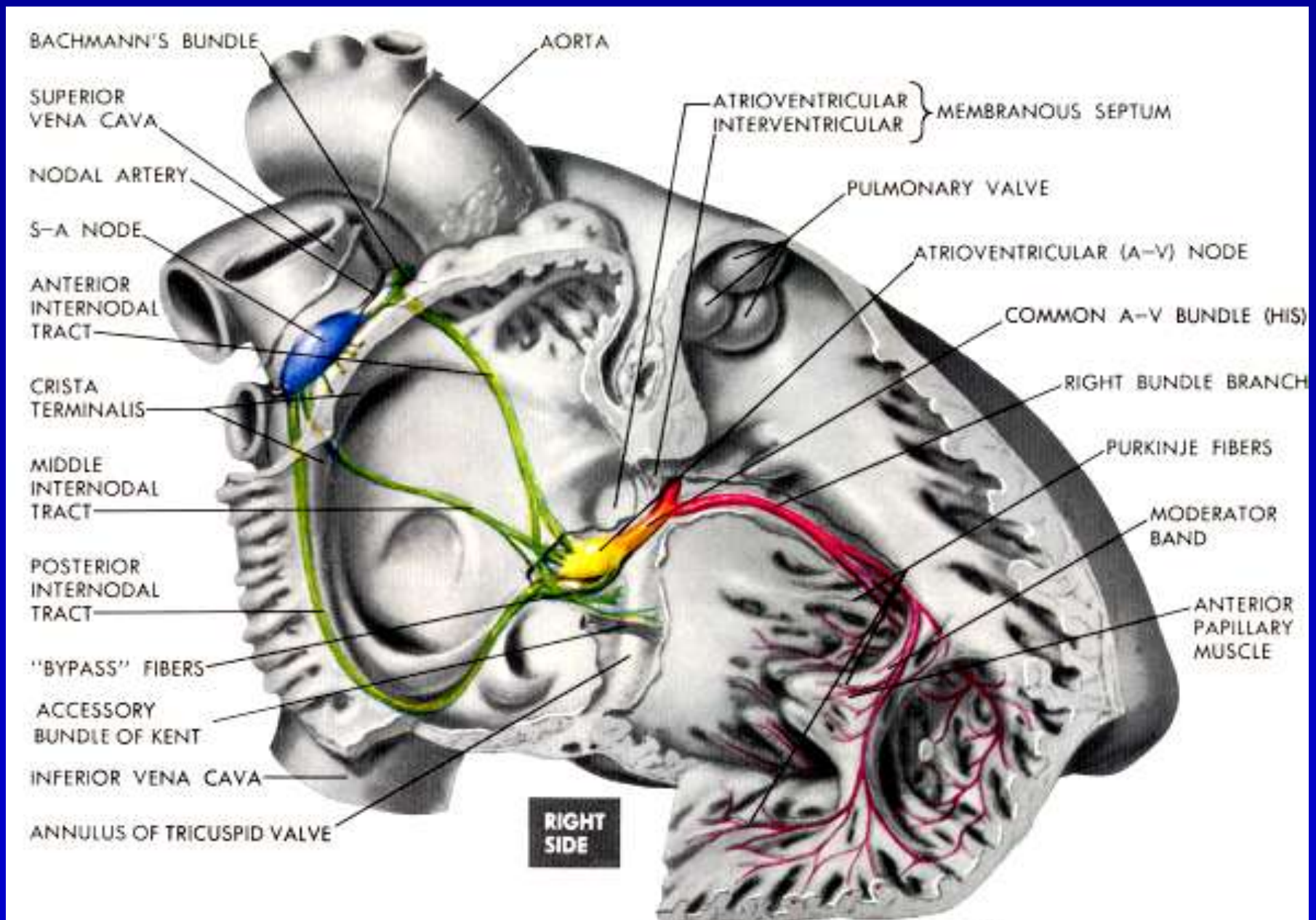
SA Node	<0.05 m/s
Atrial myocardium	0.3-0.4 m/s
AV Node	0.1 m/s
His-Purkinje system	2.0-3.0 m/s
Ventricular myocardium	0.3-0.4 m/s

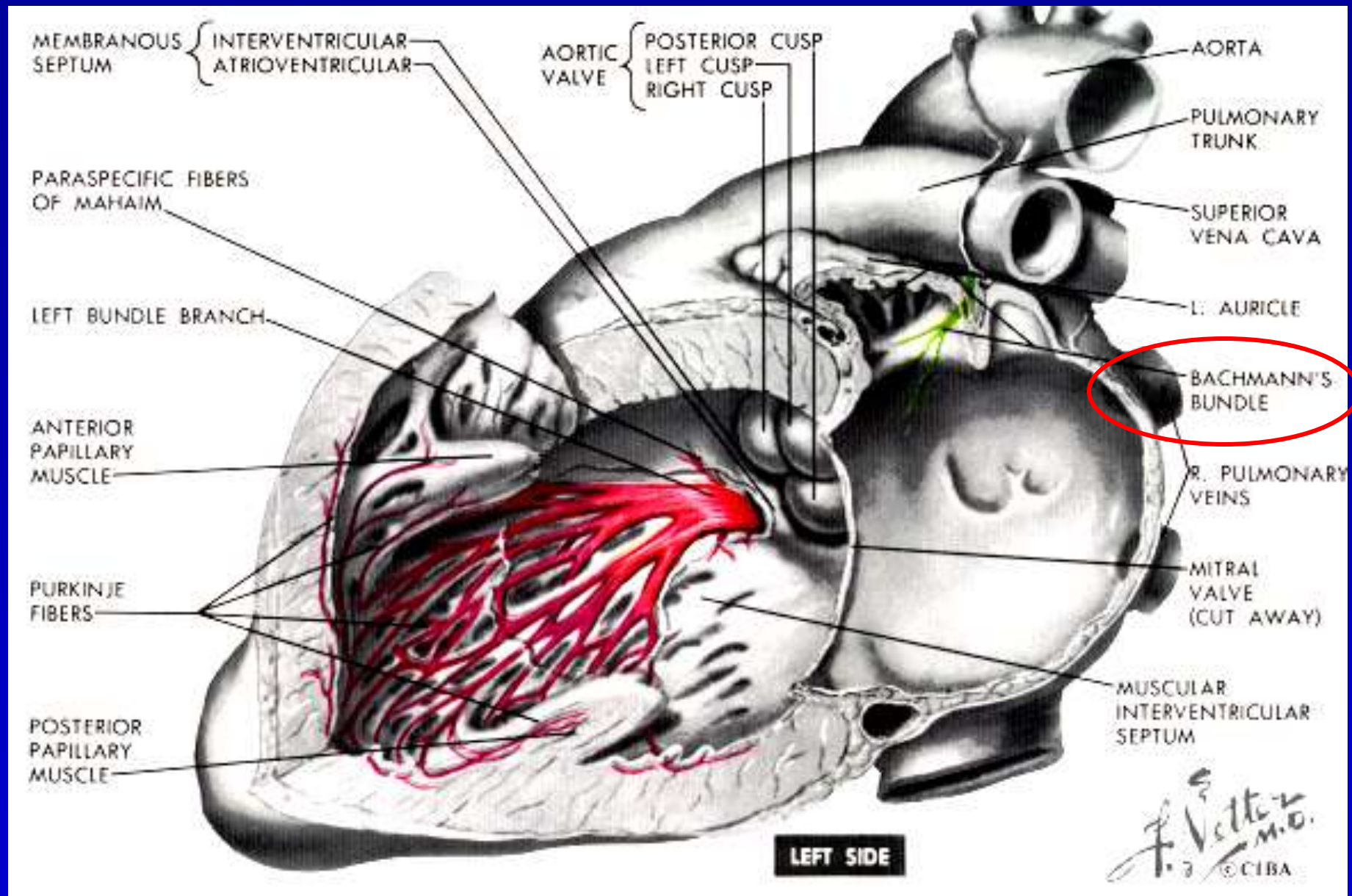
(Braunwald, 2005, p.663)



AV Node Property: Decremental Conduction



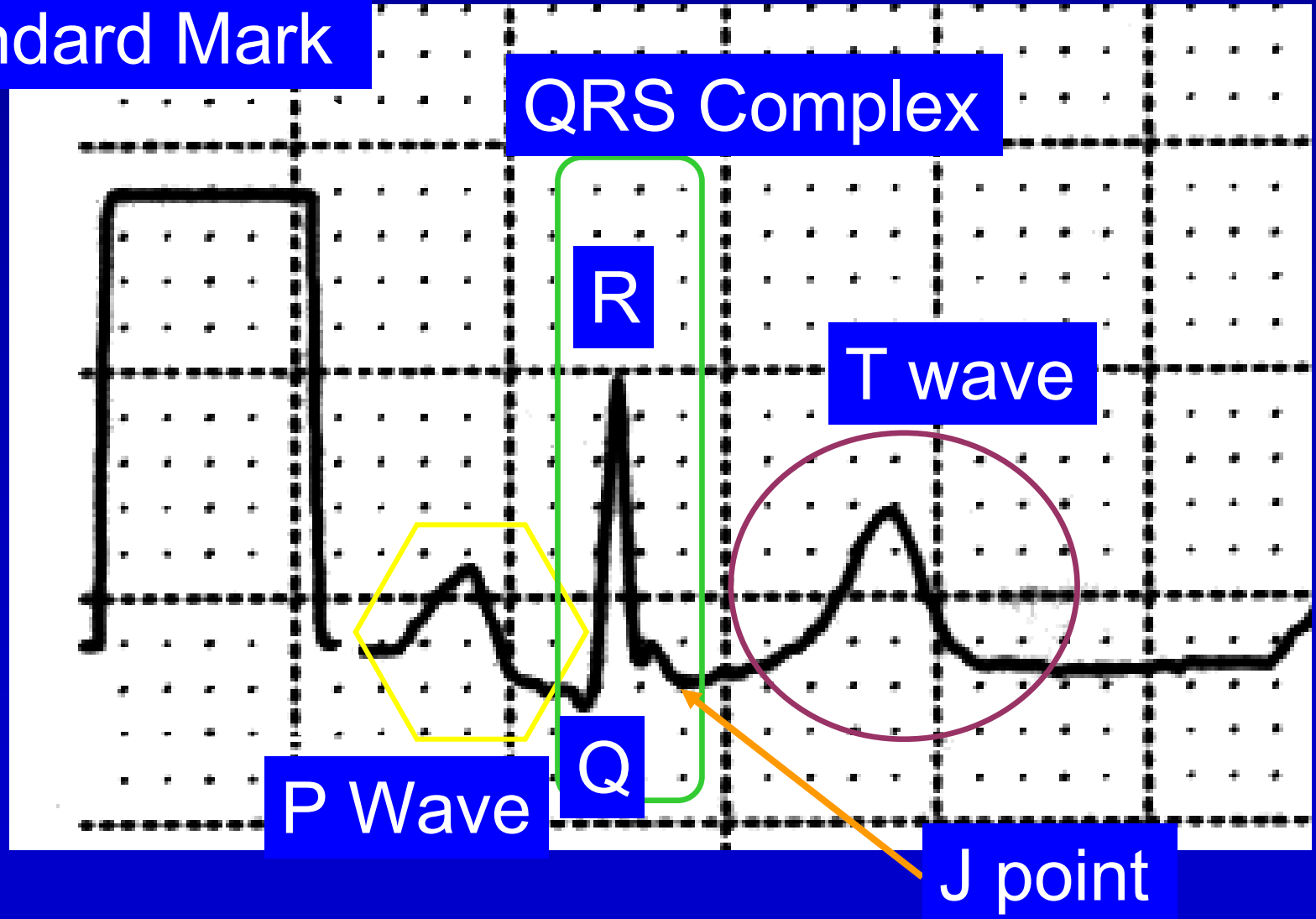




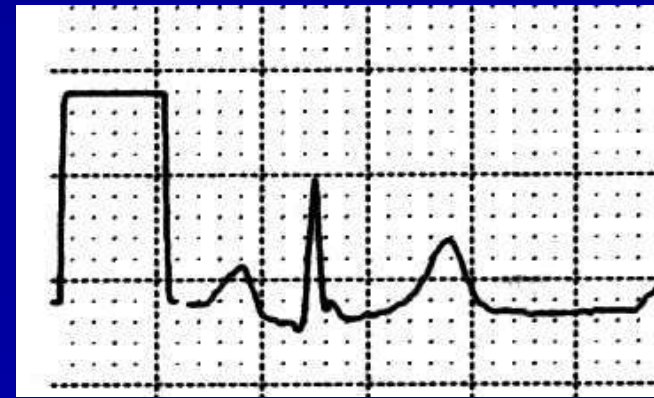From Netter's Atlas, Volume 5, The Heart 1978

ECG Waves in Lead II

Standard Mark

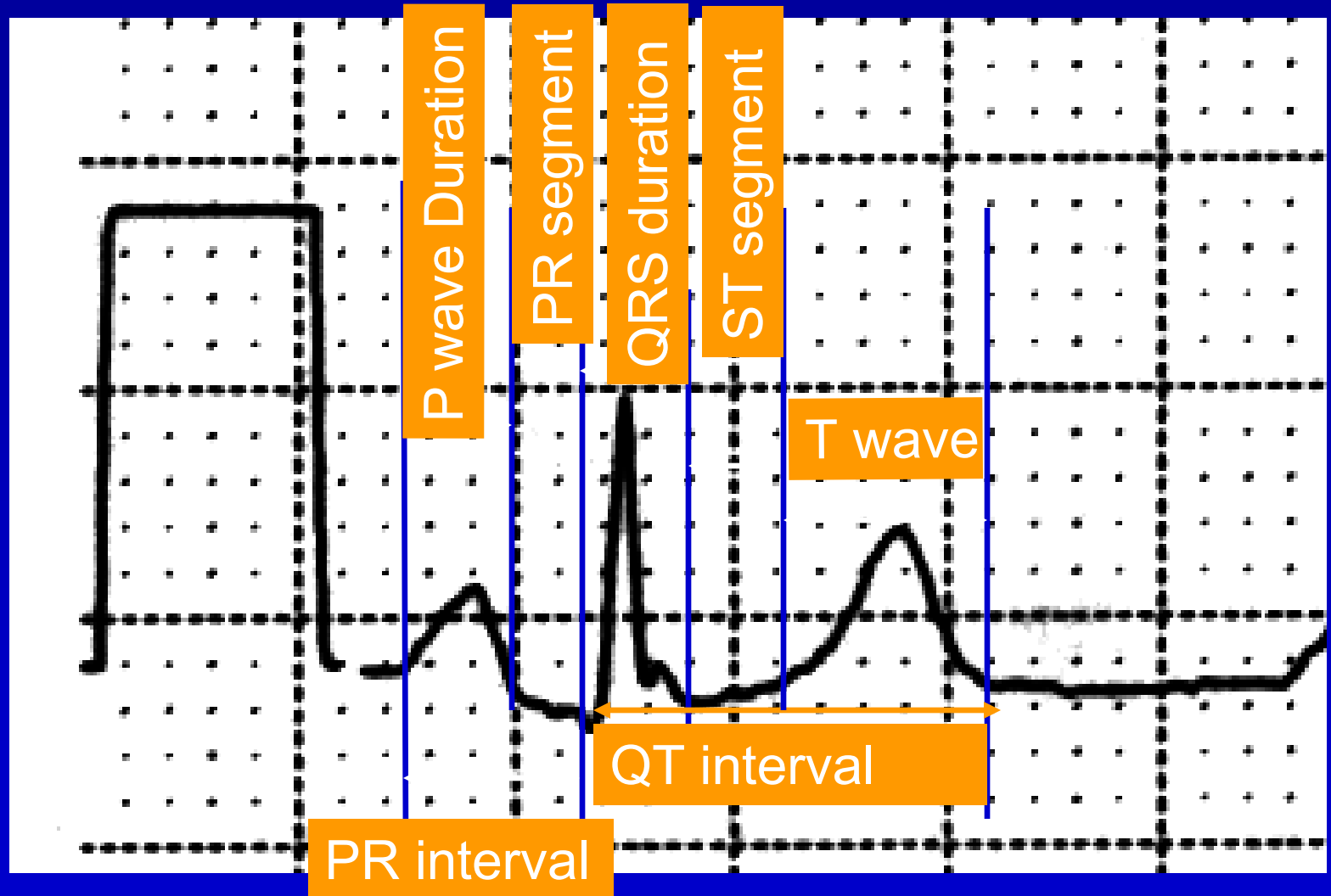


Intervals in the ECG



- P duration - from beginning to end of P wave (0.06-0.10 sec)
- PR interval - from beginning of P to beginning of QRS (0.12-0.20 sec)
- QRS duration - from beginning of QRS to its end (0.06-0.10 sec)
- QT interval - from beginning of QRS to end of T wave (varies with heart rate)

Intervals on the ECG



History in AV Block

- Noted the AV delay
- Described “partial block”
- Described “complete block”



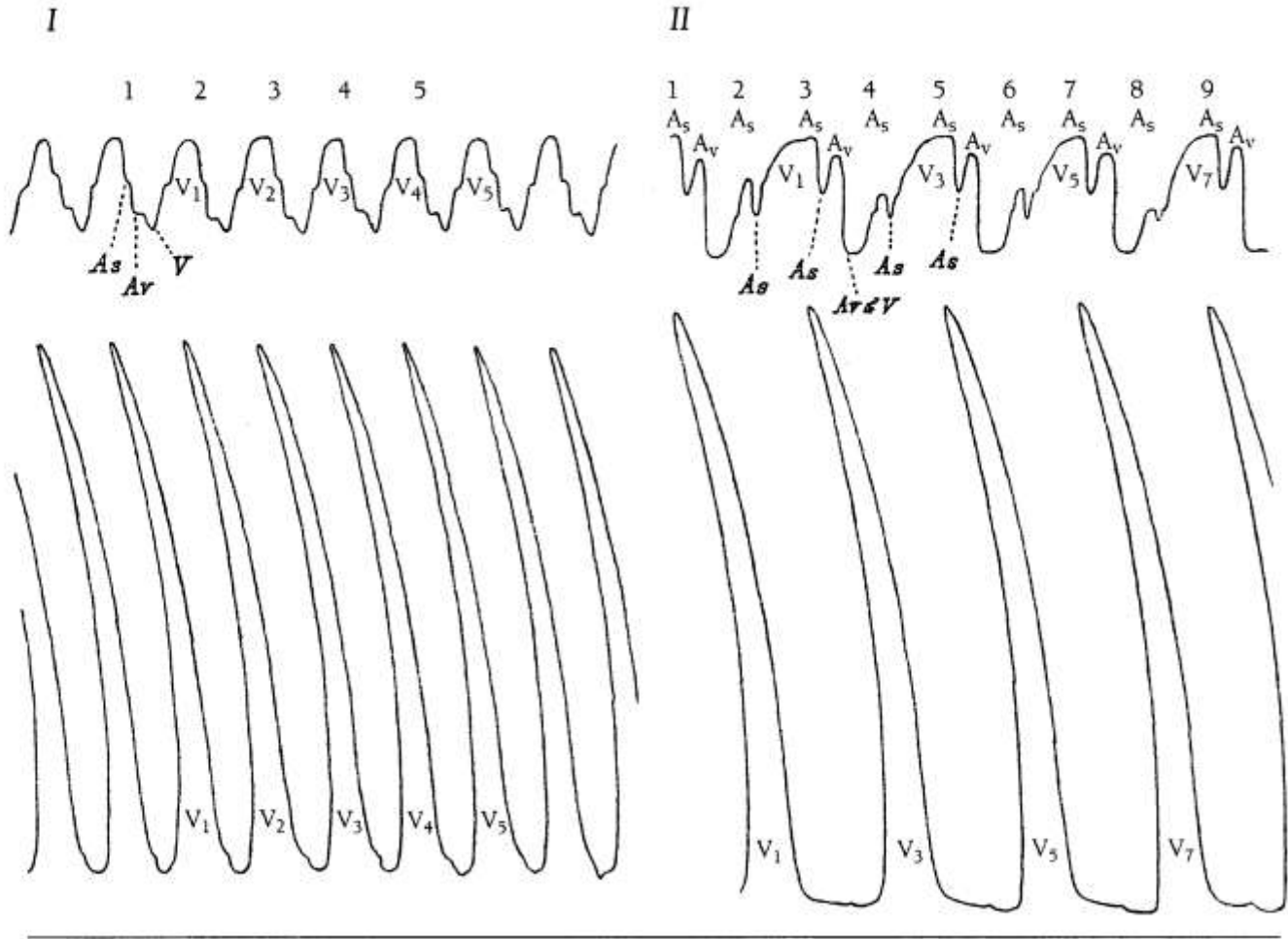
Walter H. Gaskill (1847-1914)
JACC 2002; 39:1576

History in AV Block

1882

atrial tracing

ventricular tracing



- Panel I – 1:1 conduction, rate 7.5 bpm
- Panel II – 2:1 conduction, deep cut in RA

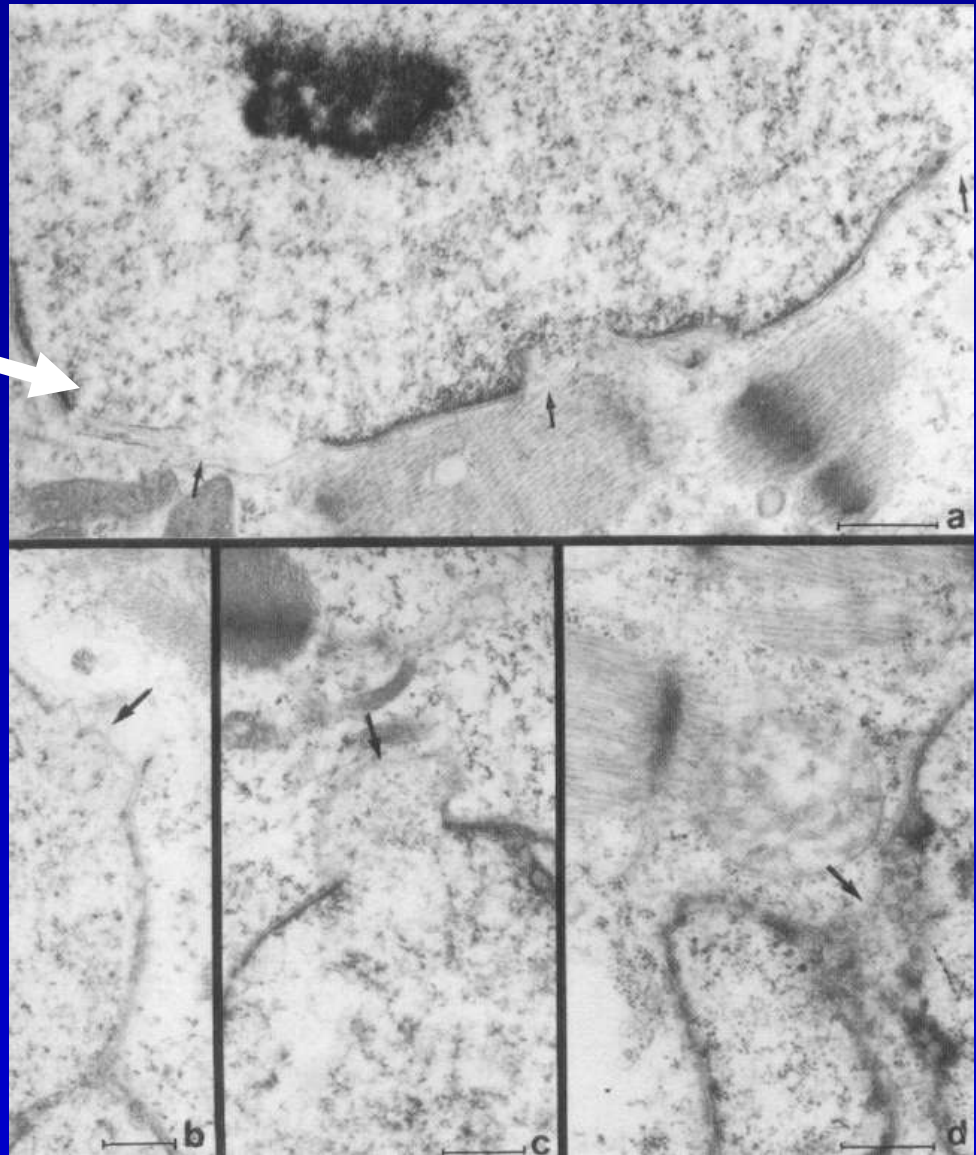
Walter H. Gaskill (1847-1914)
JACC 2002; 39:1576

Causes of AV Block

- Normal variant; Congenital (isolated, corrected transposition)
- Iatrogenic
 - vagal, negative chronotropic agents
 - Surgery (VSD, AVR), septal ablation, radiofreq
- Coronary artery disease (acute ant or inf MI)
- Valve disease – calcific aortic stenosis (?Lev)
- Degenerative conduction system disease (Lenegre)
- Cardiomyopathy – sarcoid, primary dilated, amyloid, hemochromatosis, progressive muscular dystrophy,
- Inflammation/infection/metabolic – acute myocarditis, Chagas cardiomyopathy, Lyme disease; lupus, dermatomyositis, scleroderma, Reiter's syndrome, Marfan's syndrome, rheumatoid heart disease, ankylosing spondylitis; hyperkalemia or mag
- Hereditary with DCM
 - Autosomal dominant DCM lamin A/C defect
 - Emerin defects also manifest AV conduction disease
- Isolated CHB in neonate or fetus is ominous, highly associated with anti-Ro and anti La, and with 6% and 43% mortality, respectively; in children, antibody association was 5% and mortality was 0

OSA

- Major constituents of the nuclear lamina, the proteinaceous meshwork underlying the inner nuclear membrane – defects associated with nuclear membrane damage
- Linked to 4 diseases (42 reported mutations)
 - DCM with conduction system dz or variable myopathy
 - Limb girdle muscular dystrophy
 - Autosomal dominant variant of Emery-Dreifuss muscular dystrophy
 - Autosomal dominant partial lipodystrophy



Lamins A and C

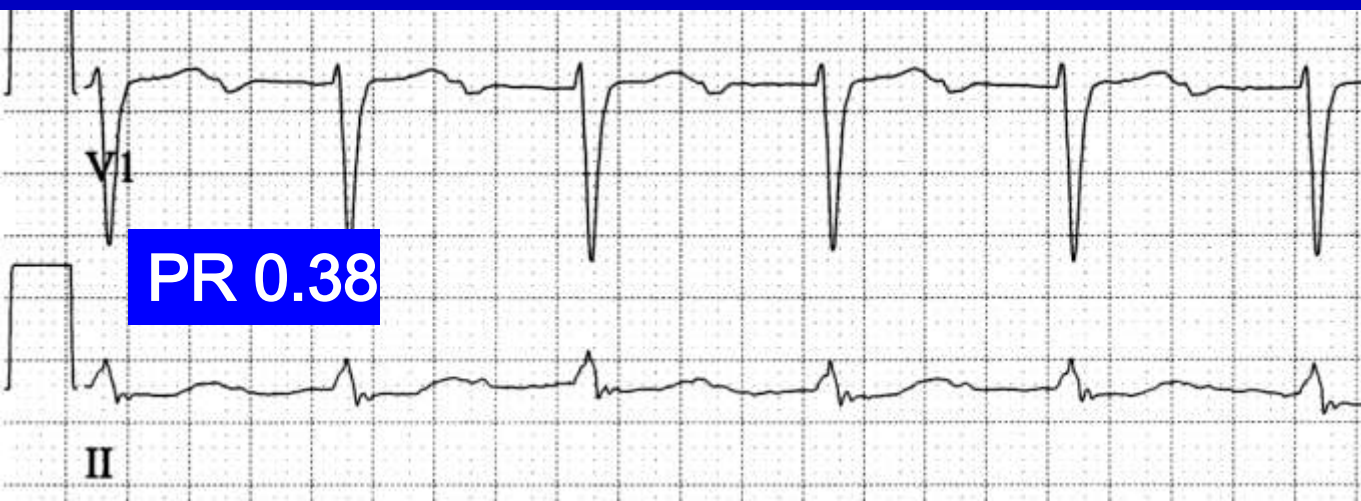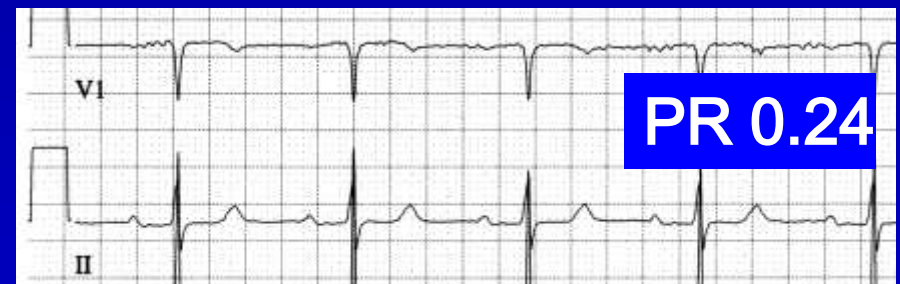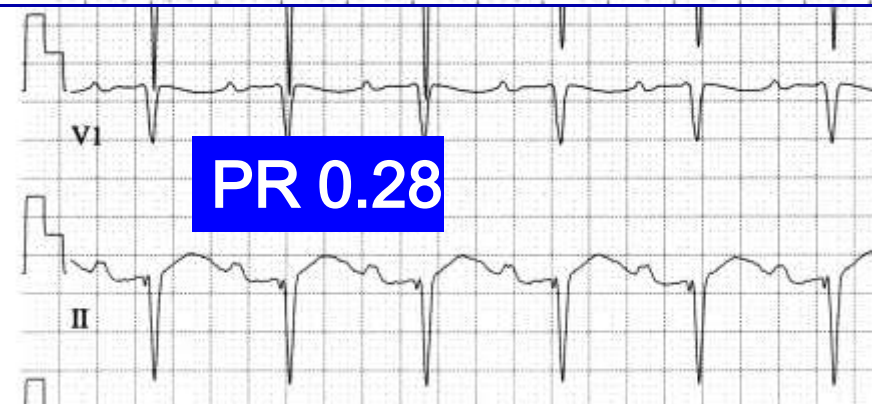
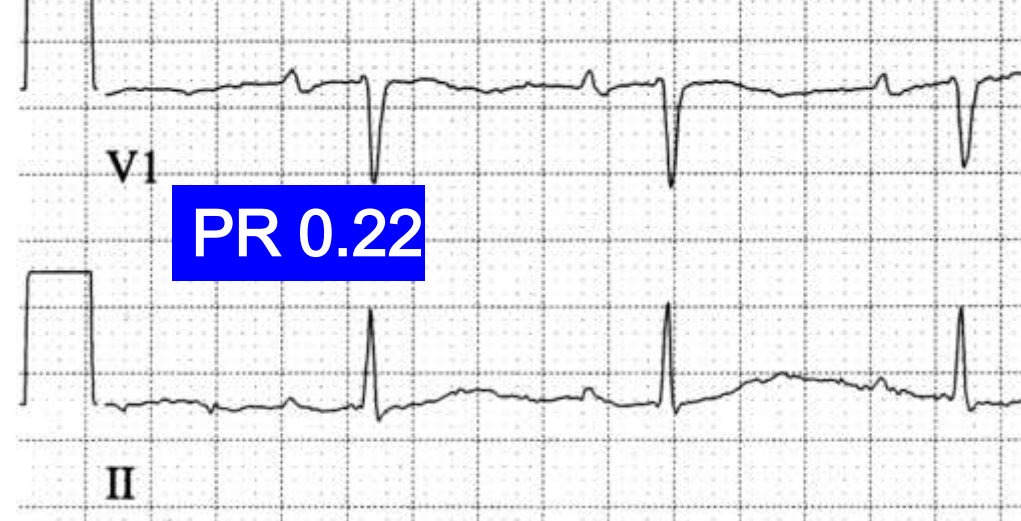Steps in Arrhythmia Analysis

- Find all the QRS's and check out their rate, regularity, uniformity and shape
- Find all the P's and check out their rate, regularity, uniformity and shape
- Deduce the origin of the P wave from the shape
- Deduce the relationship of the P and QRS by the PR interval characteristics and P wave shape
- Determine the cause of each wave using known electrophysiologic principles (automaticity, triggered activity, reentry, refractoriness, aberrancy)

Degrees of AV Block

<u>Degree</u>	<u>Which Conduct</u>	<u>PR interval</u>	<u>RR interval</u>
First	All	Constant and long	Regular
Wenckebach (Mobitz I)	Some	Variable, pattern	Grouped beats
2:1	Some	Constant	Regular
Mobitz II	Some	Constant	Irregular, multiples
Third (Complete)	None	Variable, random	Regular

First Degree AV Block

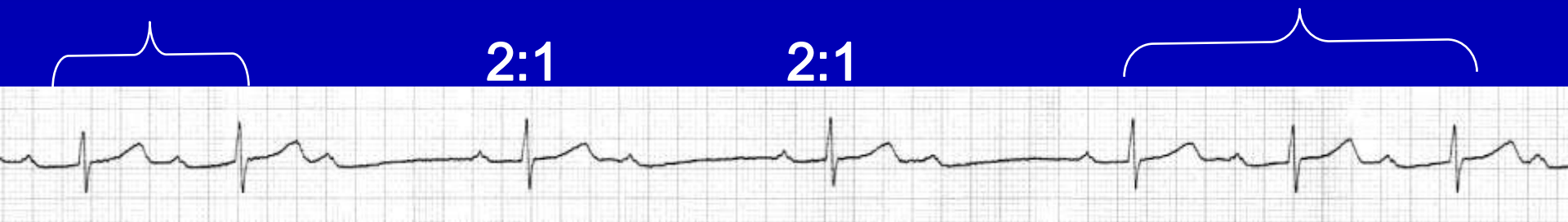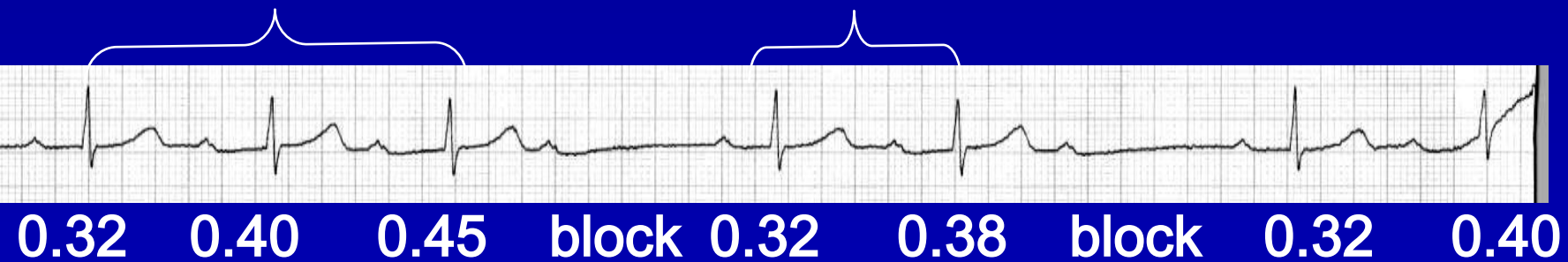


PR interval
Constant
and
Long

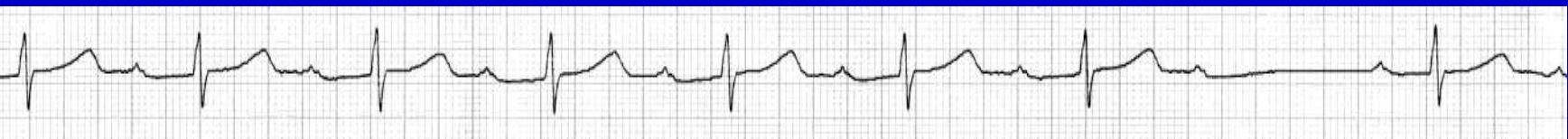Second Degree AV Block, Wenckebach (Mobitz I)

- Some beats don't conduct, so more P's than QRS's
- Progressive Prolongation of the PR interval for the conducted beats
 - increment of prolongation actually decreases
 - progressive shortening of the RR interval
- After pause is shortest PR interval
 - may be a junctional or ventricular escape beat

Second Degree AV Block, Wenckebach (Mobitz I)



Grouped beats

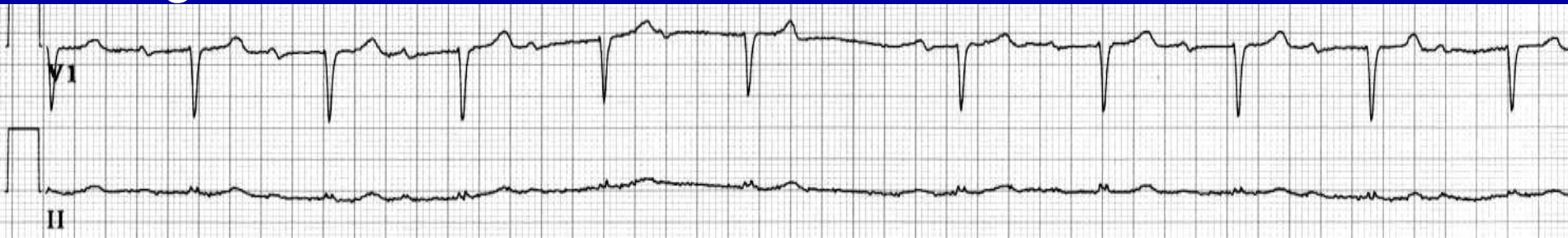

Wenckebach: The RR Decreases

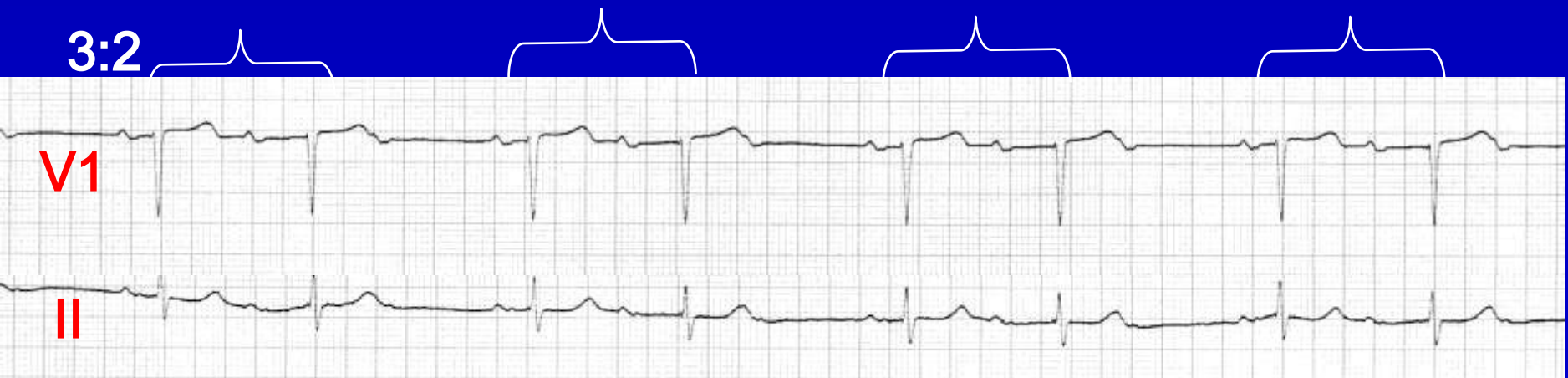A		80	80	80	80	80	80	80					
AV				22		22	12	34	5	39	3		22
V			140		92		85		83		140		

Second Degree AV Block, Wenckebach (Mobitz I)

Low grade block



3:2



Non-simultaneous

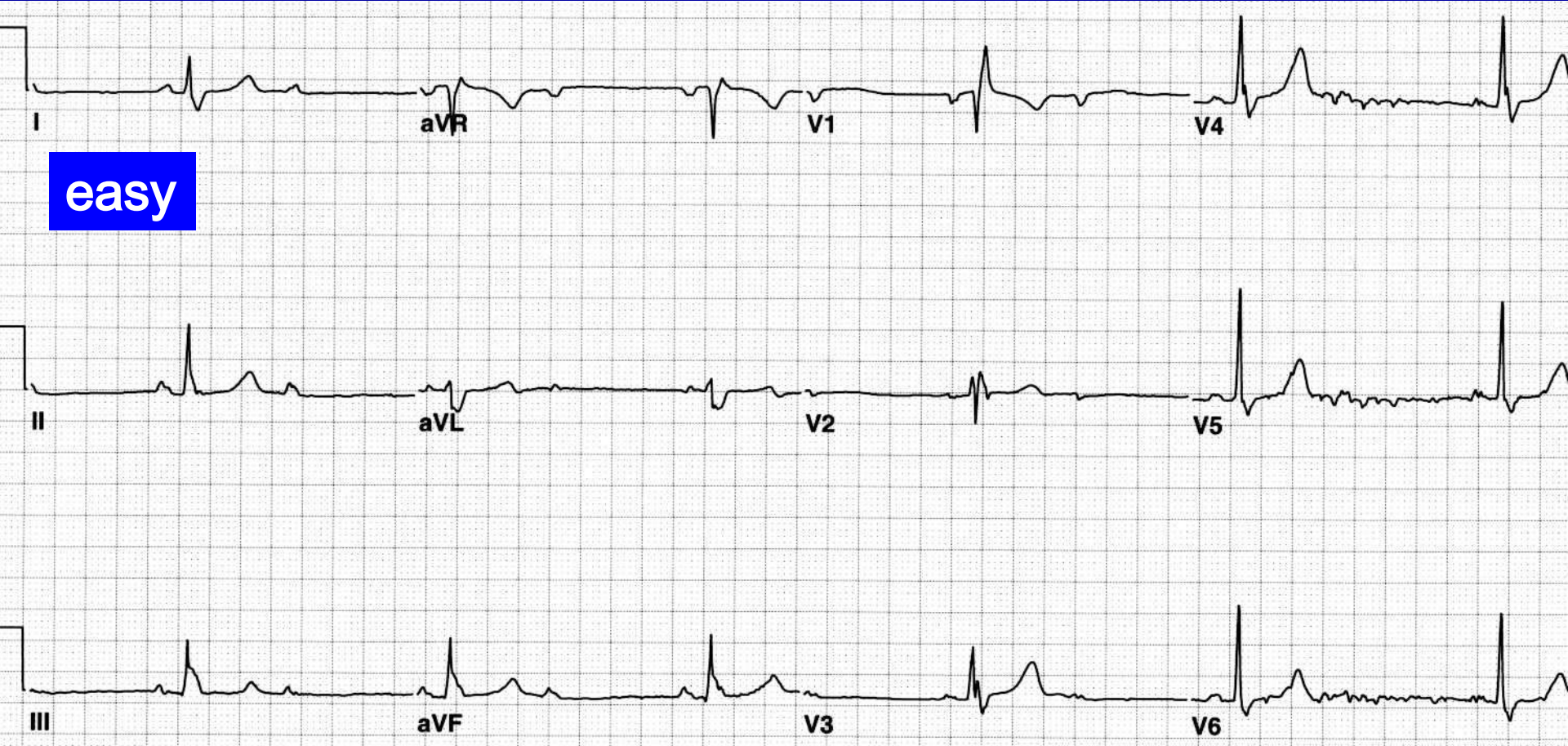
Wenckebach Details

- Block is usually in the AV node
- Blocked beat will have no His bundle potential
- If intrahisian, there will be split His potentials and blocked beat will have no second His potential (worsen with Atropine)
- If associated with BBB, still 75% are AV node, and only 25% infranodal
- Exceptions to the usual periodicity are more common than the rule

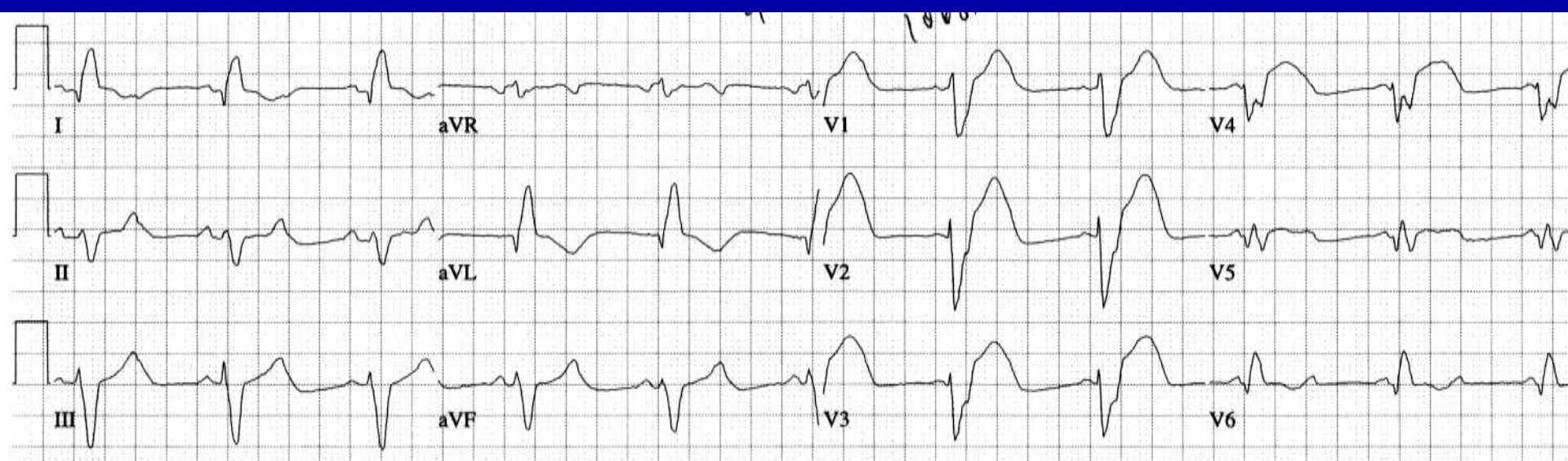
Second Degree AV block, 2:1

- Can be either mechanism of Wenckebach or mechanism of Mobitz II, can't tell
 - if QRS is wide, could be either
 - if QRS is narrow, usually is Wenckebach
- Can be tricky to diagnose, must find the nonconducted P waves (otherwise the mistaken diagnosis will be mere bradycardia)
- “It is advisable to be noncommittal as to the type of Mobitz block when dealing with 2:1 AV block”

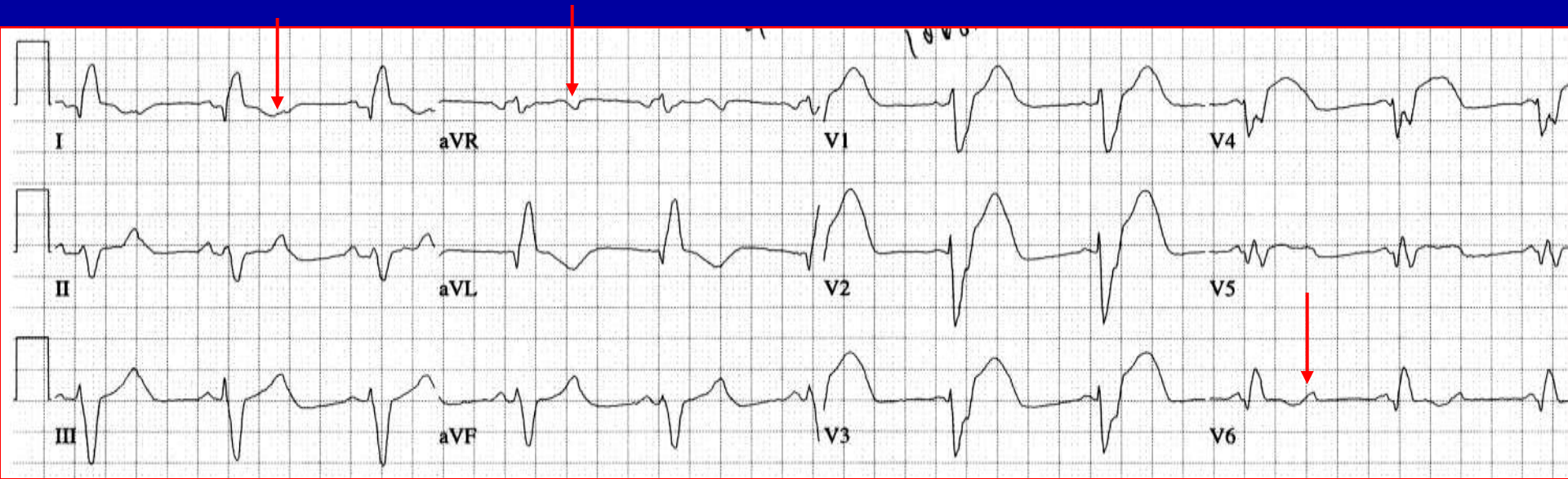
Second Degree AV block, 2:1



Second Degree AV block, 2:1



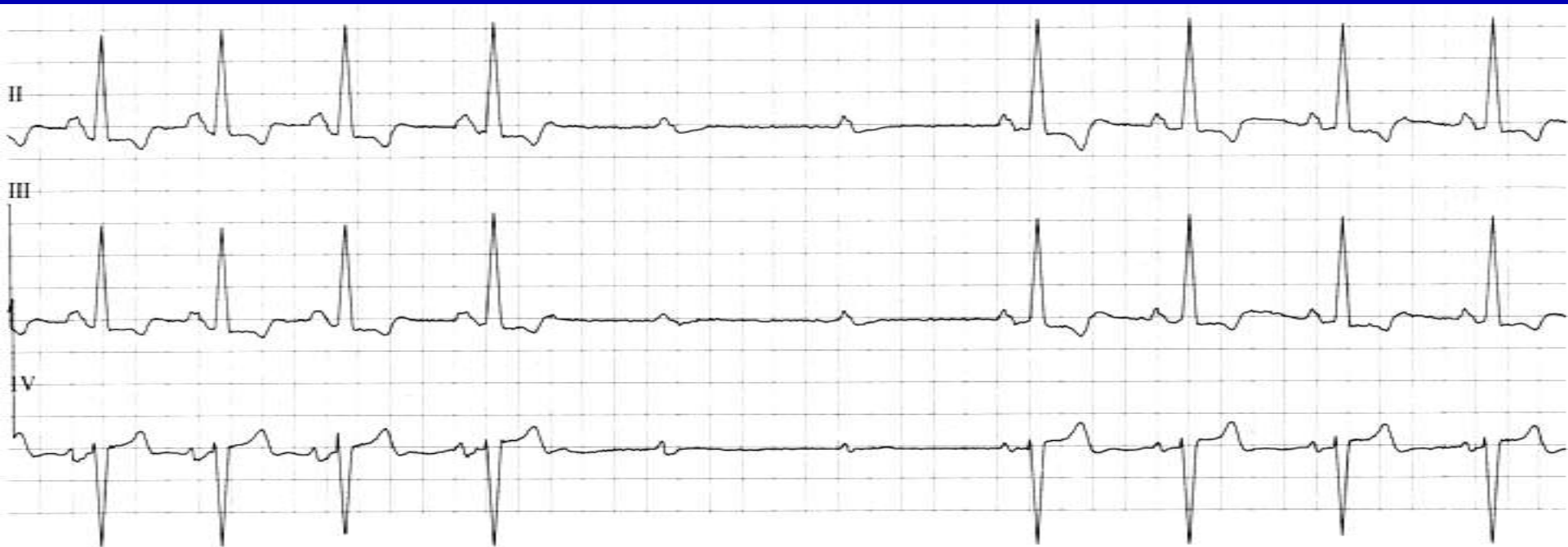Second Degree AV block, 2:1



- Not so easy... could misdiagnose as NSR rate 64.
- But actually is sinus tachycardia at rate of 128 (patient is likely sick) with 2:1 block.
- The extra P waves are best seen at the 3 red arrows, and are same shape and axis as the sinus P waves.
- Wide QRS indicates disease below the bundle of His.

Second-Degree AV Block, Mobitz II

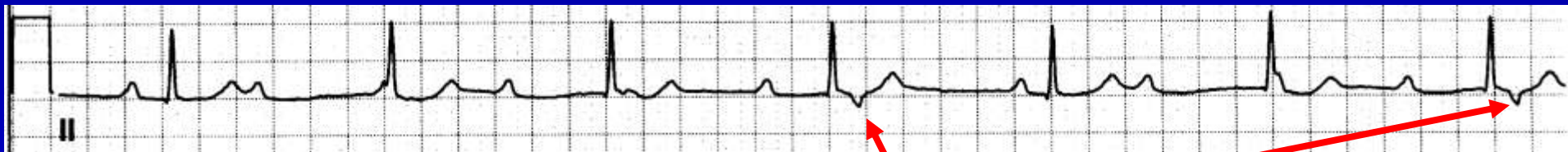- Intermittent blocked P waves
- PR interval constant for conducted beats
- Most are associated with BBB
- About 1/3 of patients with Mobitz II have block located in the His bundle, so QRS is narrow
- Rarely Mobitz II is due to block in the AV node



Advanced AV block

- Block is 3:1 or higher
- Sometimes only occasional ventricular captures are observed, sometimes more frequently
- One definition: 2 consecutive nonconducted sinus beats

Third Degree AV Block

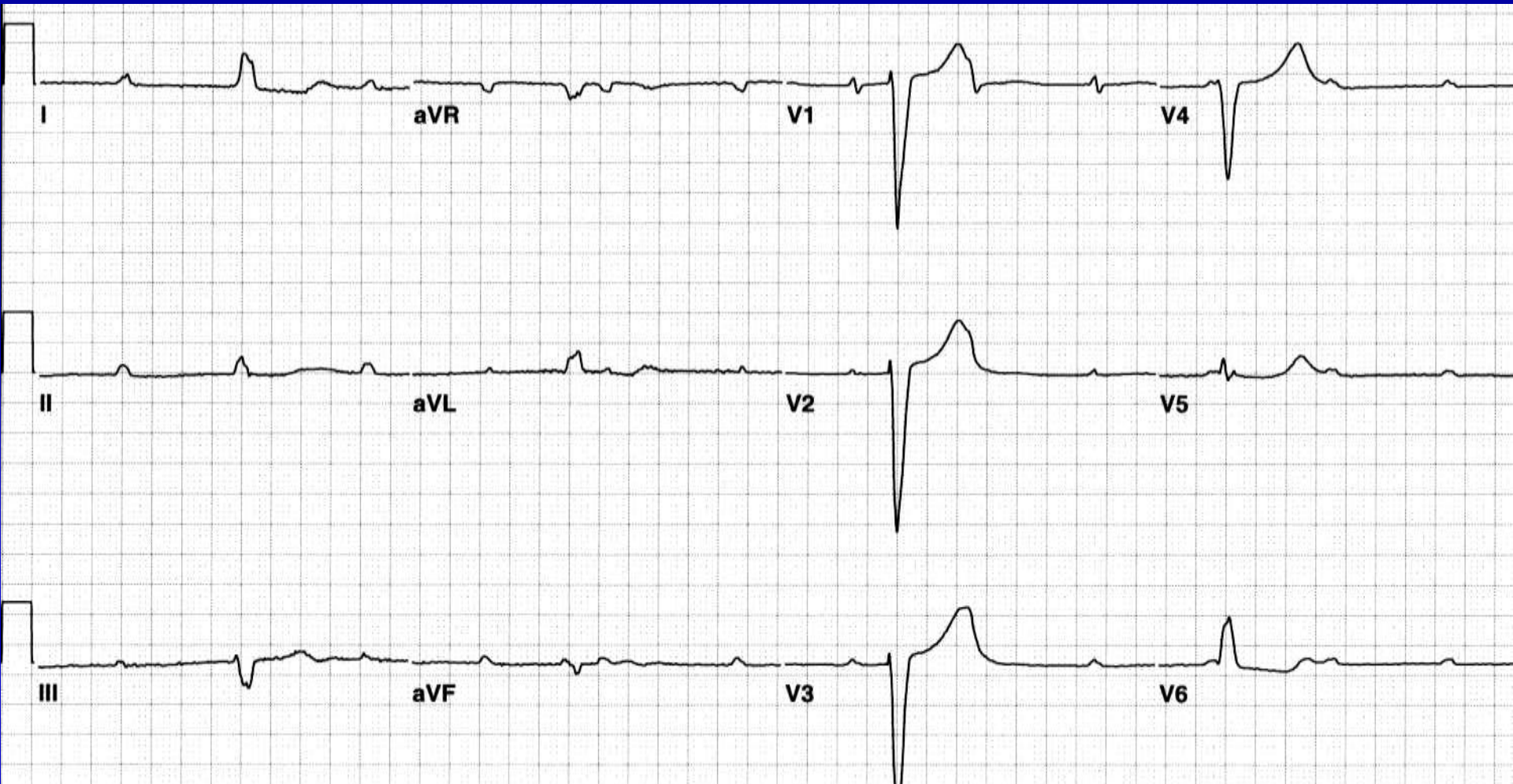


Retrograde conduction

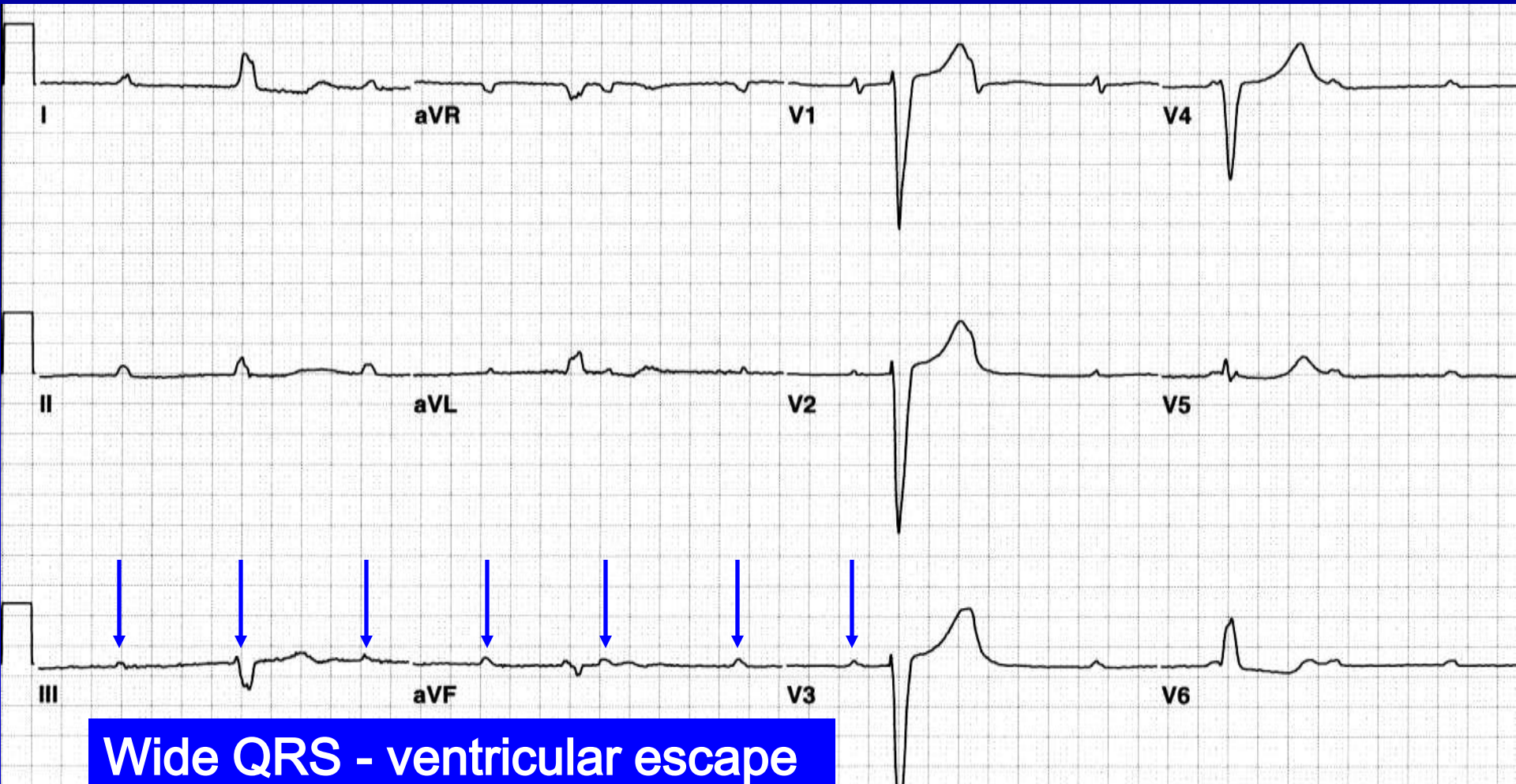
Third Degree AV block - 2

- Site of block: AV junction, His bundle, or bundle branches (either bilateral bundle branch, or trifascicular block)
- Adult acquired chronic: 50-60% are infrahisian and escape complexes are wide
- Acute block from drugs, infection or inferior MI: usually proximal to His bundle
- Anterior MI: usually distal to His bundle

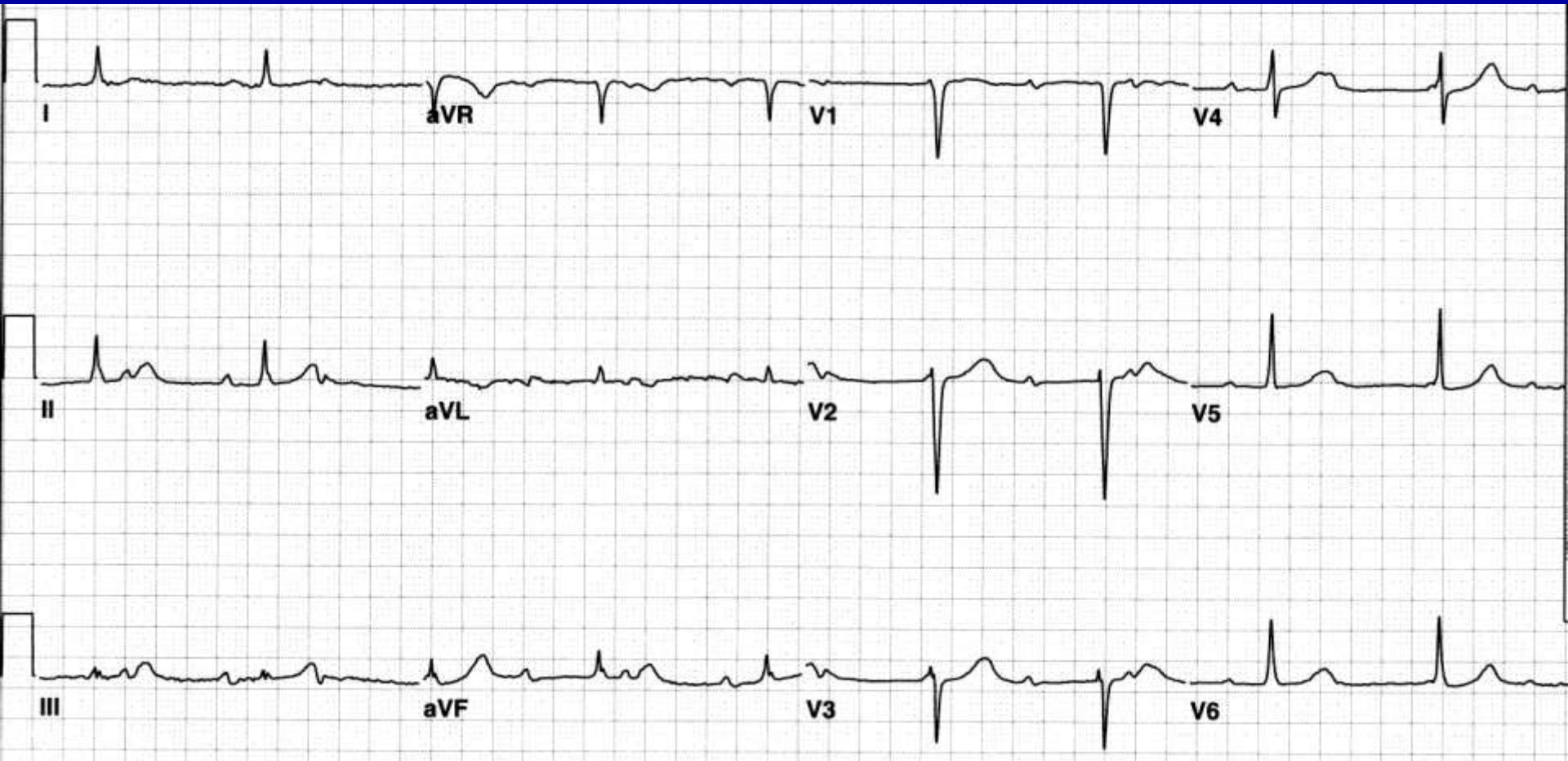
Third Degree AV block (Complete Heart Block)



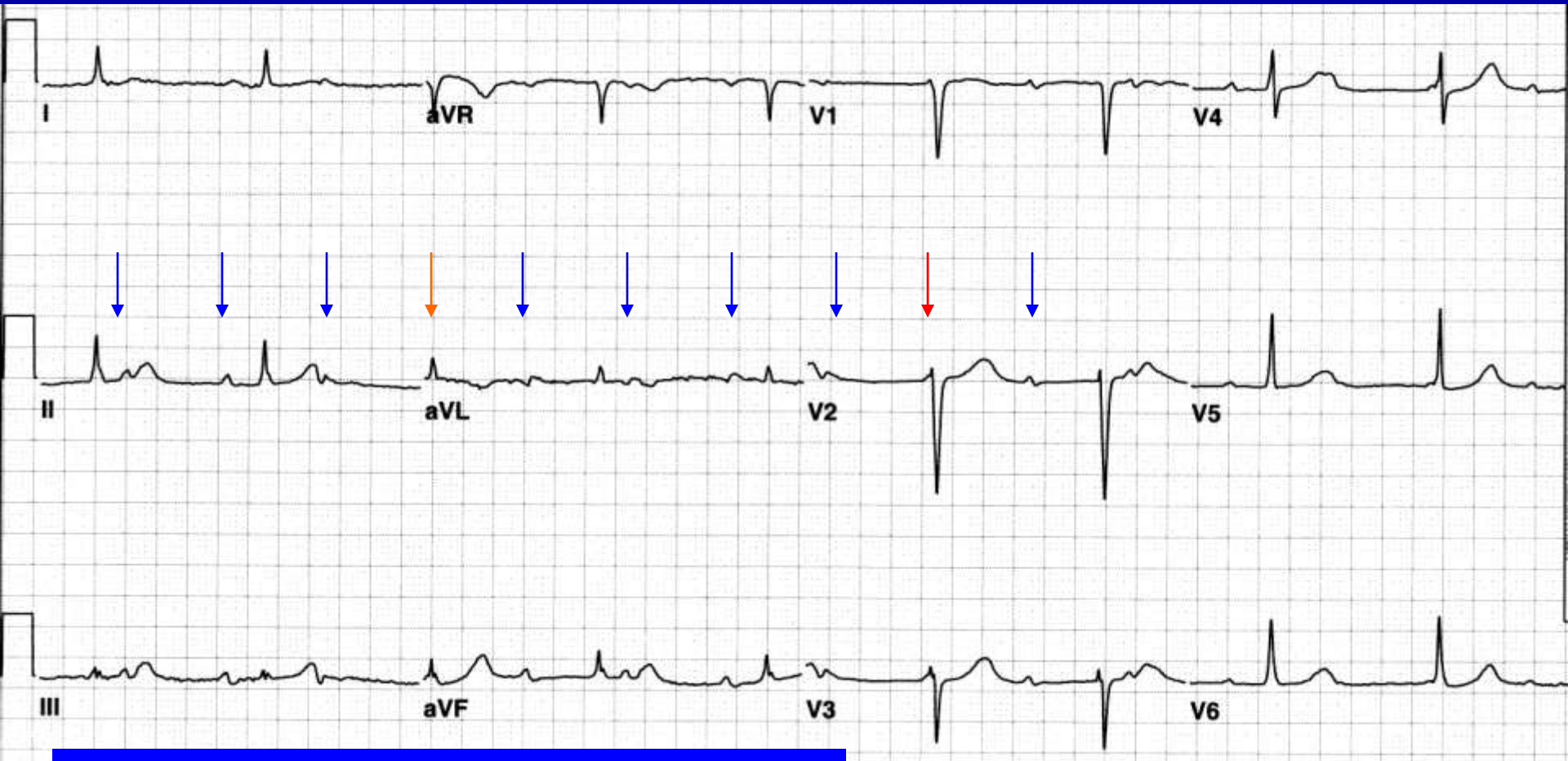
Third Degree AV block (Complete Heart Block)



Third Degree AV block (Complete Heart Block)

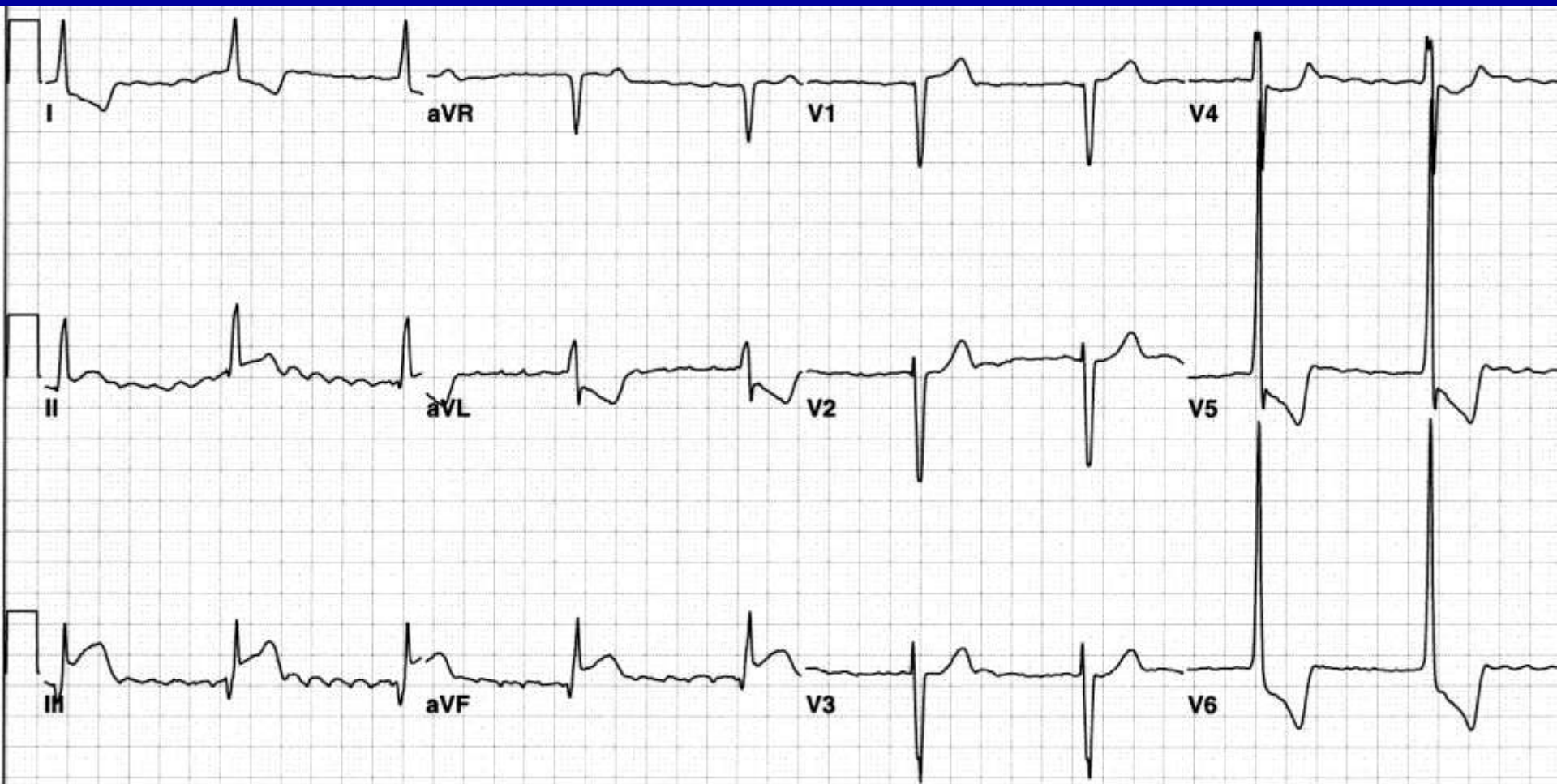


Third Degree AV block (Complete Heart Block)



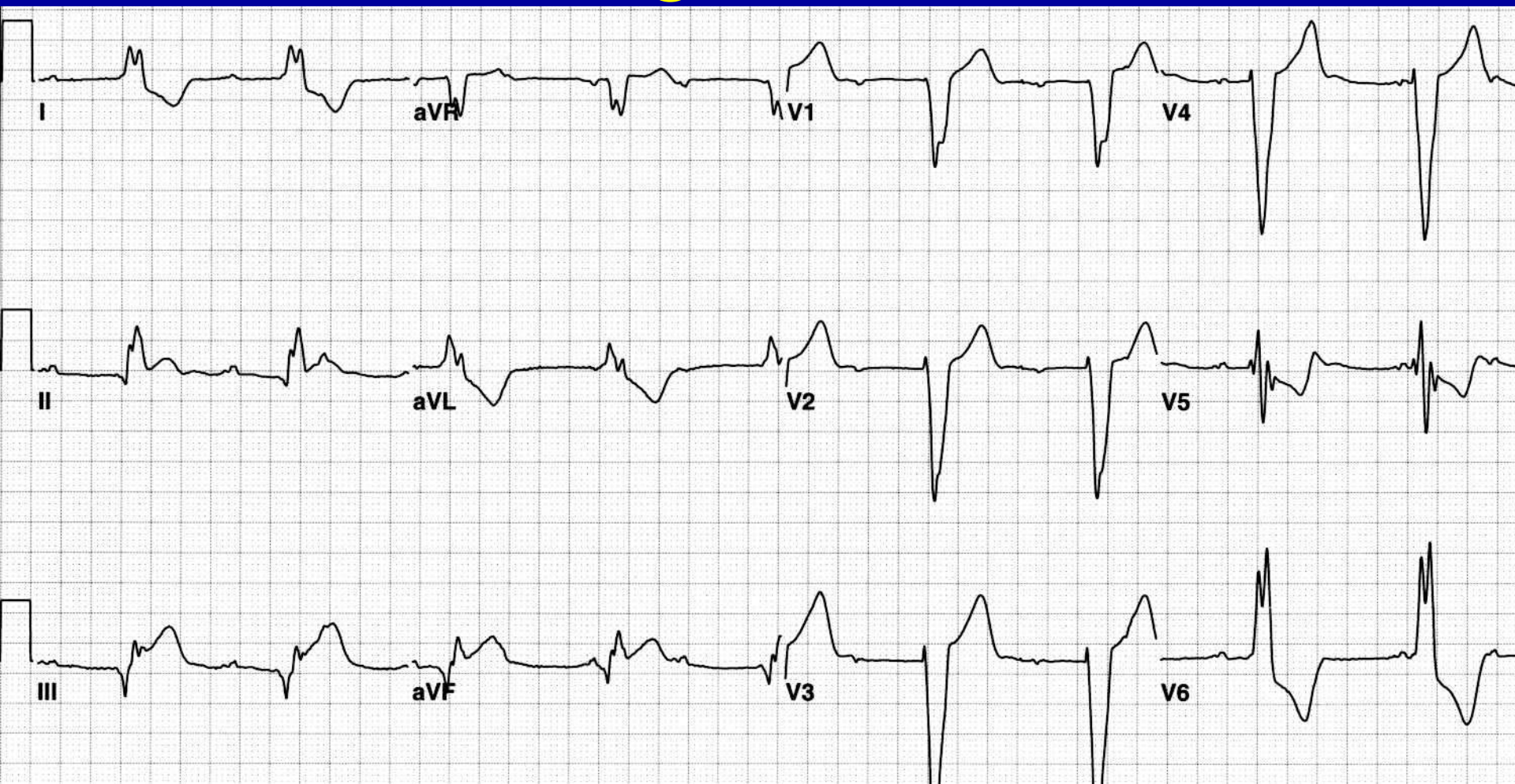Narrow QRS - junctional escape

Third Degree AV block

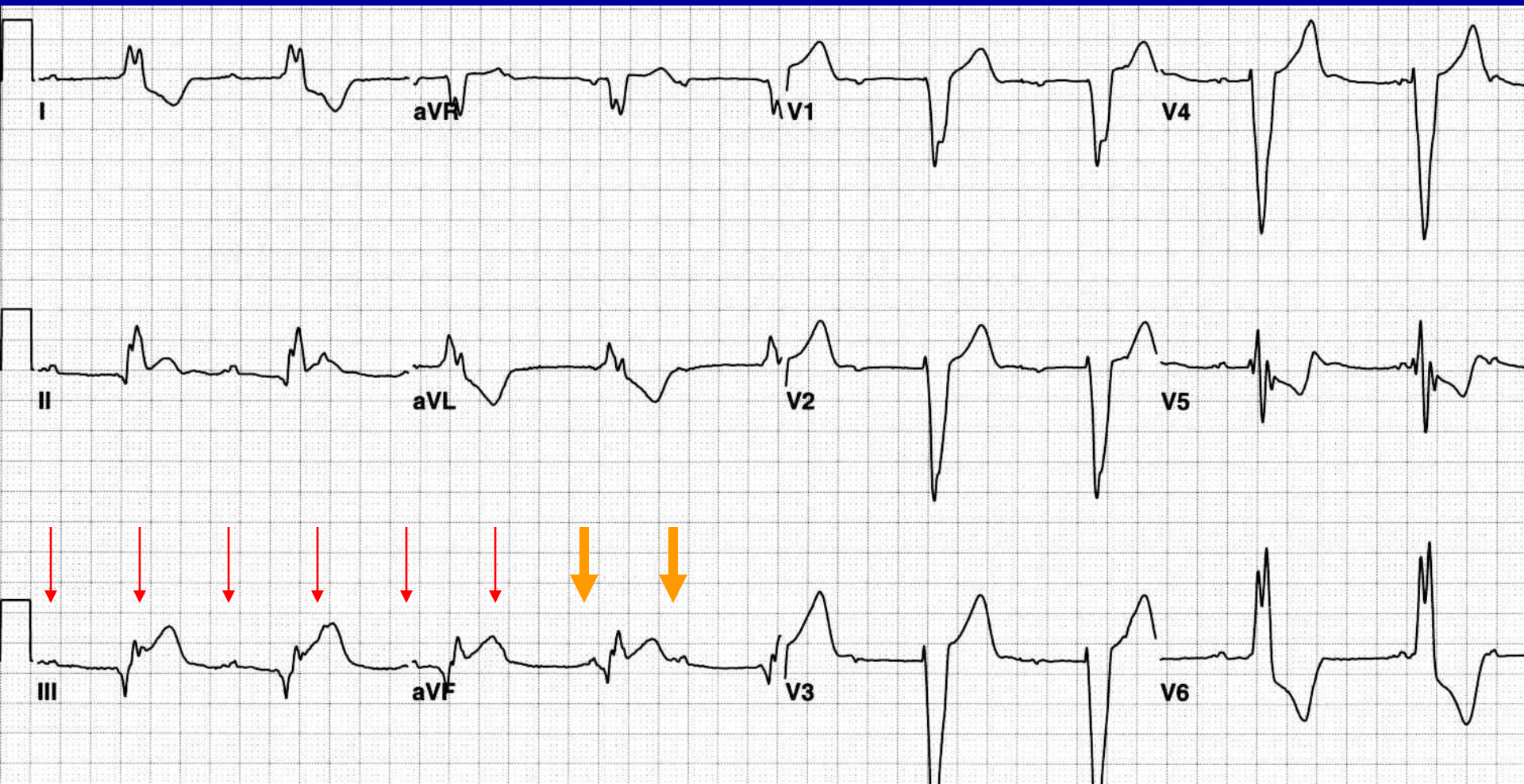


Atrial fibrillation with narrow QRS - junctional escape.
Acute inferior injury pattern!

Third Degree AV block



Third Degree AV block



Wide QRS (LBBB pattern) - ventricular escape.
Acute inferior injury pattern!

Pseudo AV Block

- Most common cause of a pause – a non-conducted PAC (but don't be led astray by ventriculophasic sinus arrhythmia)
- Concealed His bundle extrasystole
- AV junctional parasystole with concealed conduction
- Concealed junctional discharges can delay a normal junctional escape rate

AV Dissociation

- Definition: Variability of the PR interval without heart block
 - Atrial and ventricular activities are independent
 - Ventricular rate is faster than atrial
 - No retrograde conduction
- AV dissociation is always a secondary diagnosis, consequent to a primary problem of automaticity or reentry, and the clinical significance is determined by the primary disorder

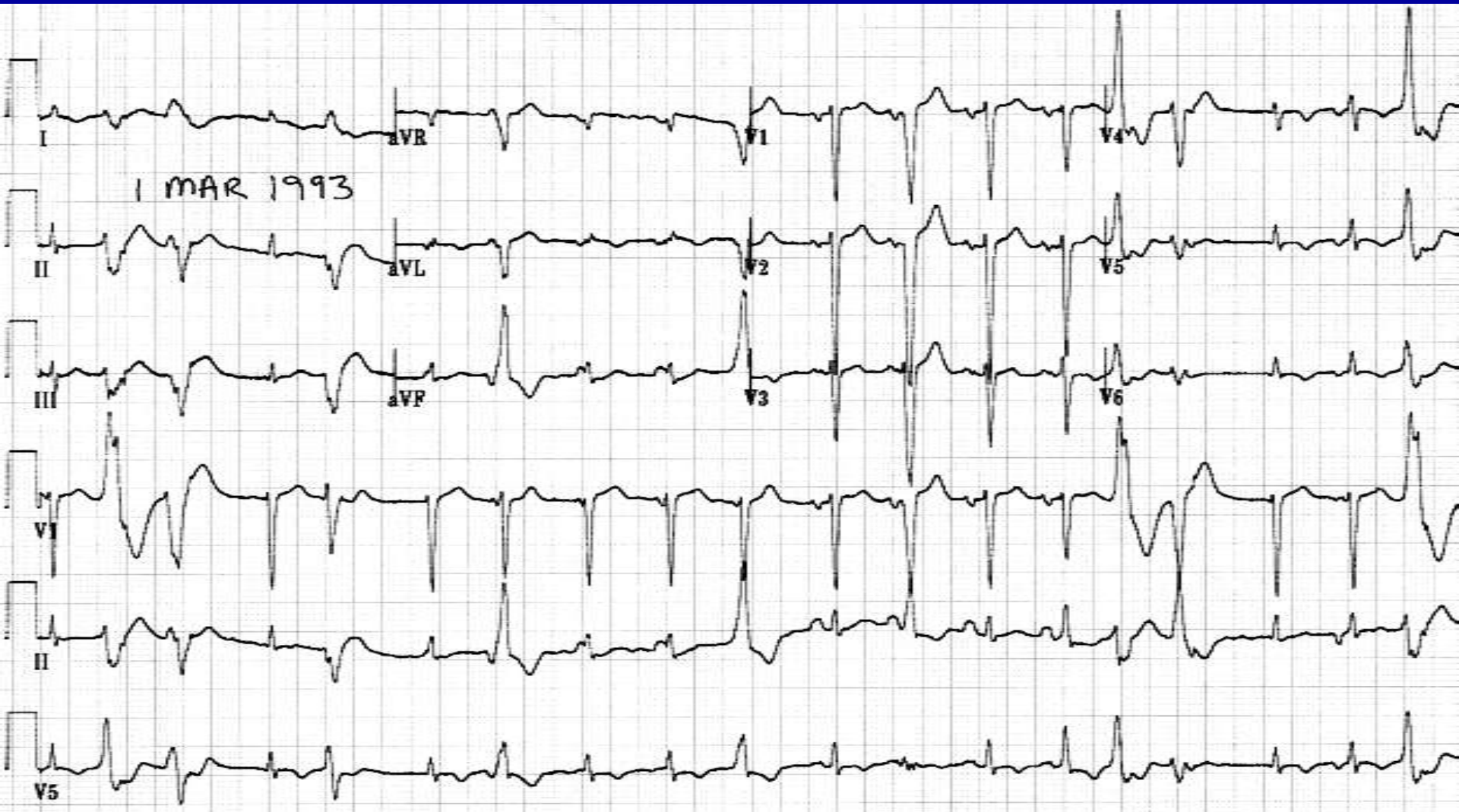
Terminology in AV Dissociation

- Usurpation:
 - The ventricular rhythm is too fast, usurping the normal atrial mechanism
 - Ventricular rate is generally normal or fast
- Default:
 - The atrial rhythm is too slow, defaulting to the normal escape ventricular mechanism
 - Ventricular rate is generally slow
- Complete AV dissociation: there is no connection between atrial and ventricular complexes
- Incomplete AV dissociation: there is evidence of AV conduction causing an early QRS complex
- Interference dissociation: incomplete AV dissociation
- Isorhythmic AV dissociation: the PR interval varies but the atrial and ventricular rates are identical

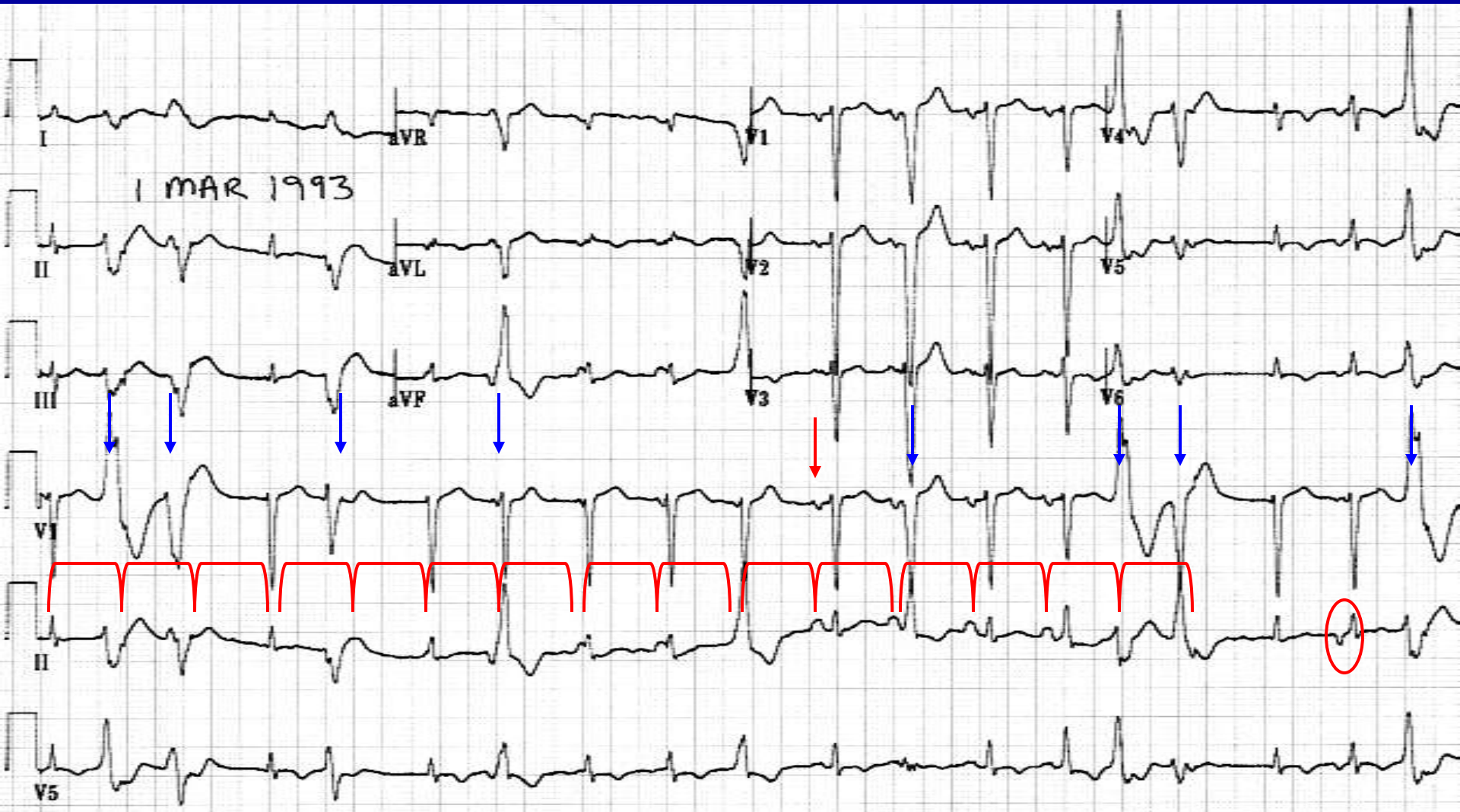
Examples in AV Dissociation

- Sinus bradycardia with junctional escape rhythm with AV dissociation by default with interference and escape capture bigeminy
- Ventricular tachycardia with AV dissociation by usurpation without interference, sinus rhythm
- Ventricular tachycardia with sinus rhythm and complete AV dissociation
- Sinus bradycardia, junctional escape rhythm, isorhythmic incomplete AV dissociation

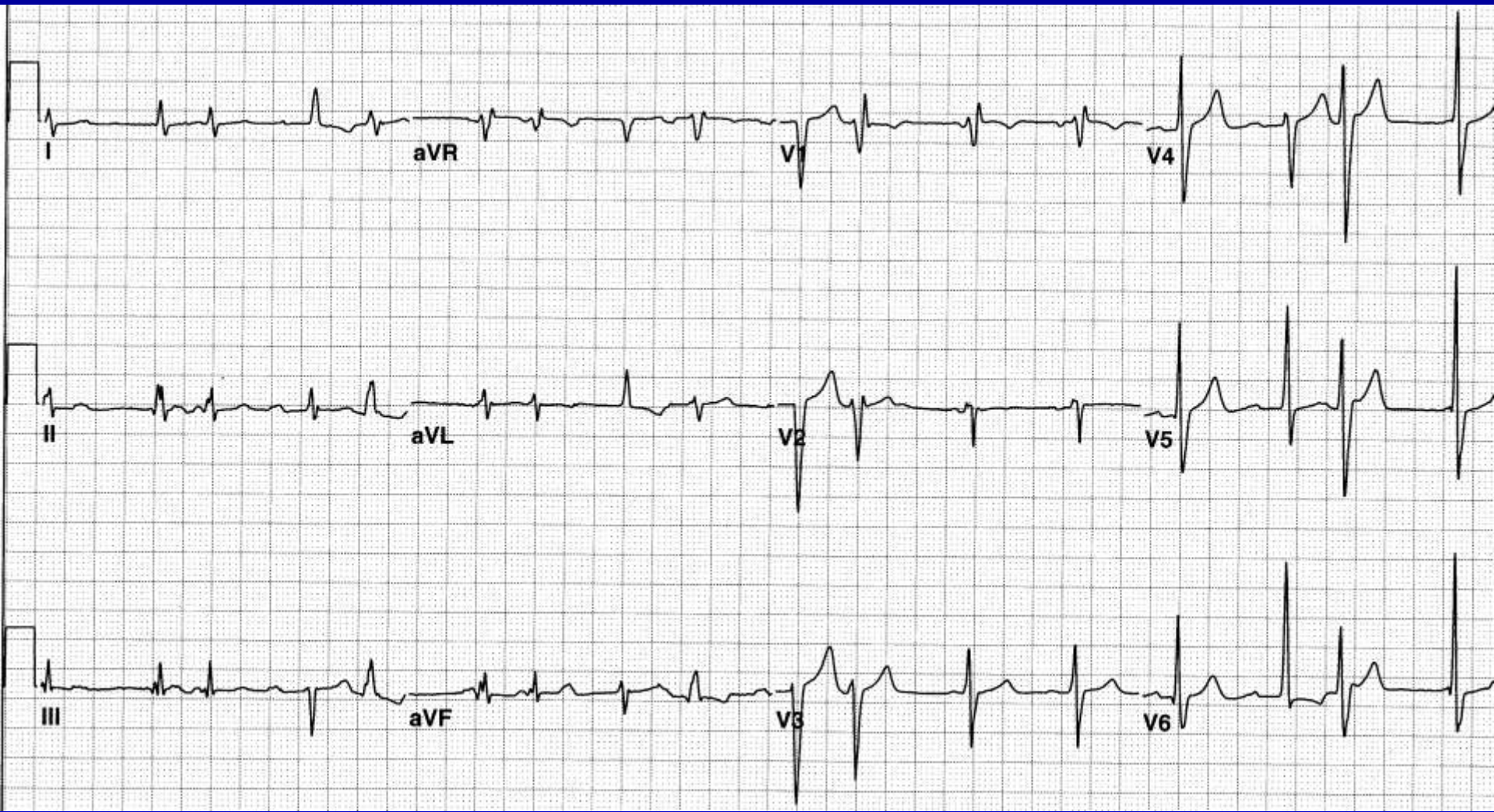
What is the rhythm?



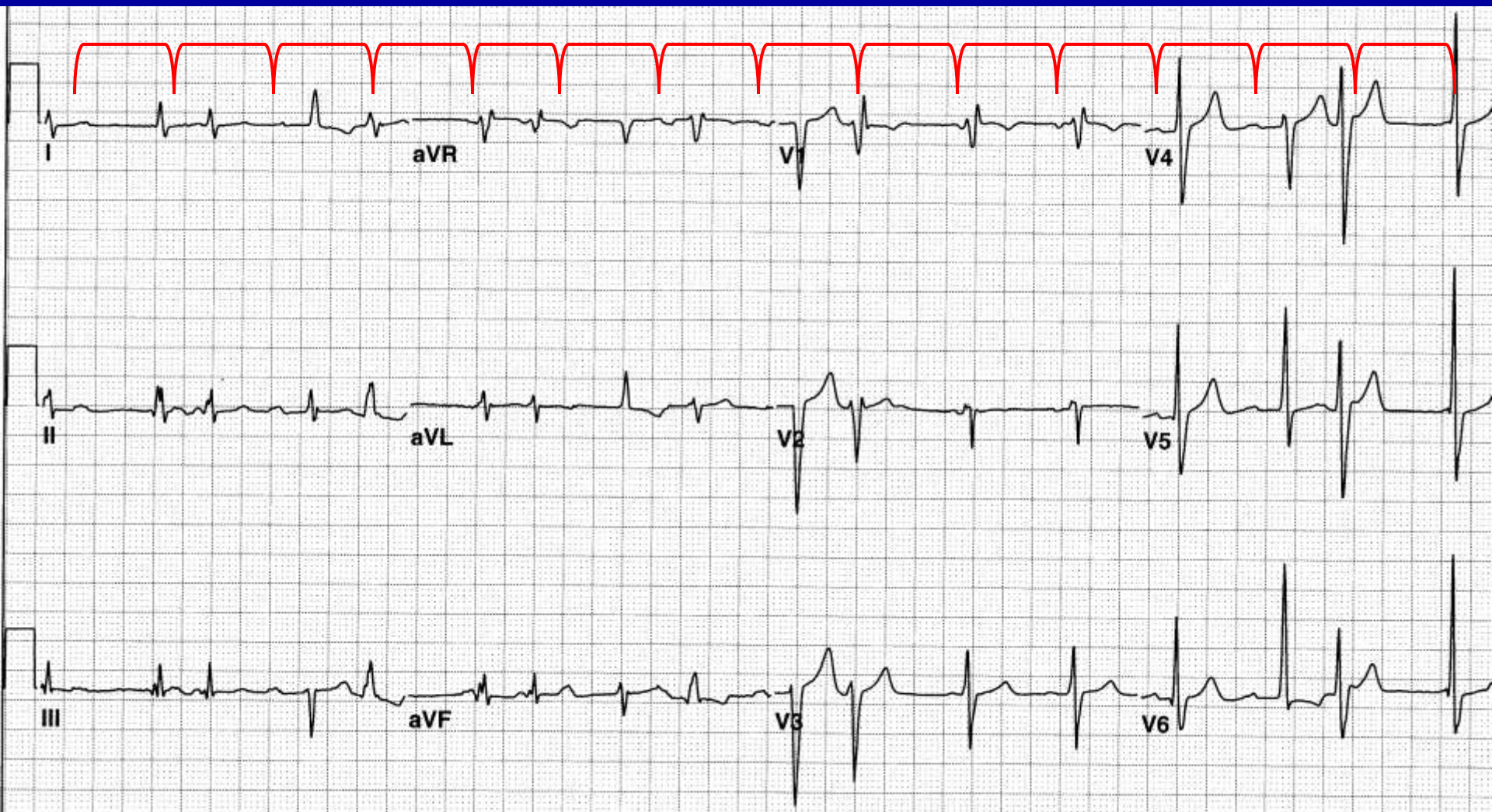
Sinus Tachycardia, PVC's and fusion beats, accelerated junctional rhythm, PAC's



What is the Rhythm?

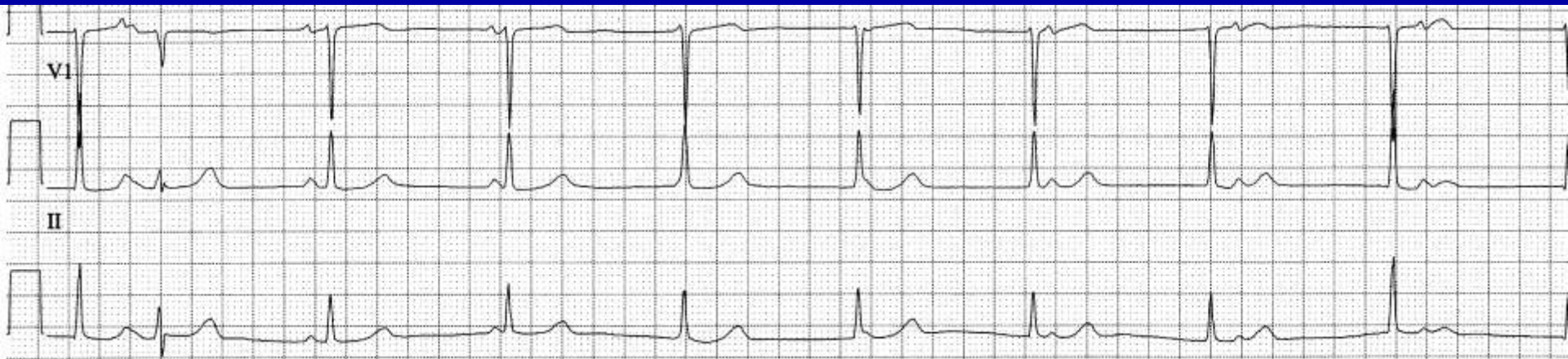

Sinus rhythm, Accelerated Junctional rhythm, PVC's

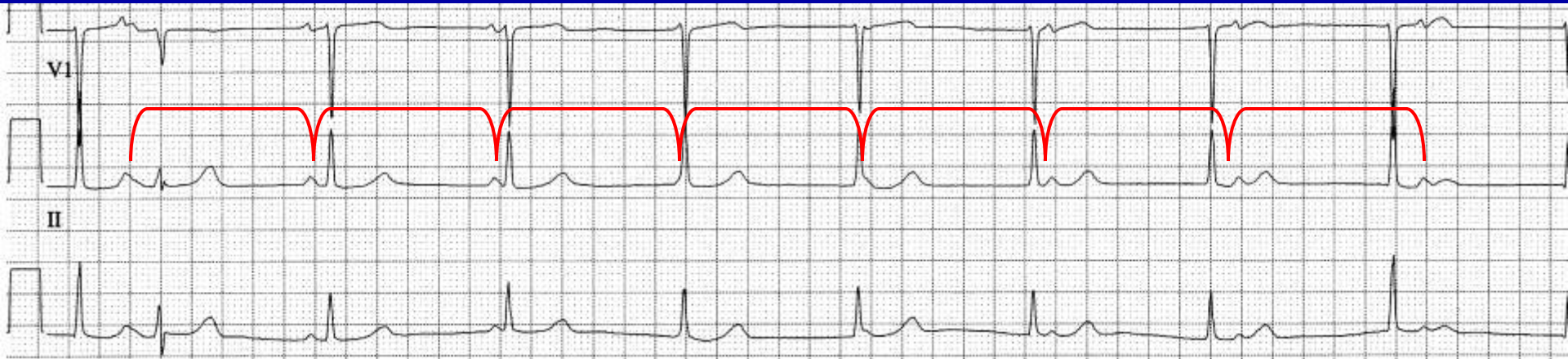


15 P waves, 17 QRS complexes

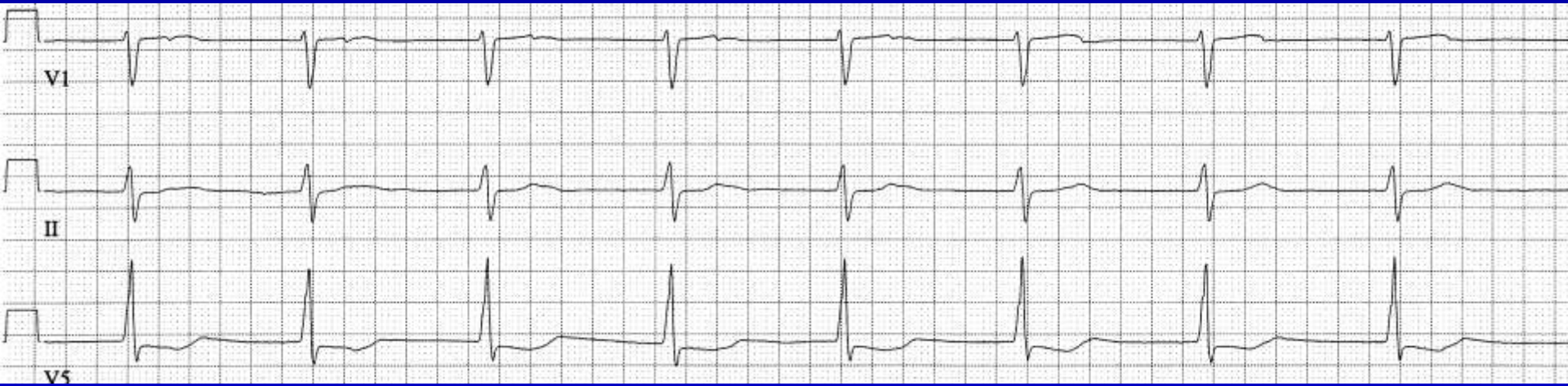
What is the rhythm?



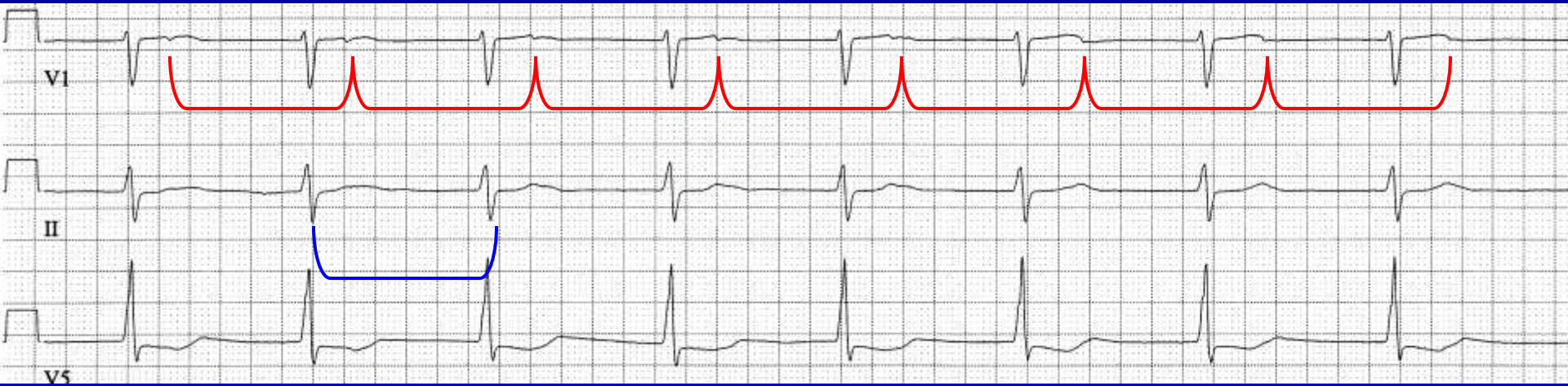Sinus bradycardia, junctional escape rhythm, AV dissociation with interference (incomplete AV dissociation)



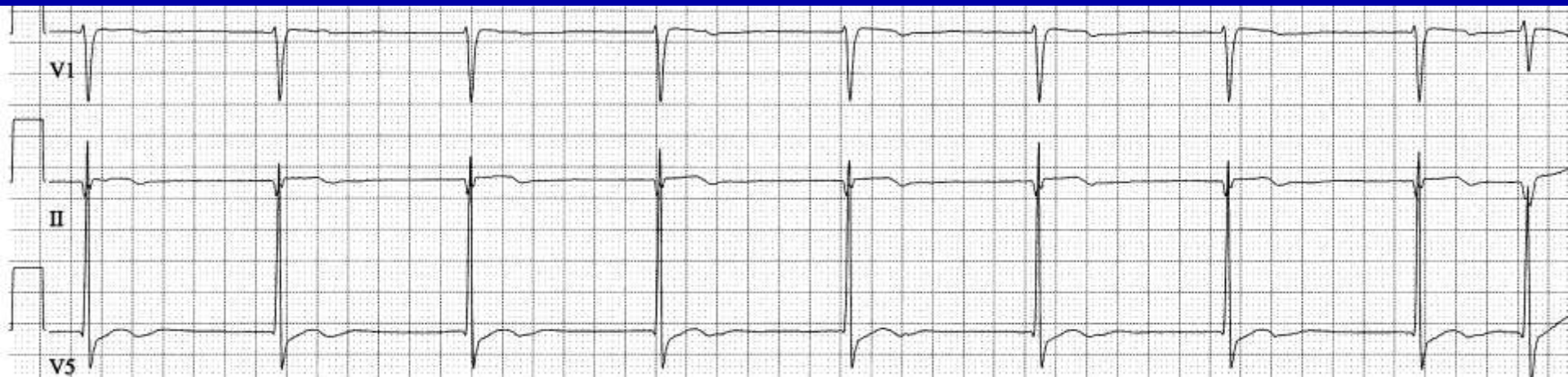
What is the rhythm?



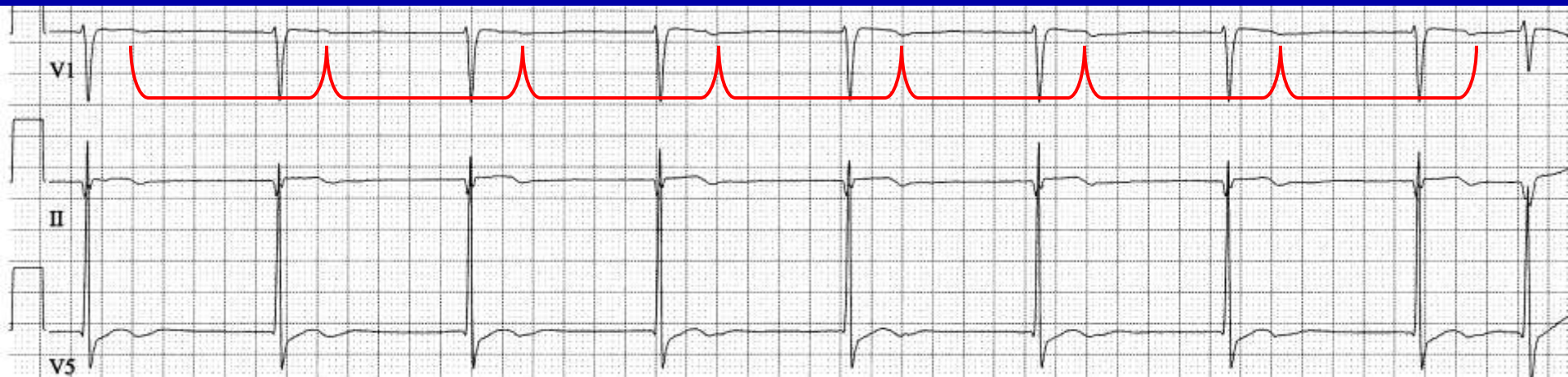
Junctional rhythm, sinus bradycardia, AV dissociation



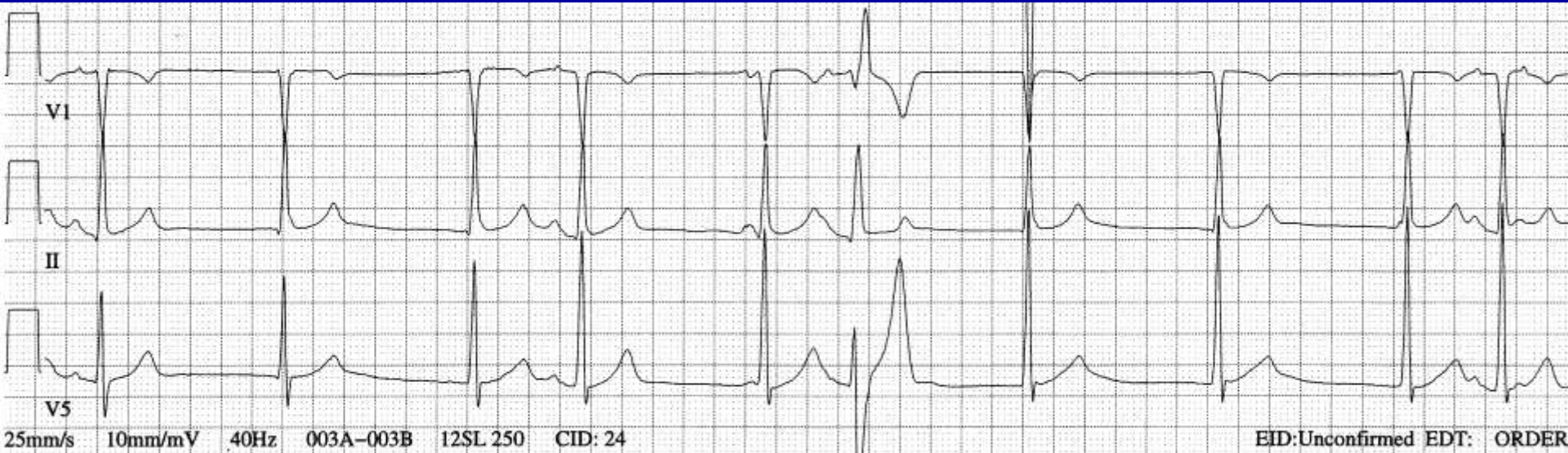
What is the rhythm?



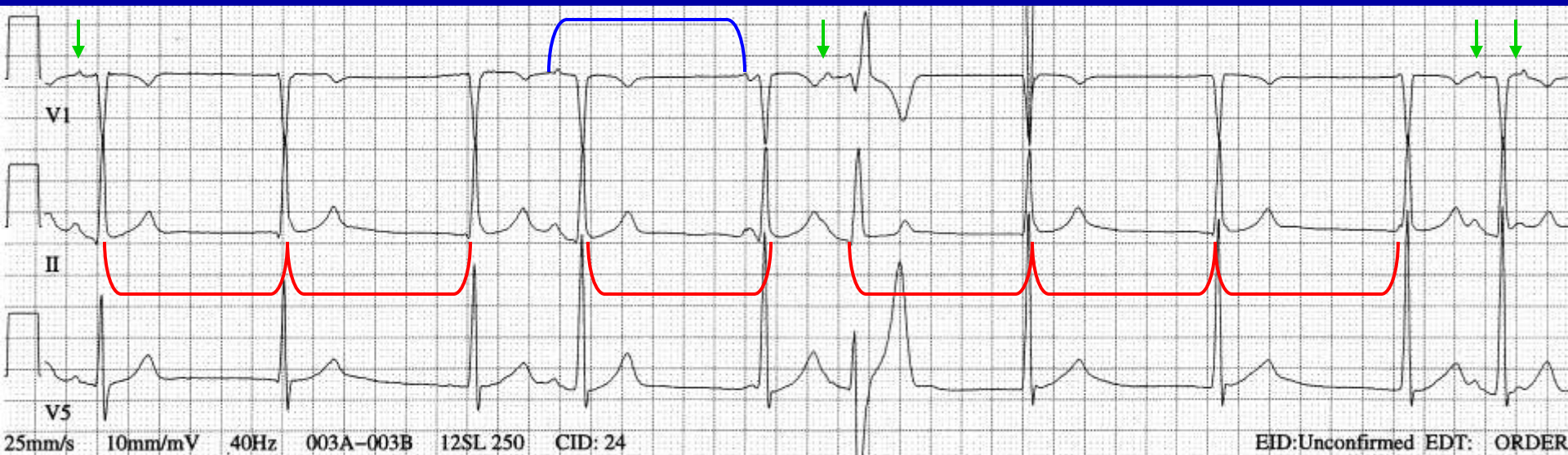
Sinus bradycardia, junctional escape rhythm, one capture beat



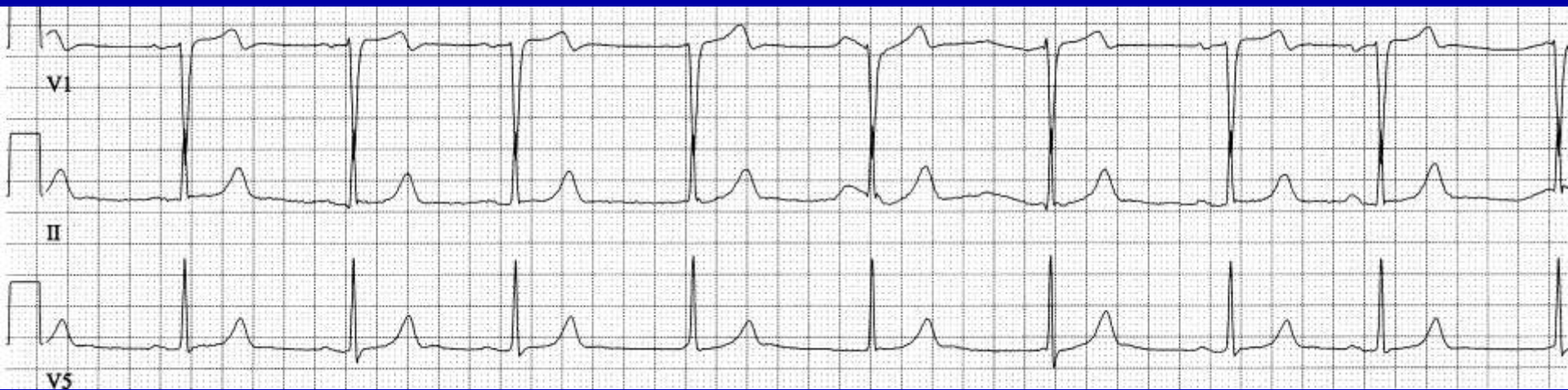What is the rhythm?



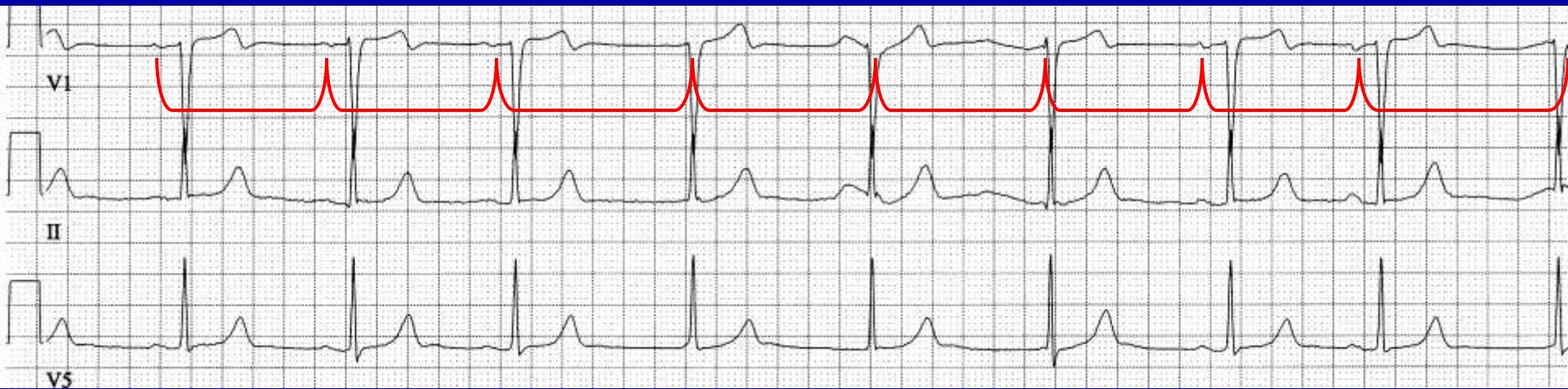Junctional rhythm, sinus bradycardia, PAC's, some conducted, some aberrant, some nonconducted



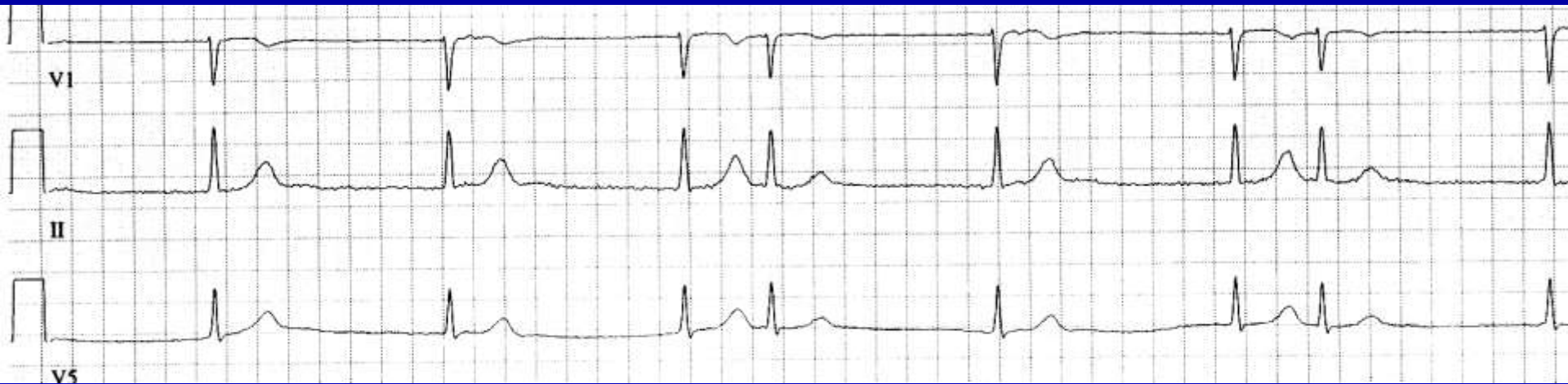
What is the Rhythm?



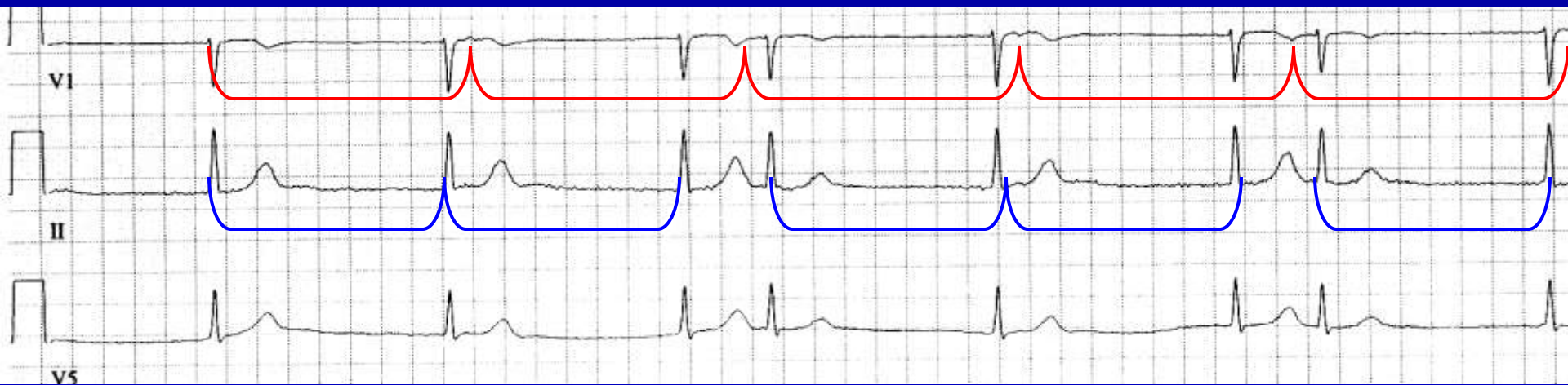Sinus rhythm, sinus arrhythmia, junctional escape rhythm, isorhythmic AV dissociation



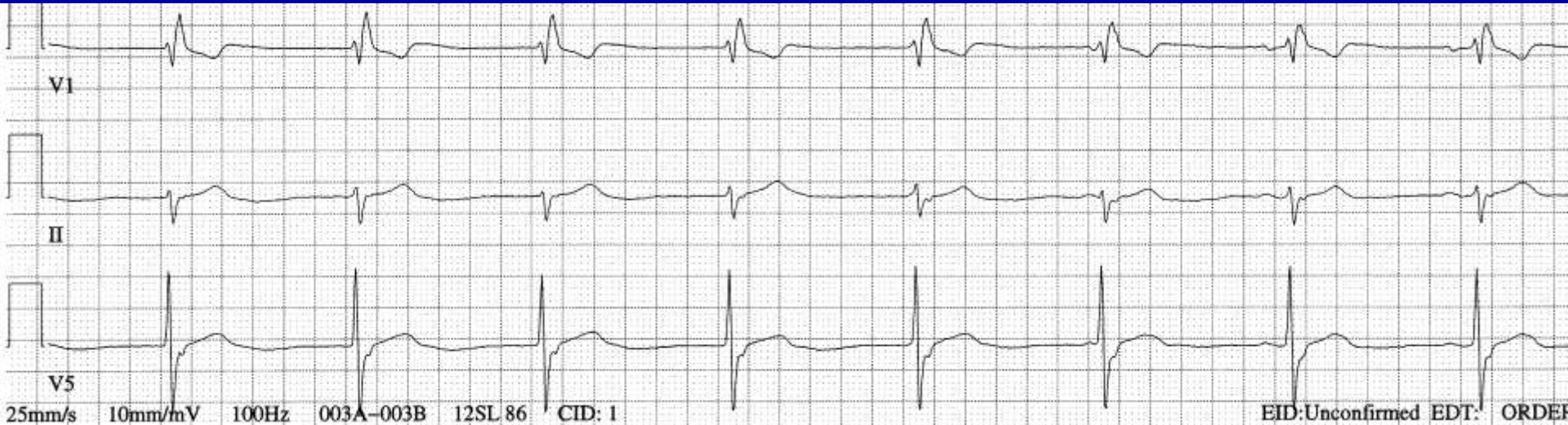
What is the Rhythm?



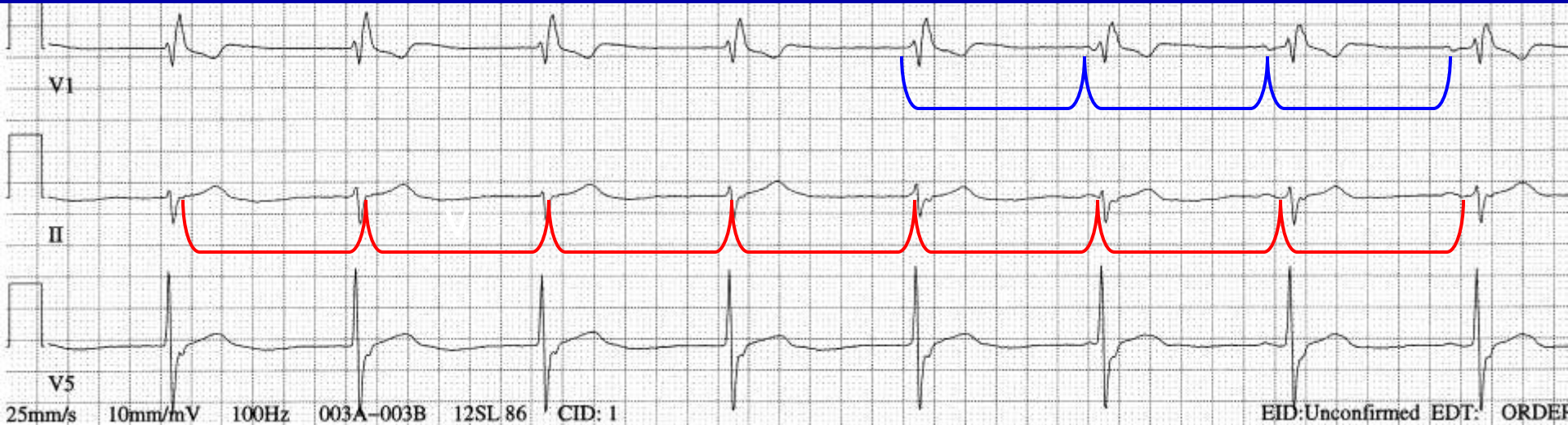
Sinus bradycardia, junctional escape rhythm, AV dissociation with interference, escape capture



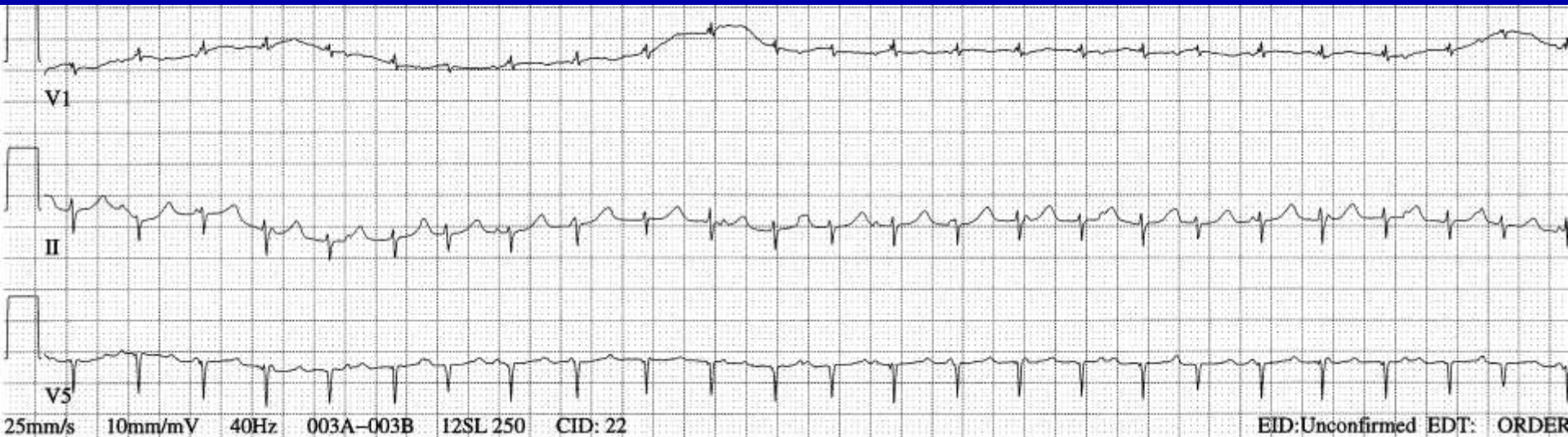
What is the rhythm?



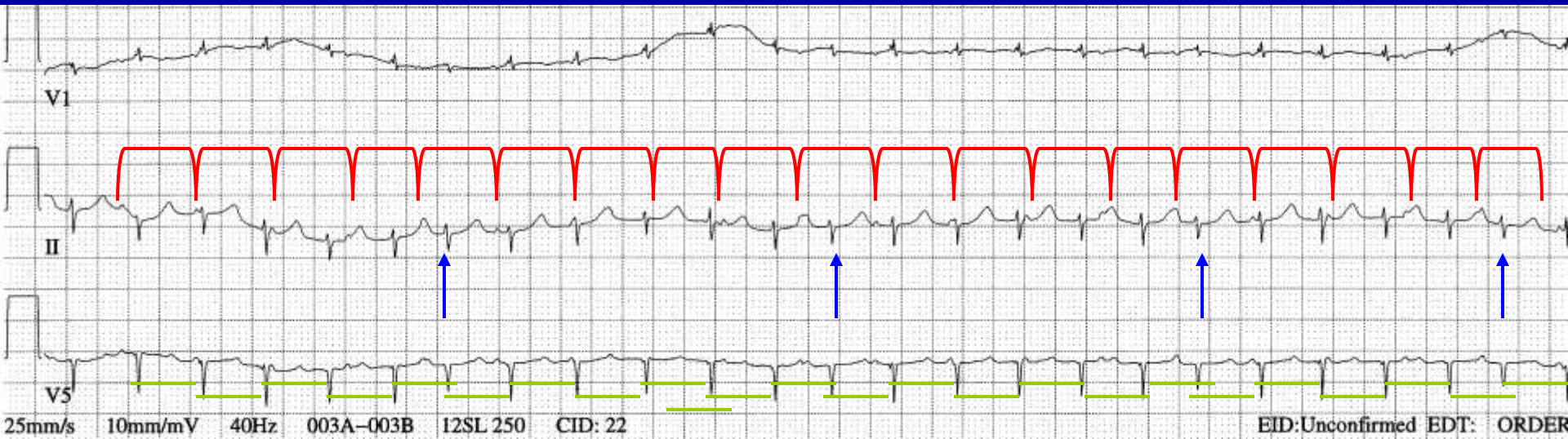
Junctional rhythm with RBBB or ventricular escape rhythm, isorhythmic AV dissociation, sinus bradycardia



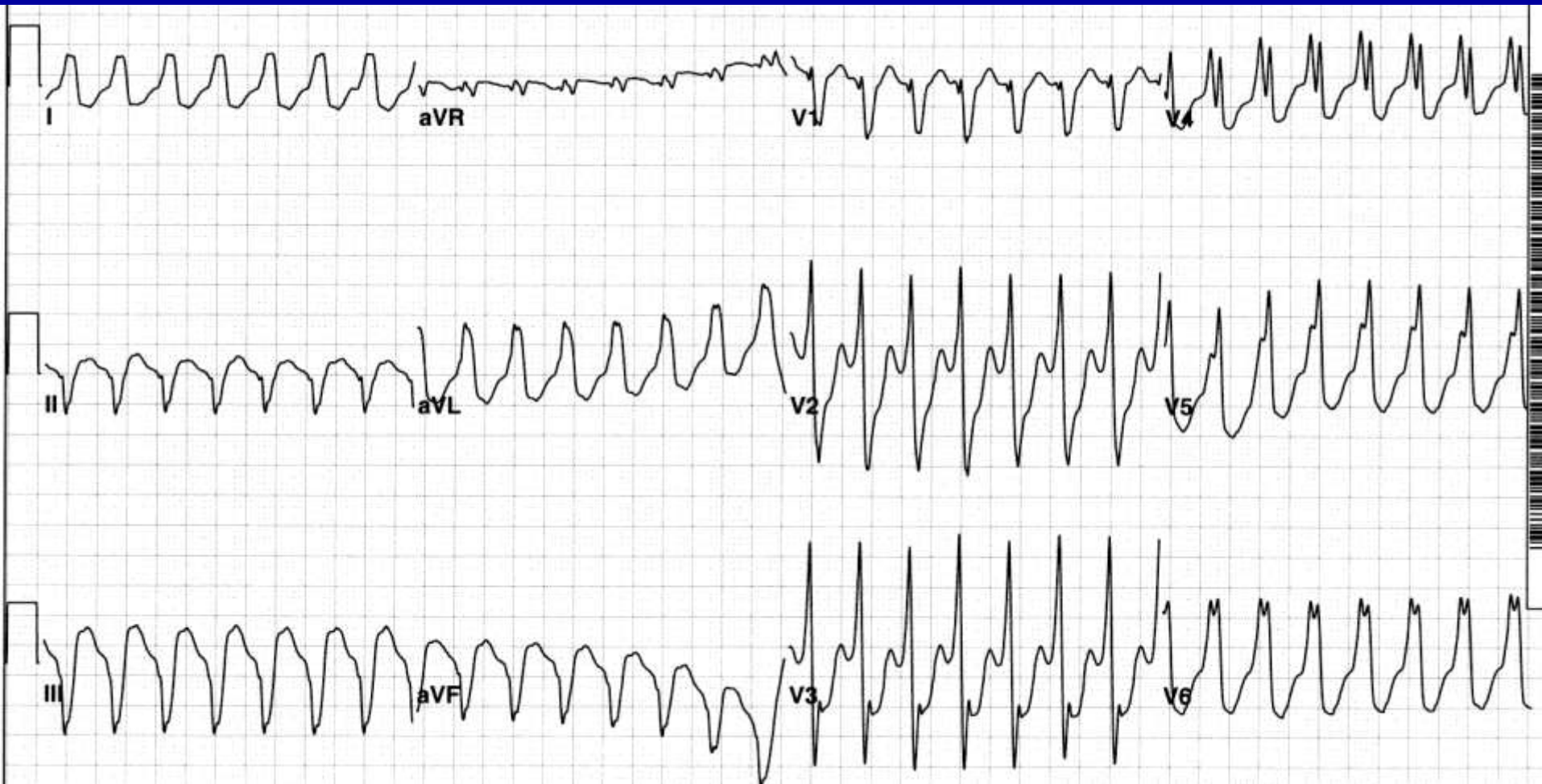
What is the rhythm?



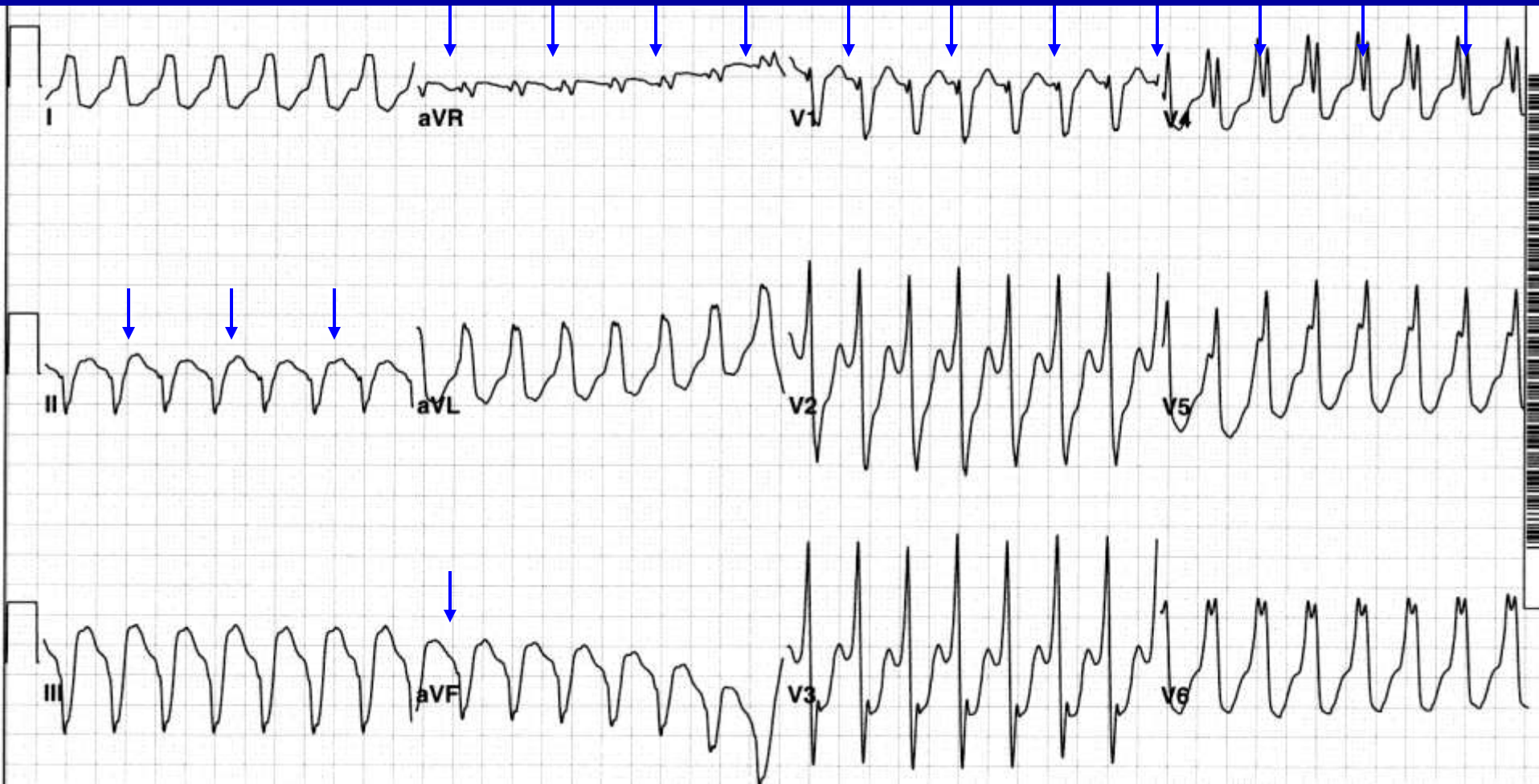
Sinus tachycardia, junctional tachycardia, incomplete AV dissociation

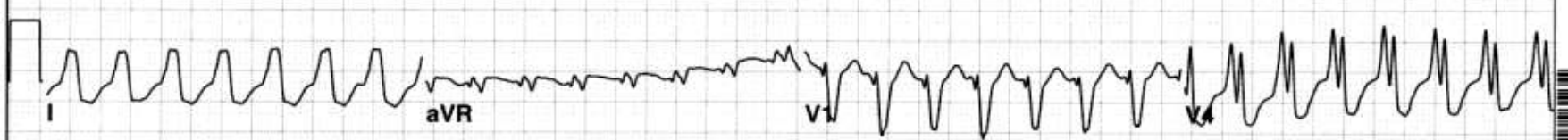

What is the rhythm?

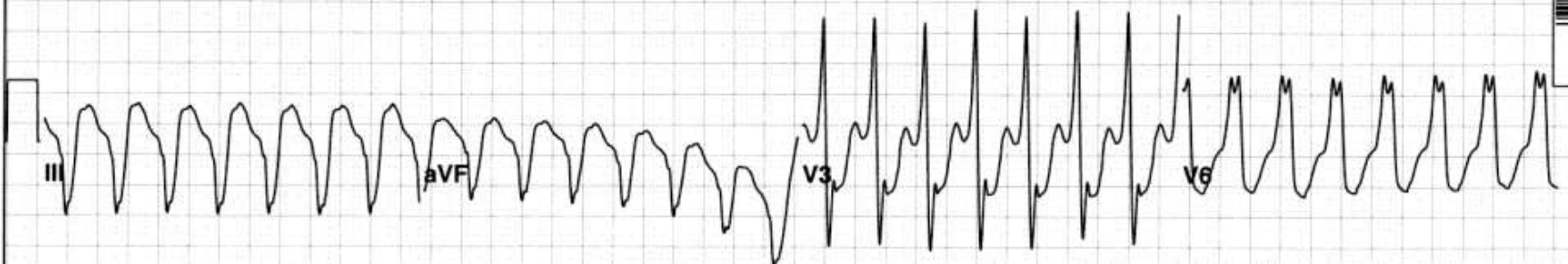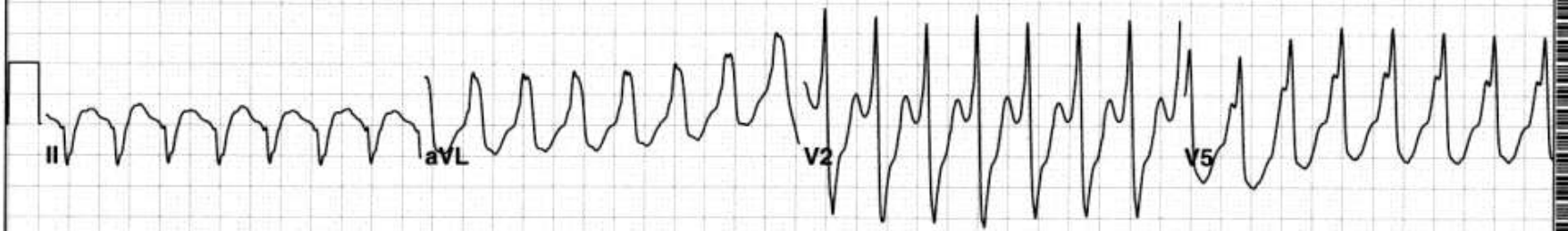


Ventricular tachycardia, sinus rhythm with sinus rate slightly less than half the ventricular rate



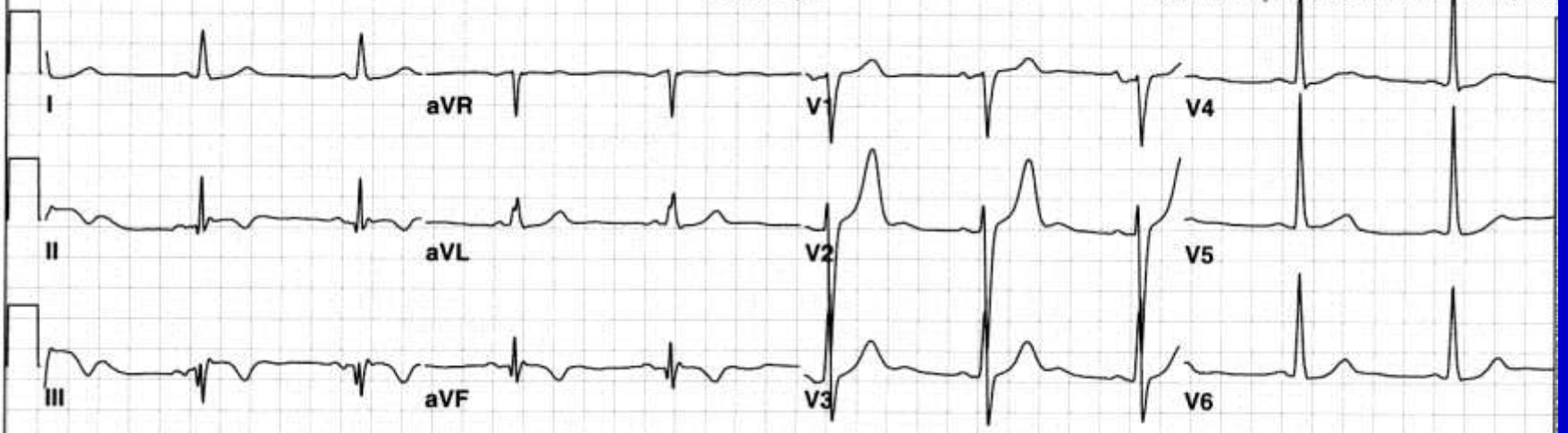

Ventricular tachycardia and baseline ECG

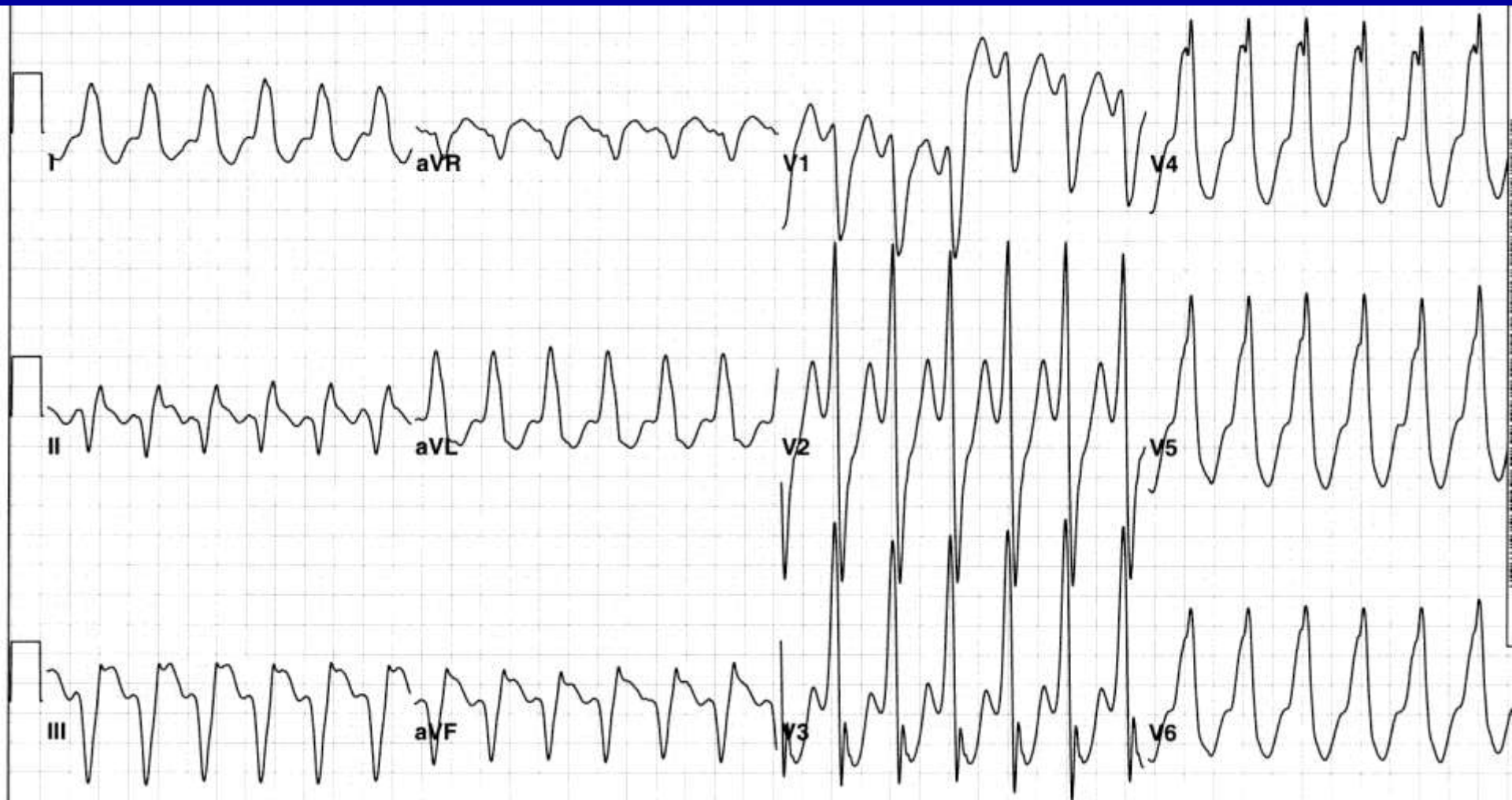

Referred by:

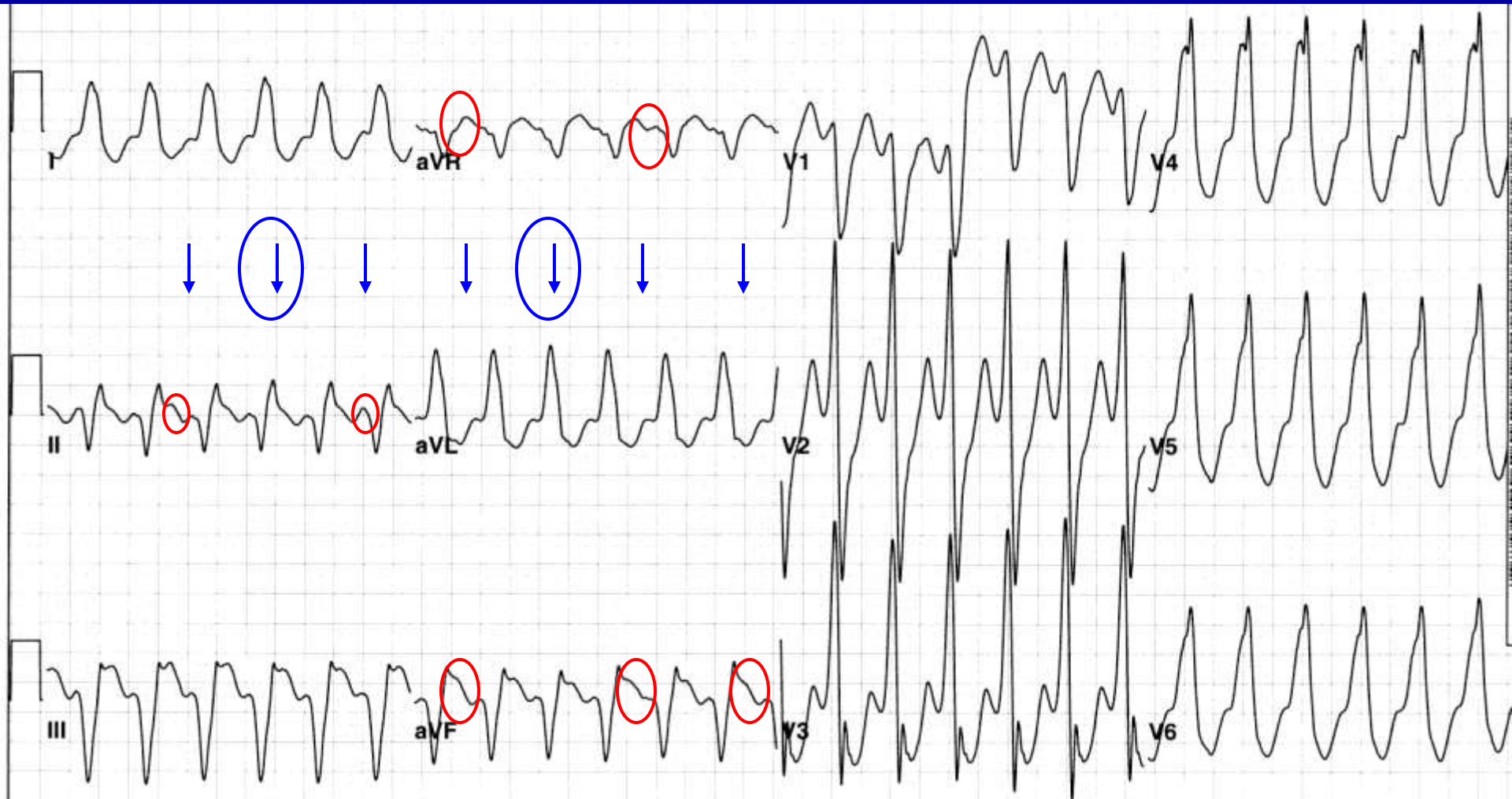
Confirmed by: JAMES M. CAMPBELL, MD



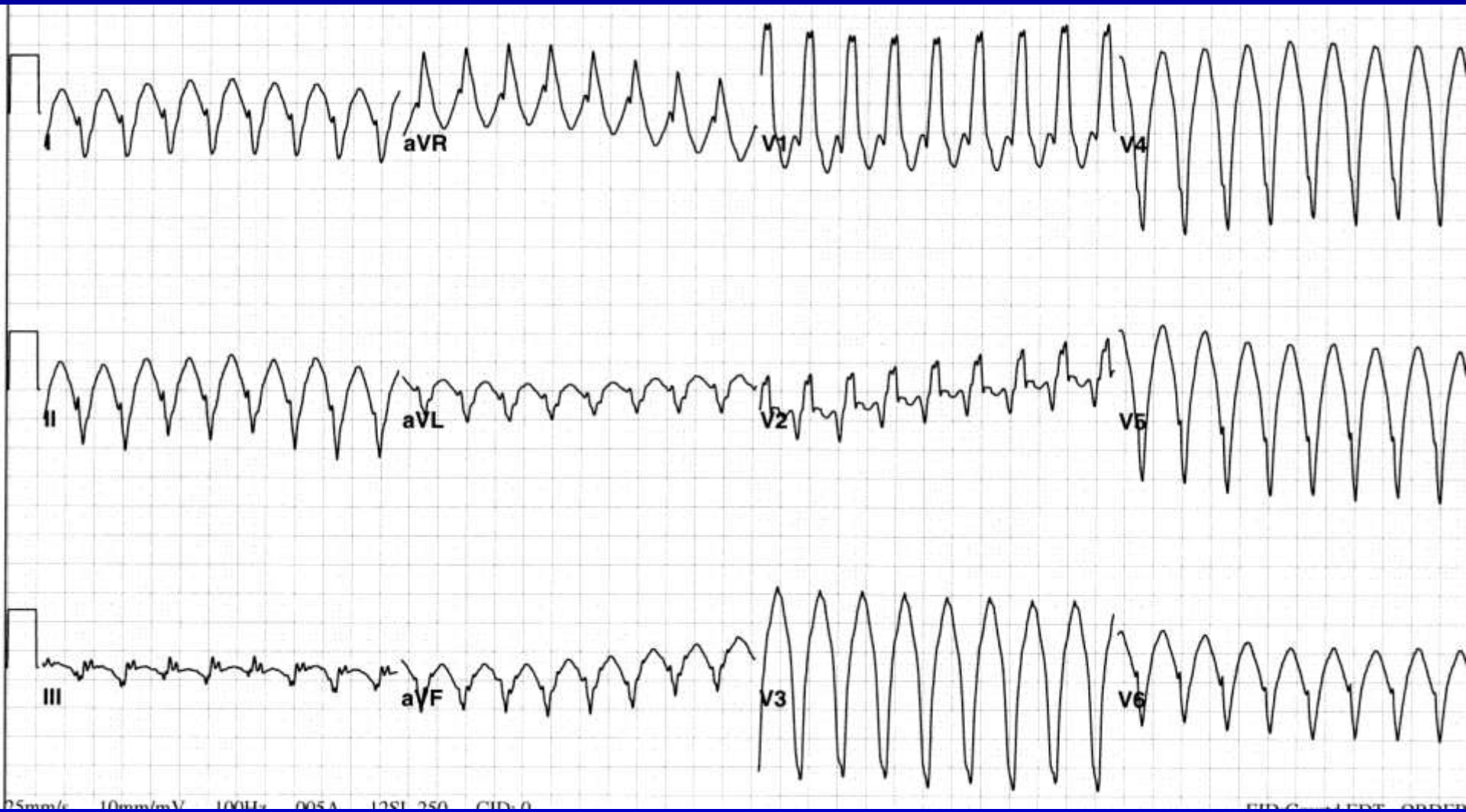
What is the rhythm?



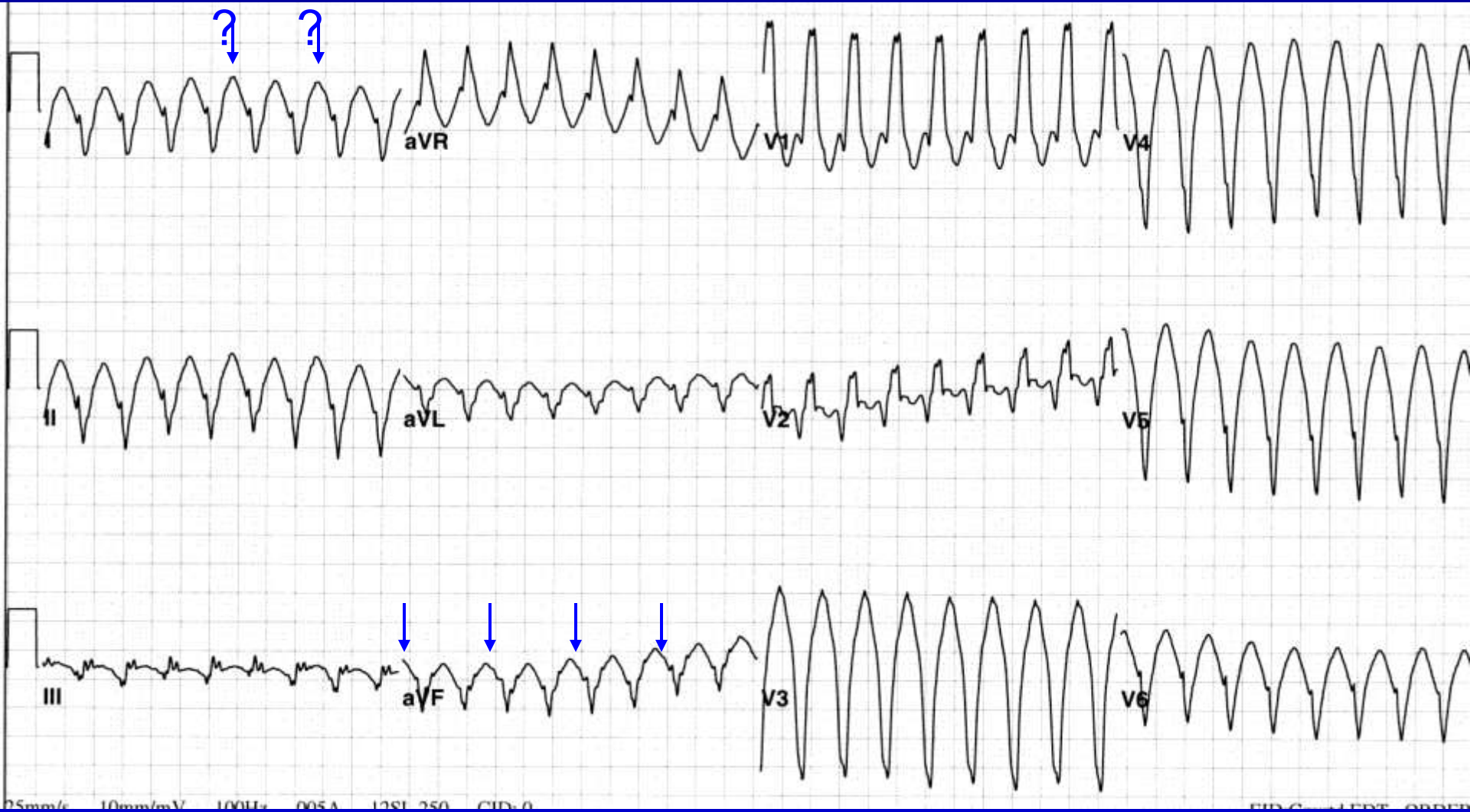
Ventricular Tachycardia, sinus tachycardia, AV dissociation by usurpation



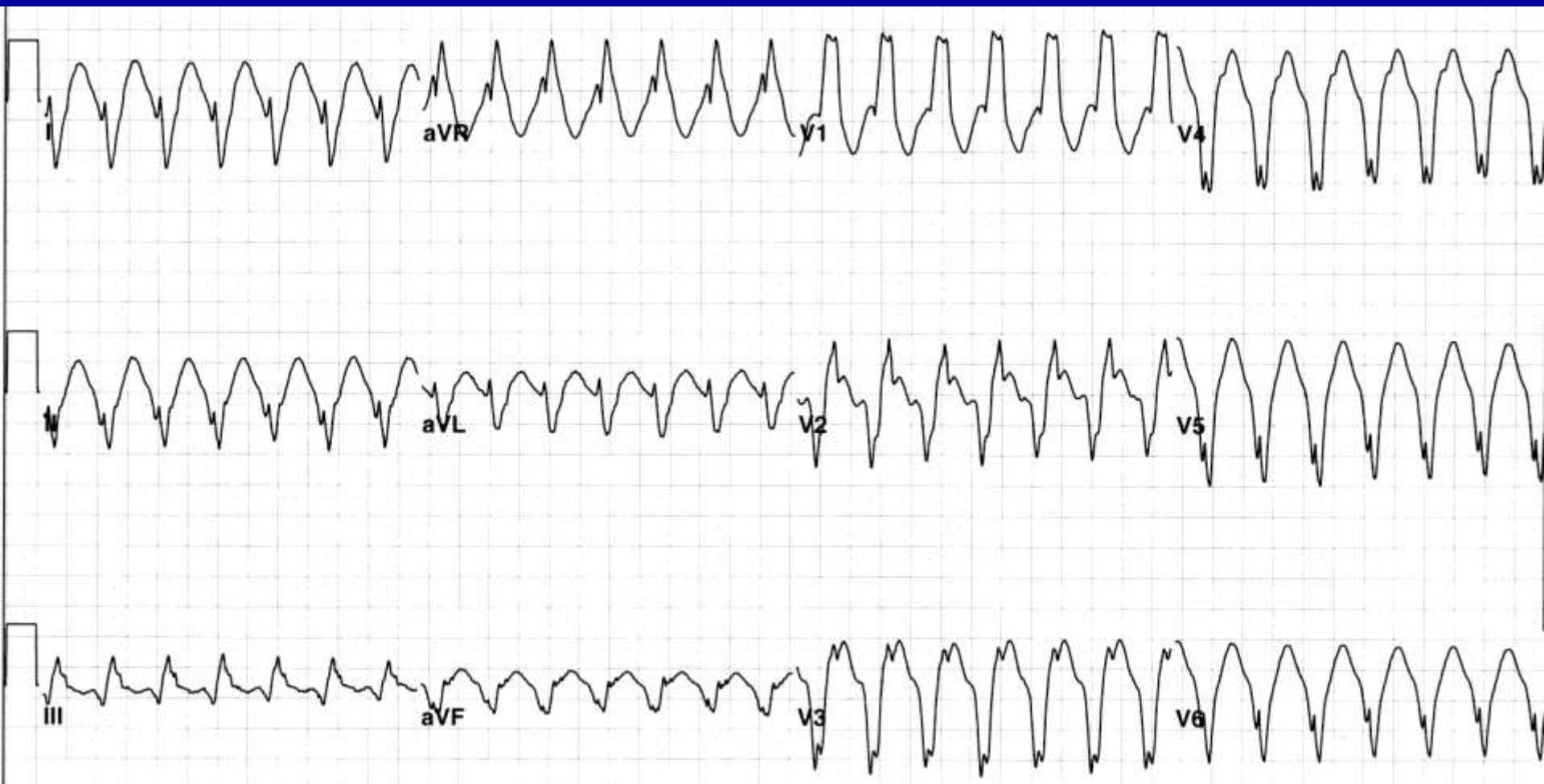
What is the rhythm?



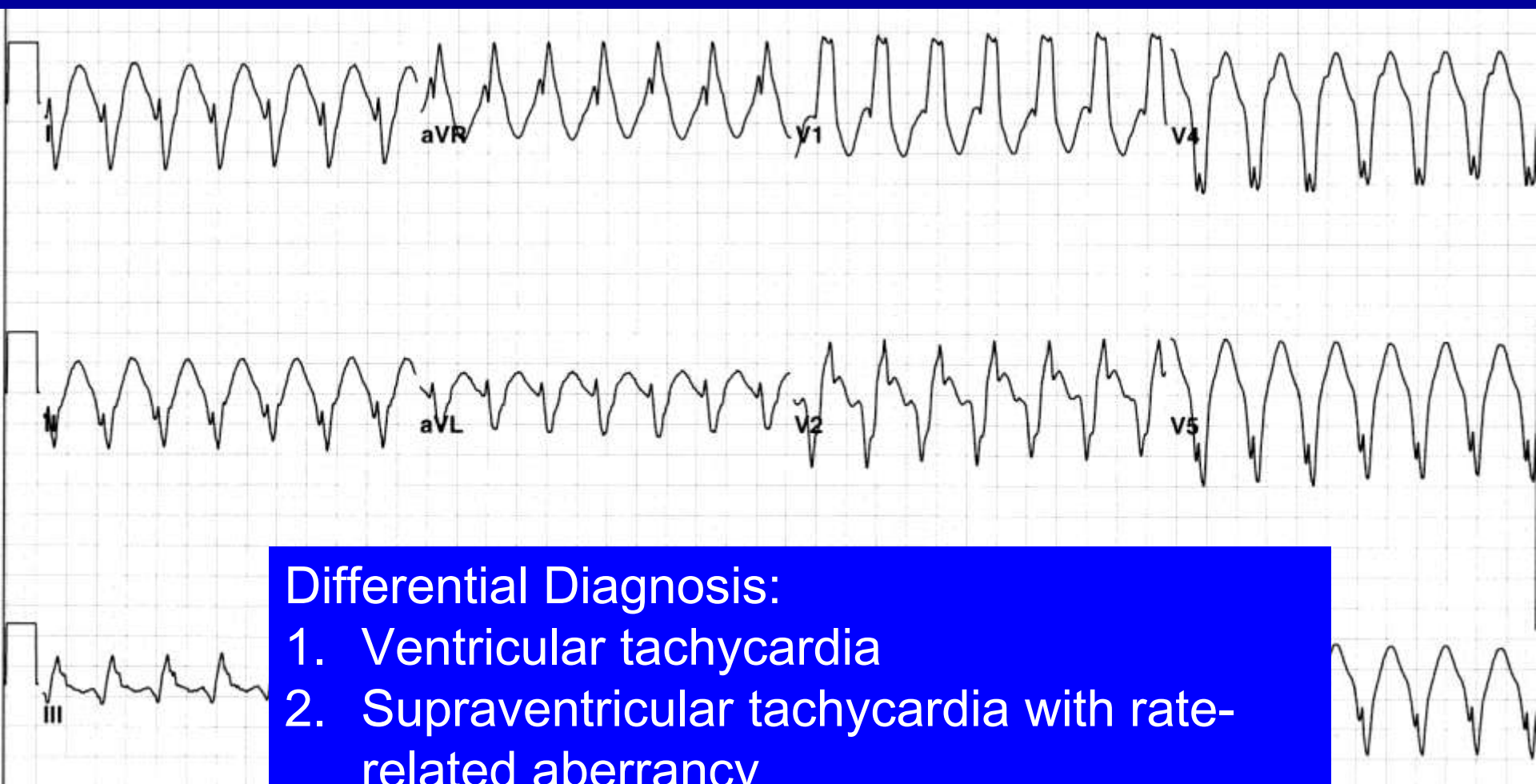
Wide Complex Tachycardia



What is the rhythm?



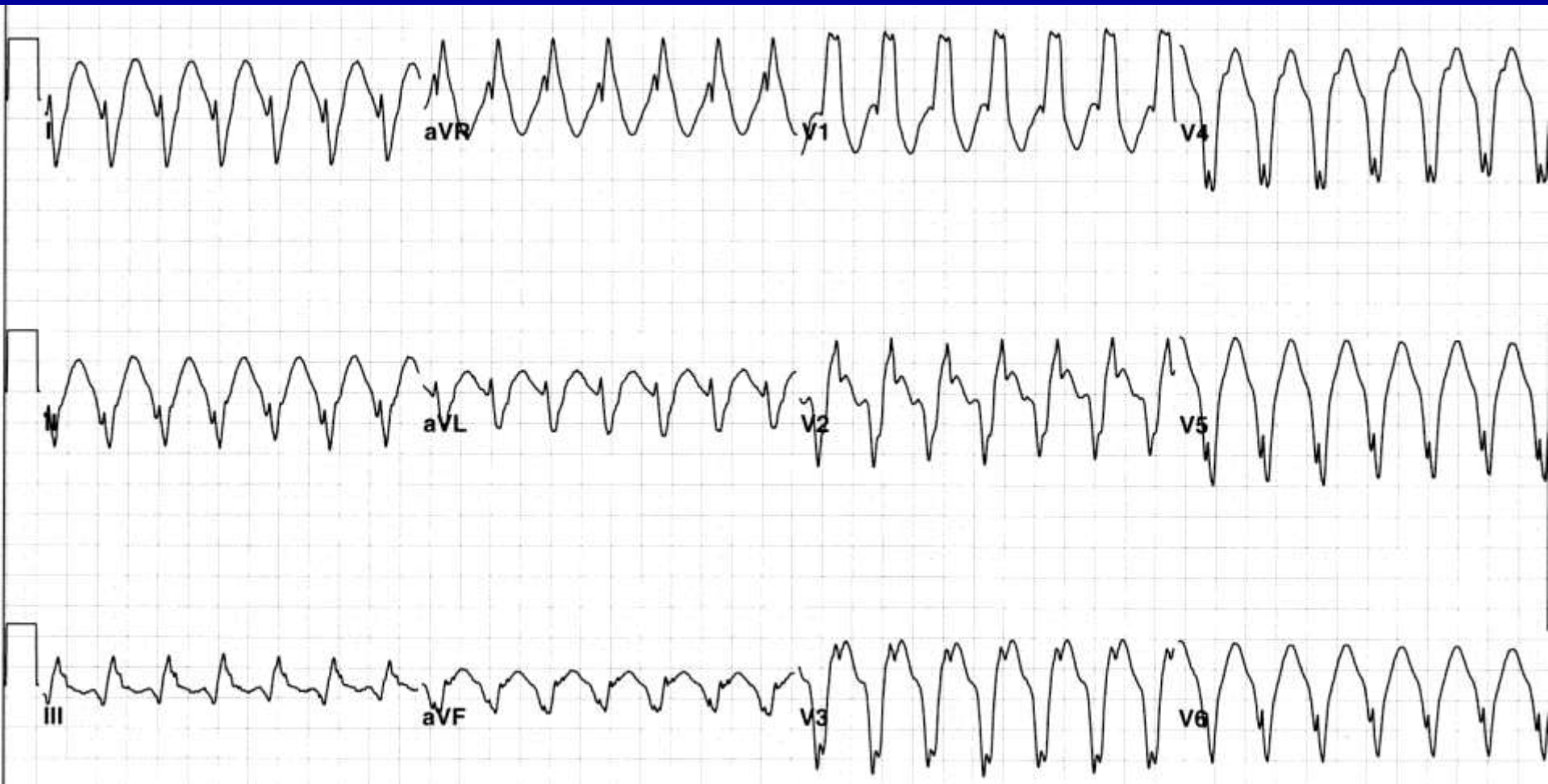
What is the rhythm?



Differential Diagnosis:

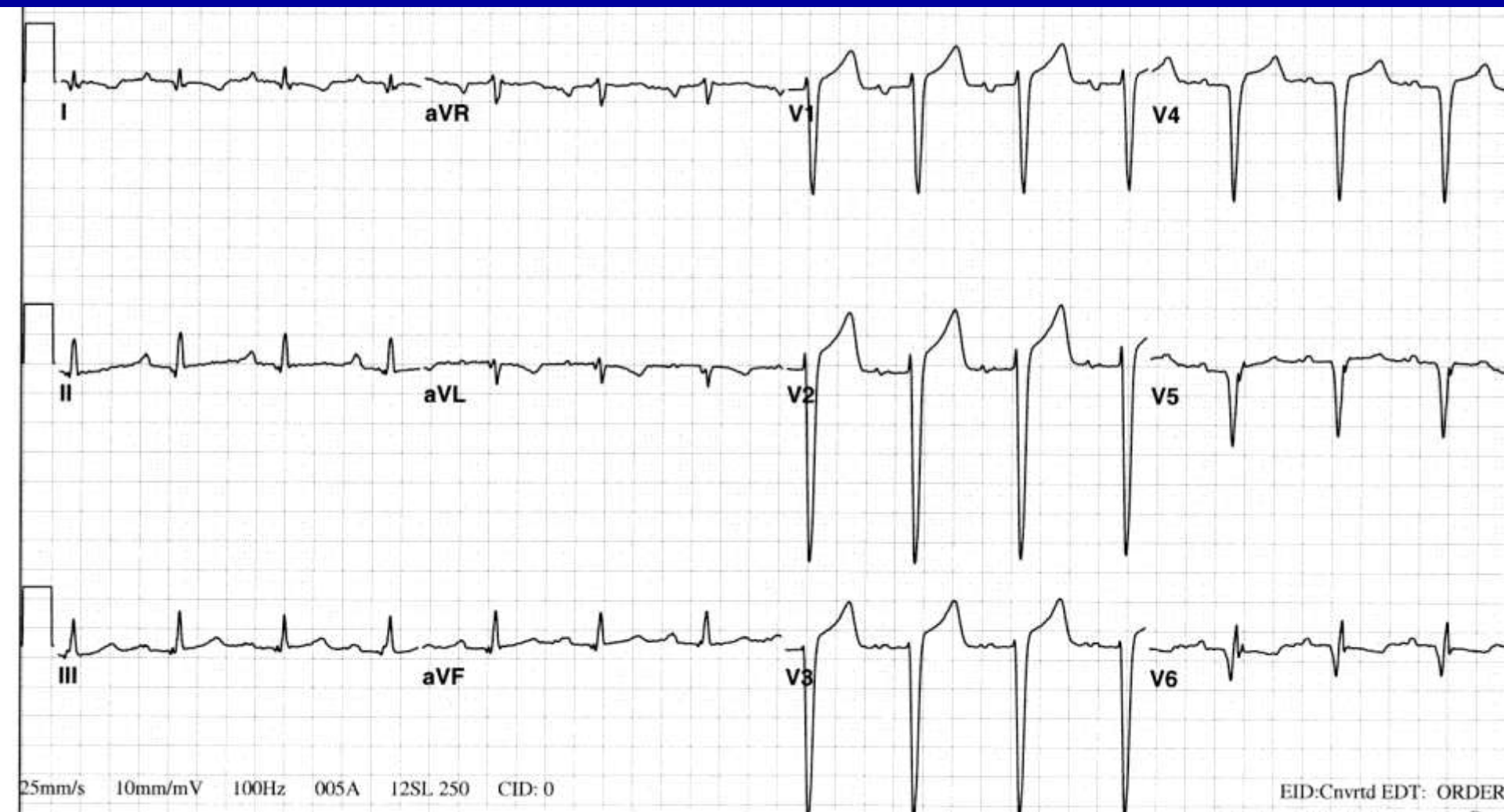1. Ventricular tachycardia
2. Supraventricular tachycardia with rate-related aberrancy
3. Supraventricular tachycardia with IVCD
4. Sinus tachycardia with IVCD
5. Antidromic AVRT

Ventricular Tachycardia



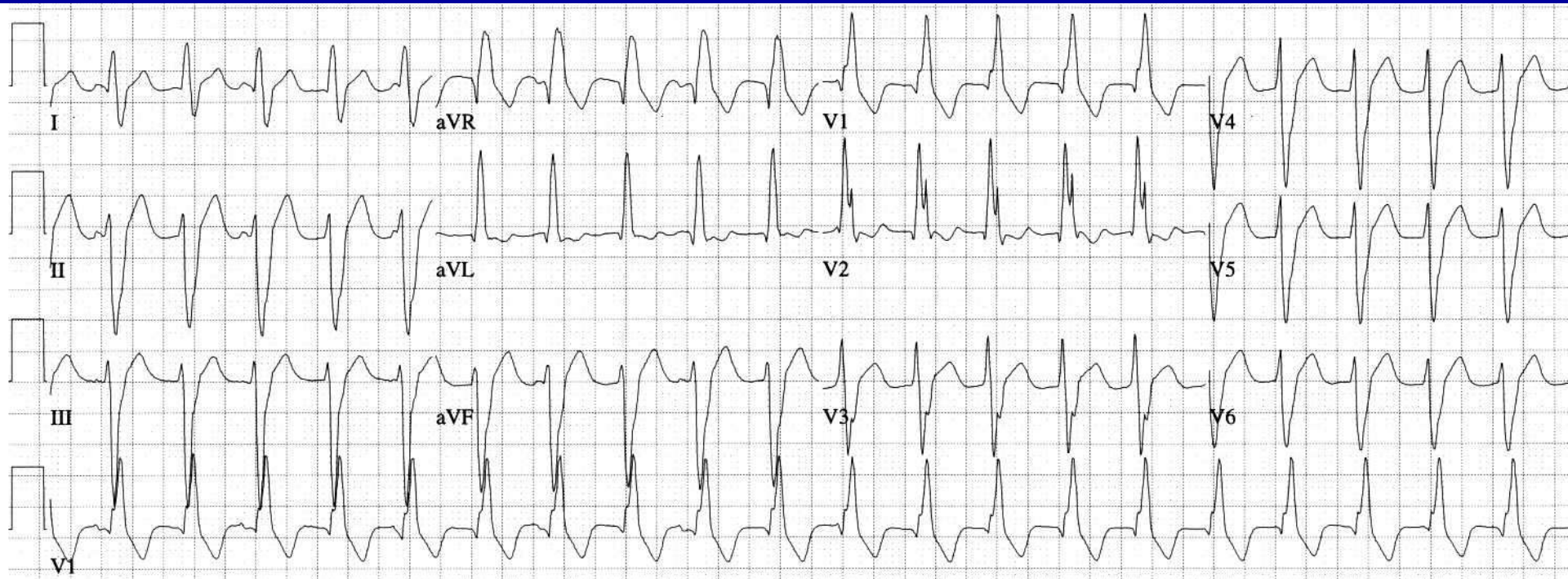
Atrial activity not definitely seen

Baseline ECG

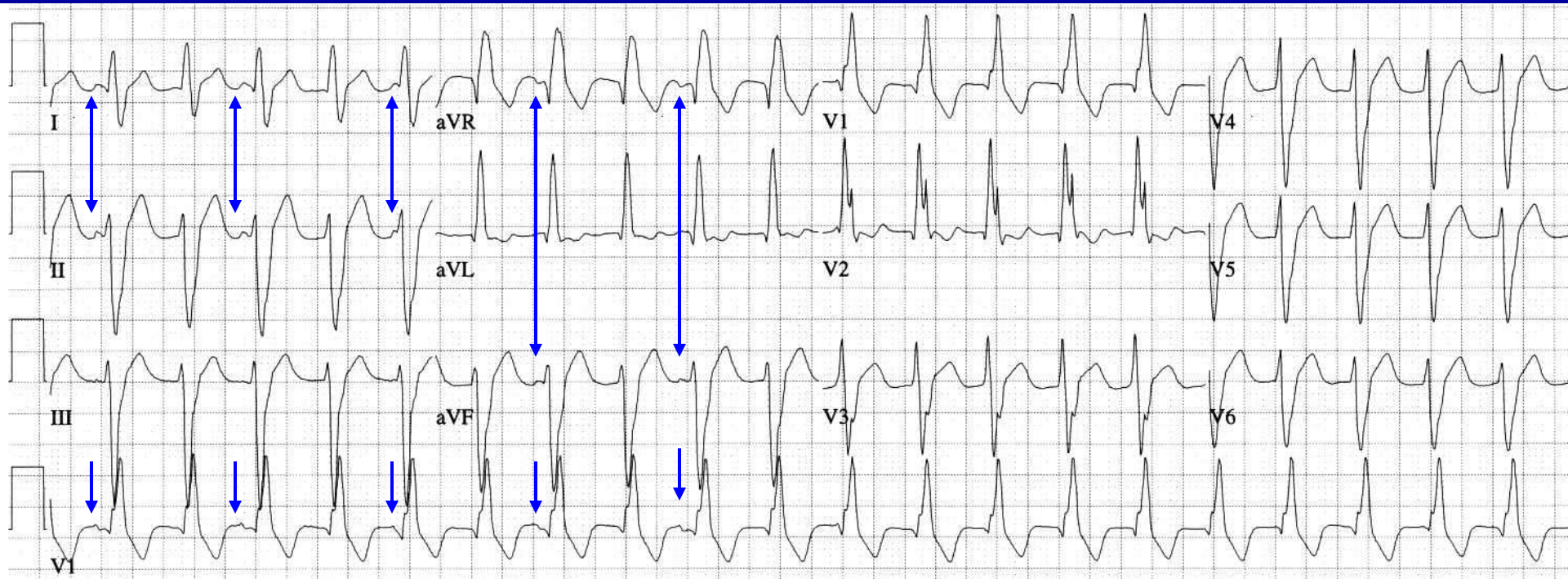


NSR, LAE, large anterolateral MI

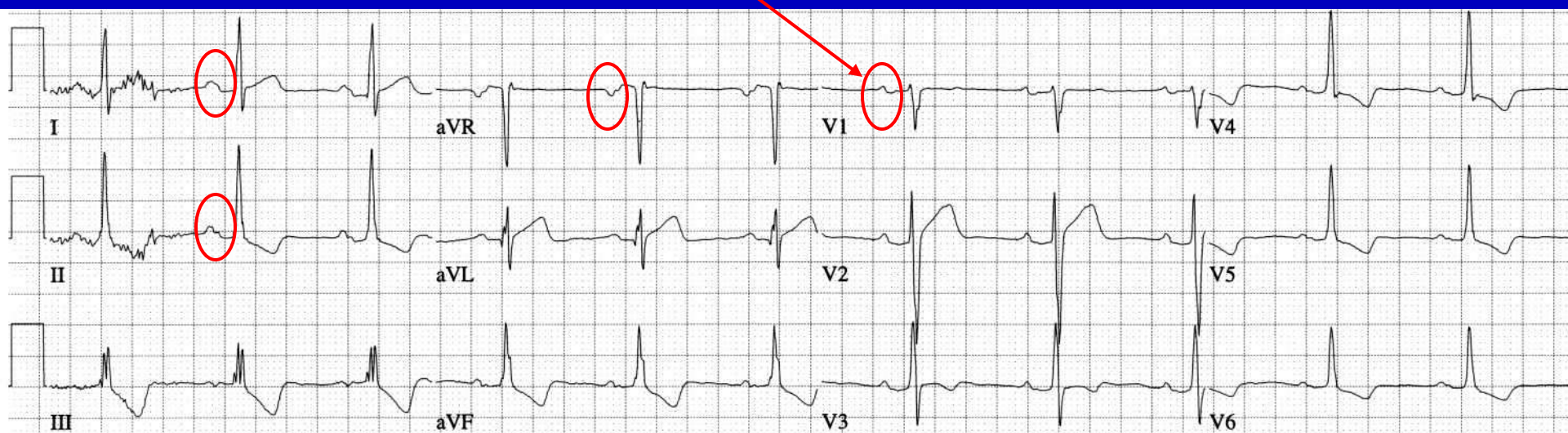
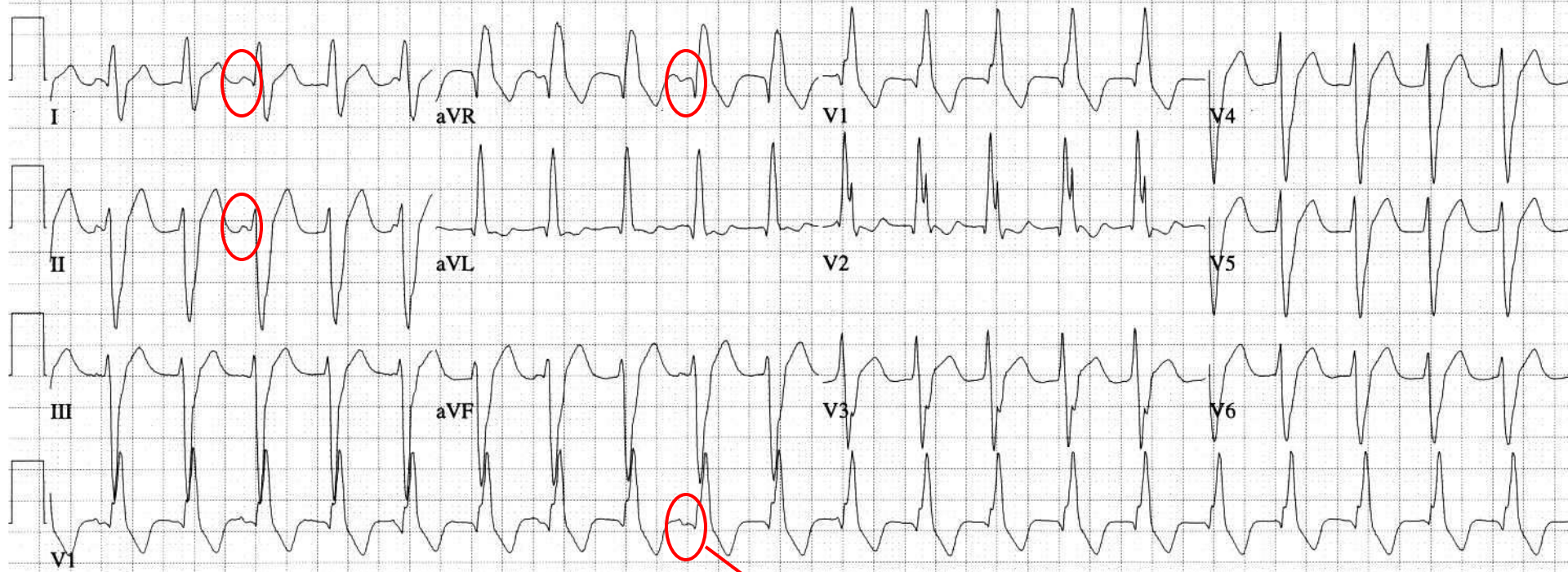
What is the rhythm?



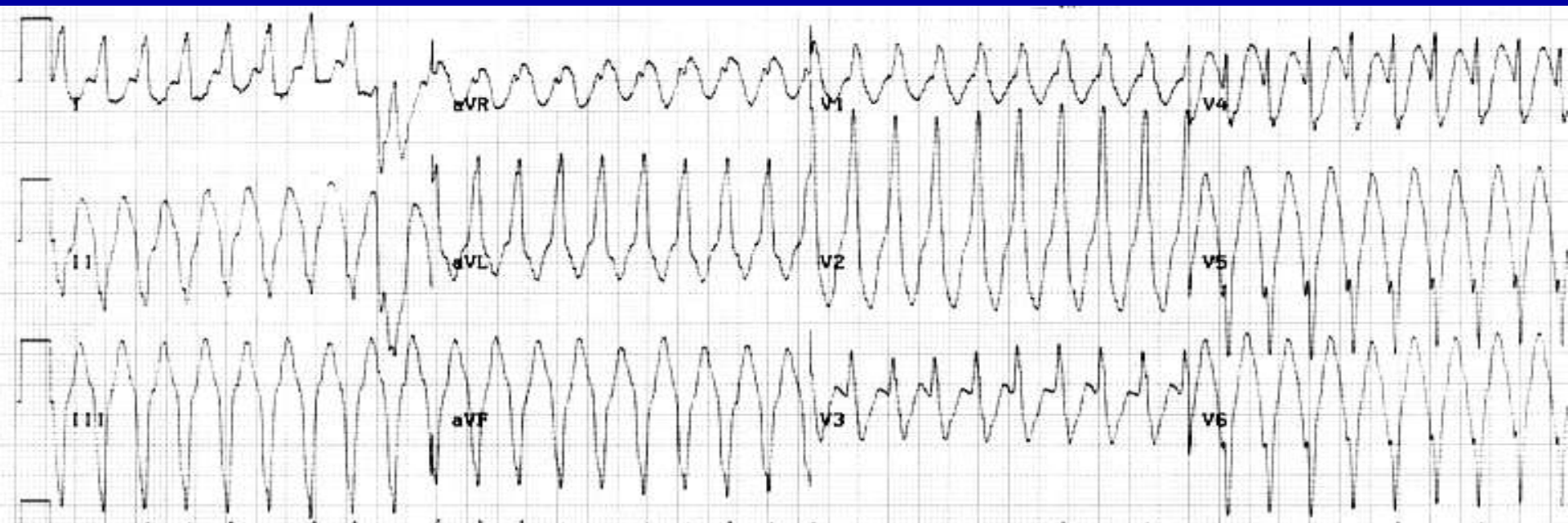
WCT: ventricular tachycardia with sinus rhythm and AV dissociation, but no Dressler beats



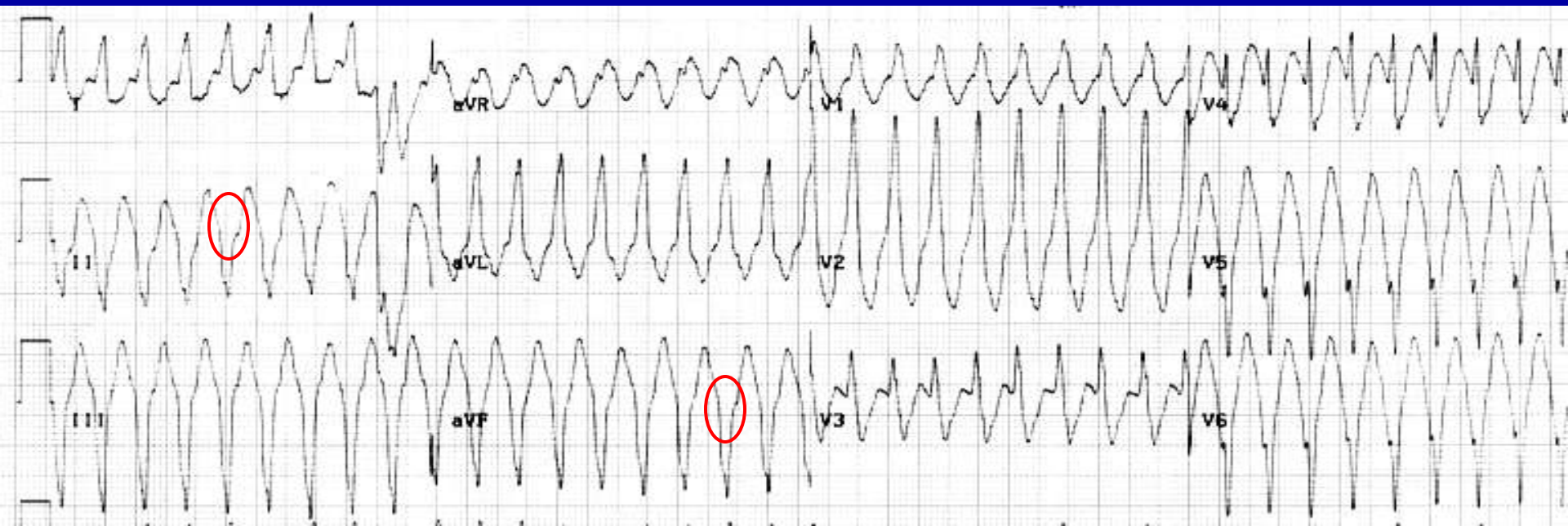
Arrhythmia and baseline ECG



What is the rhythm?

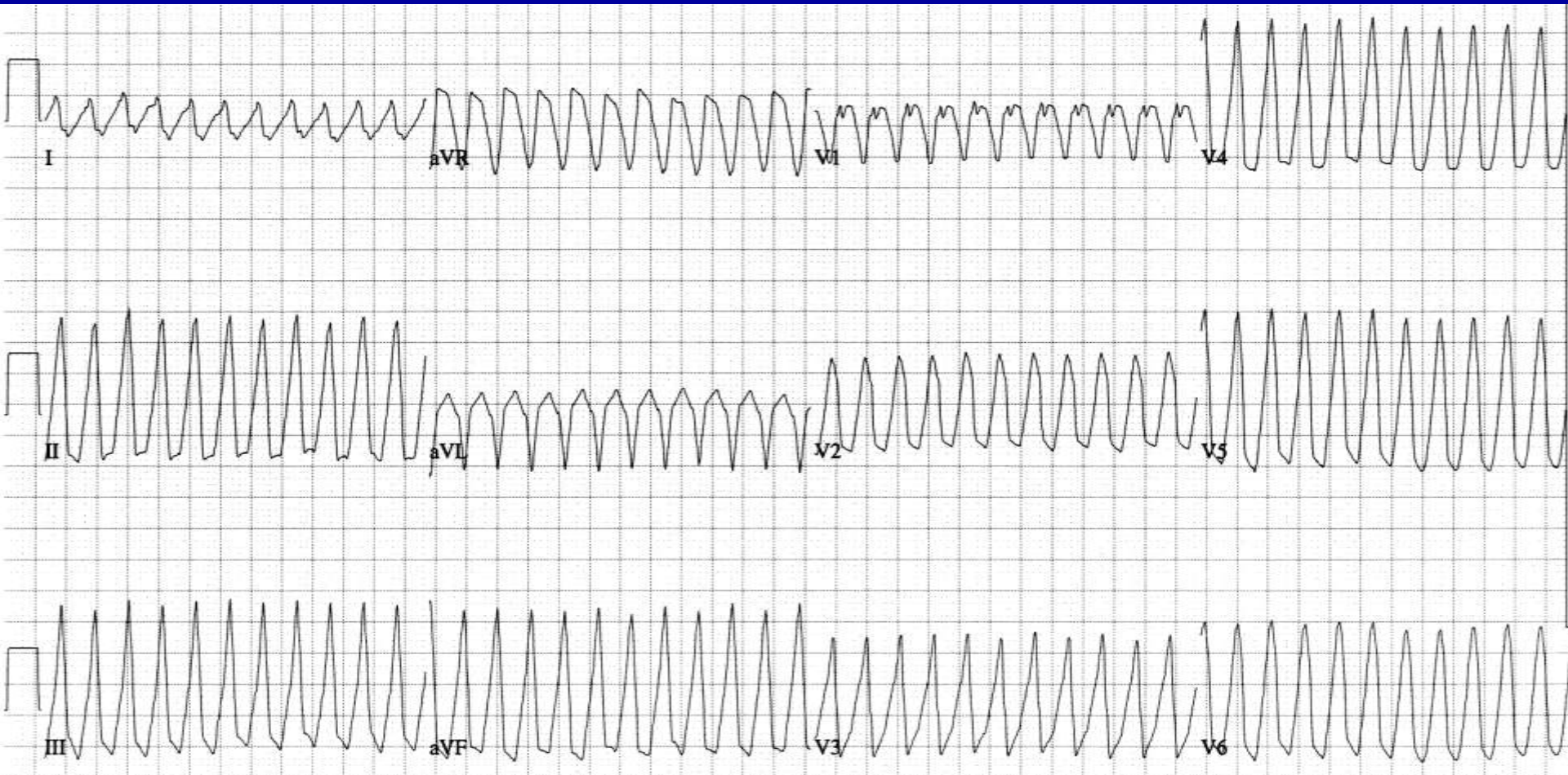


WCT. No baseline tracing, no P waves

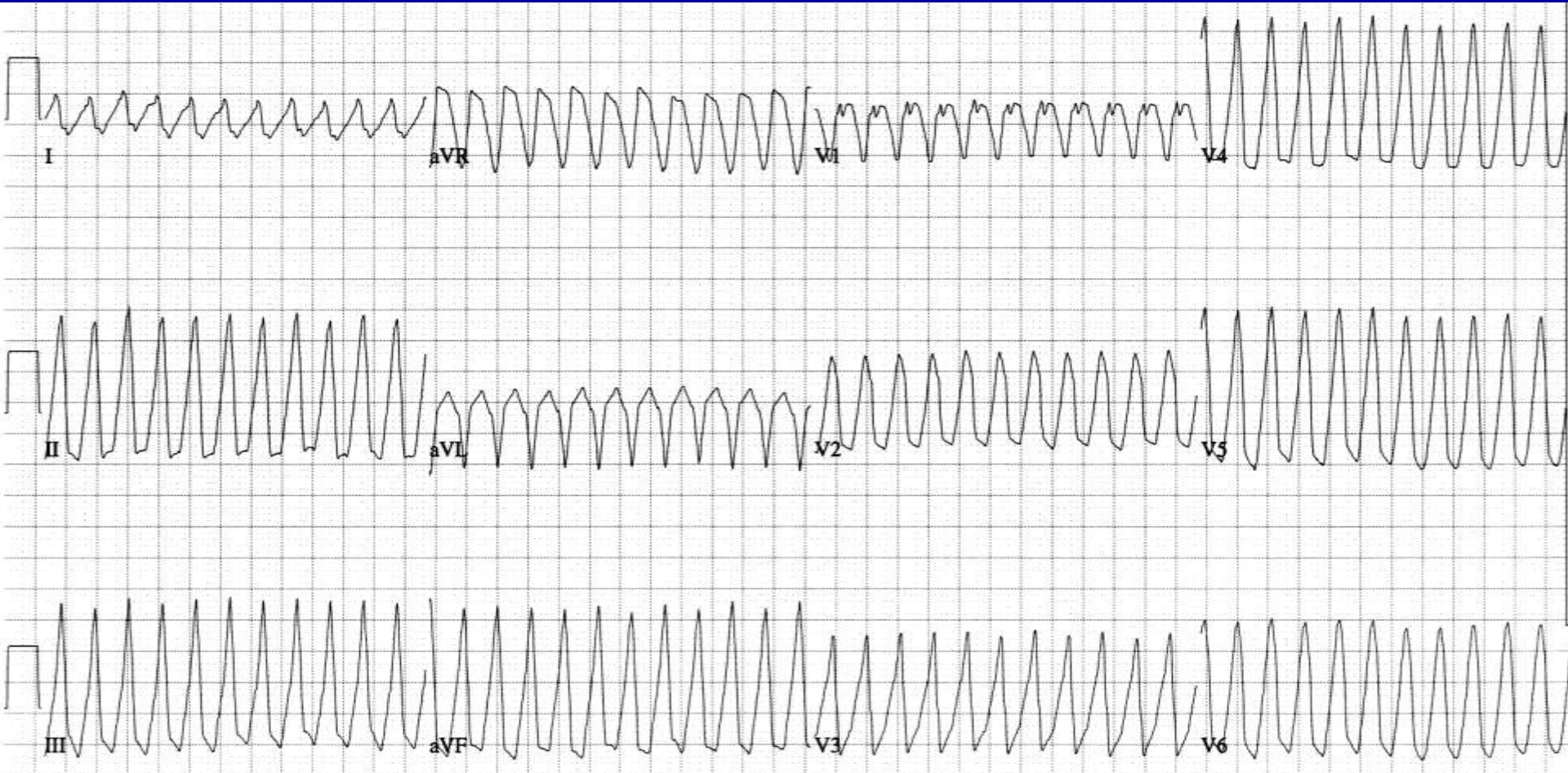


Consider 1:1 retrograde conduction

What is the rhythm?



WCT: No P waves found

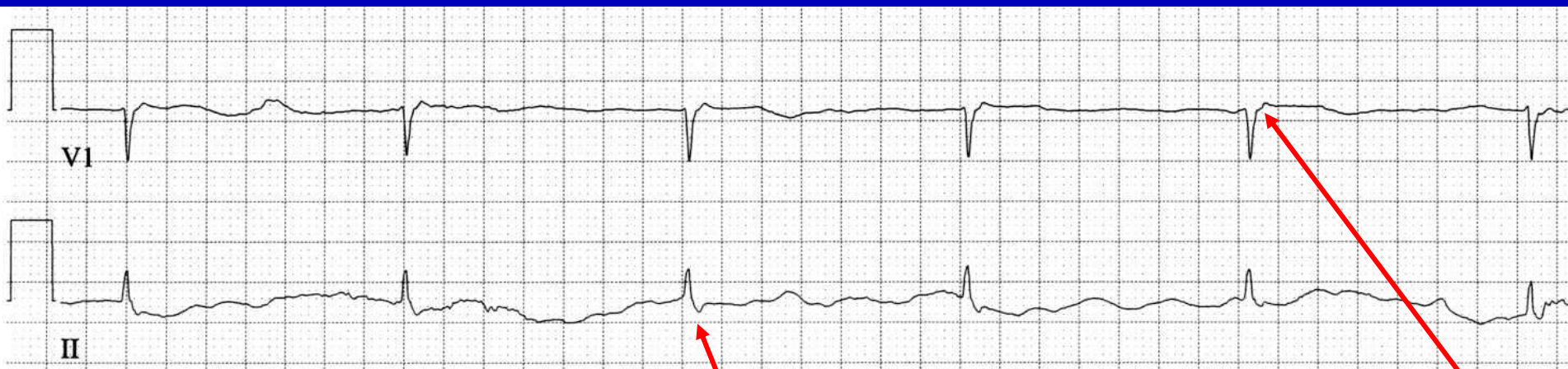
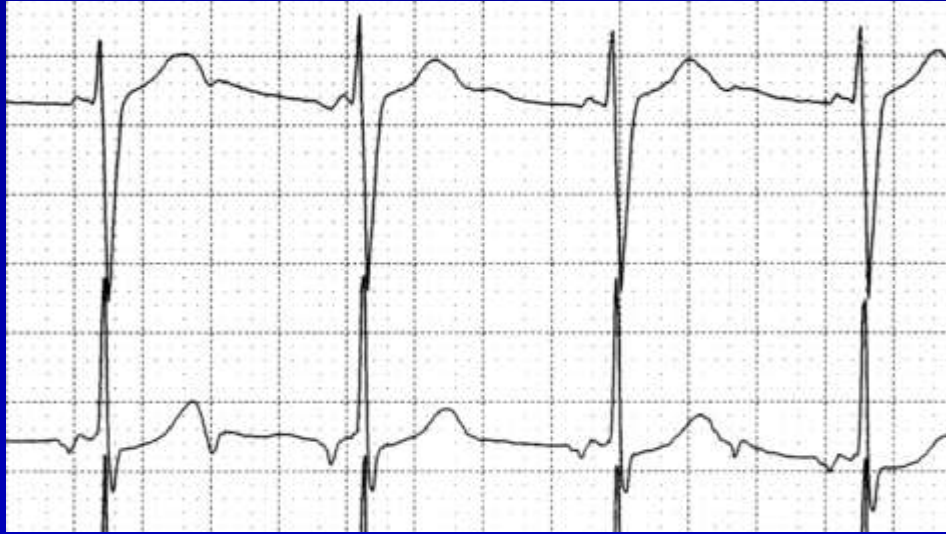
Young adult patient with postoperative cyanotic congenital heart disease, diagnosed as inducible ventricular tachycardia at the second electrophysiologic study

Junctional Rhythms

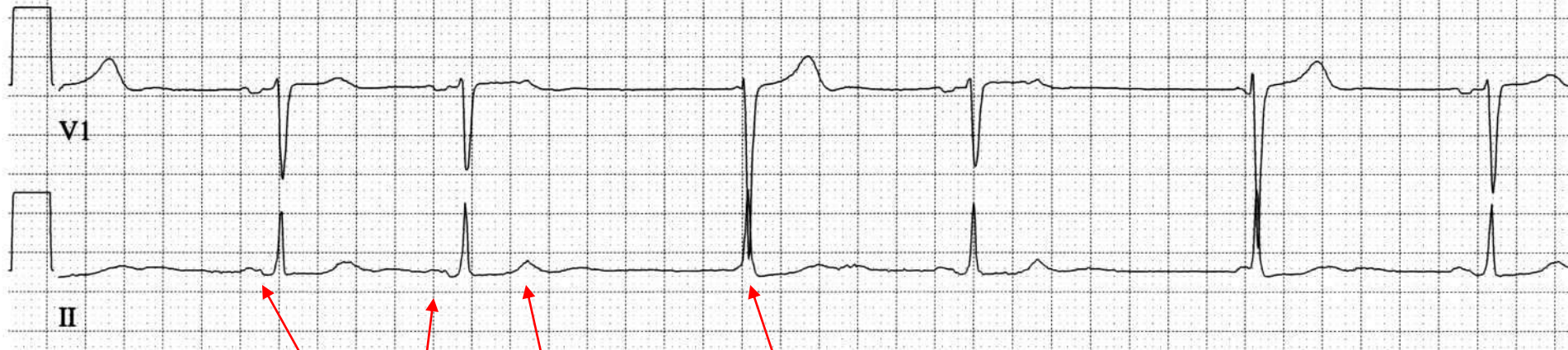Lead V1

Lead II



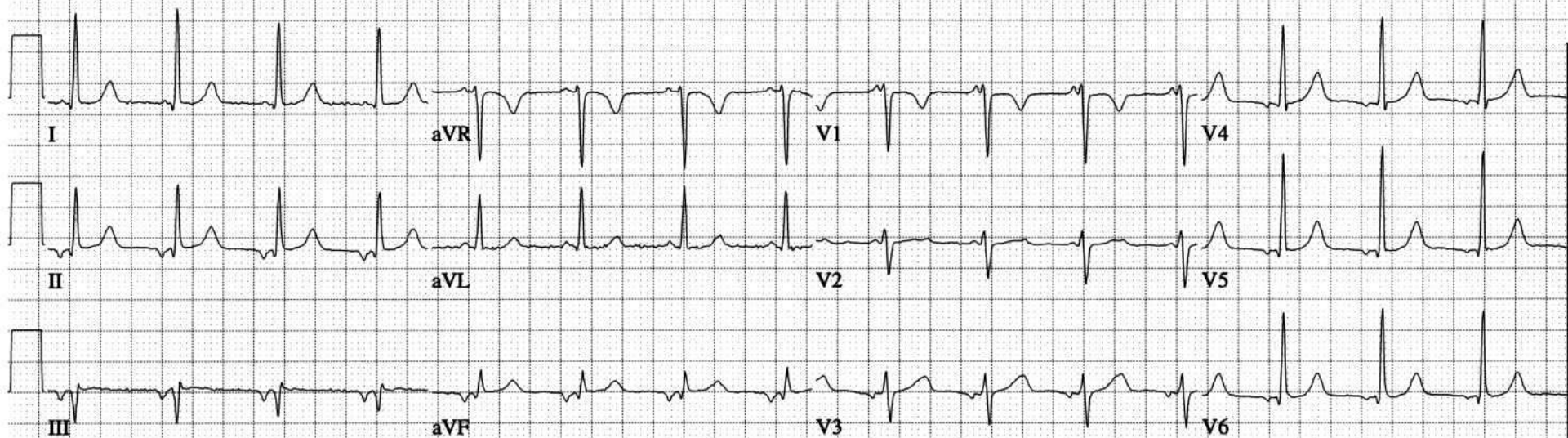
Pseudo R-prime

Junctional Rhythms

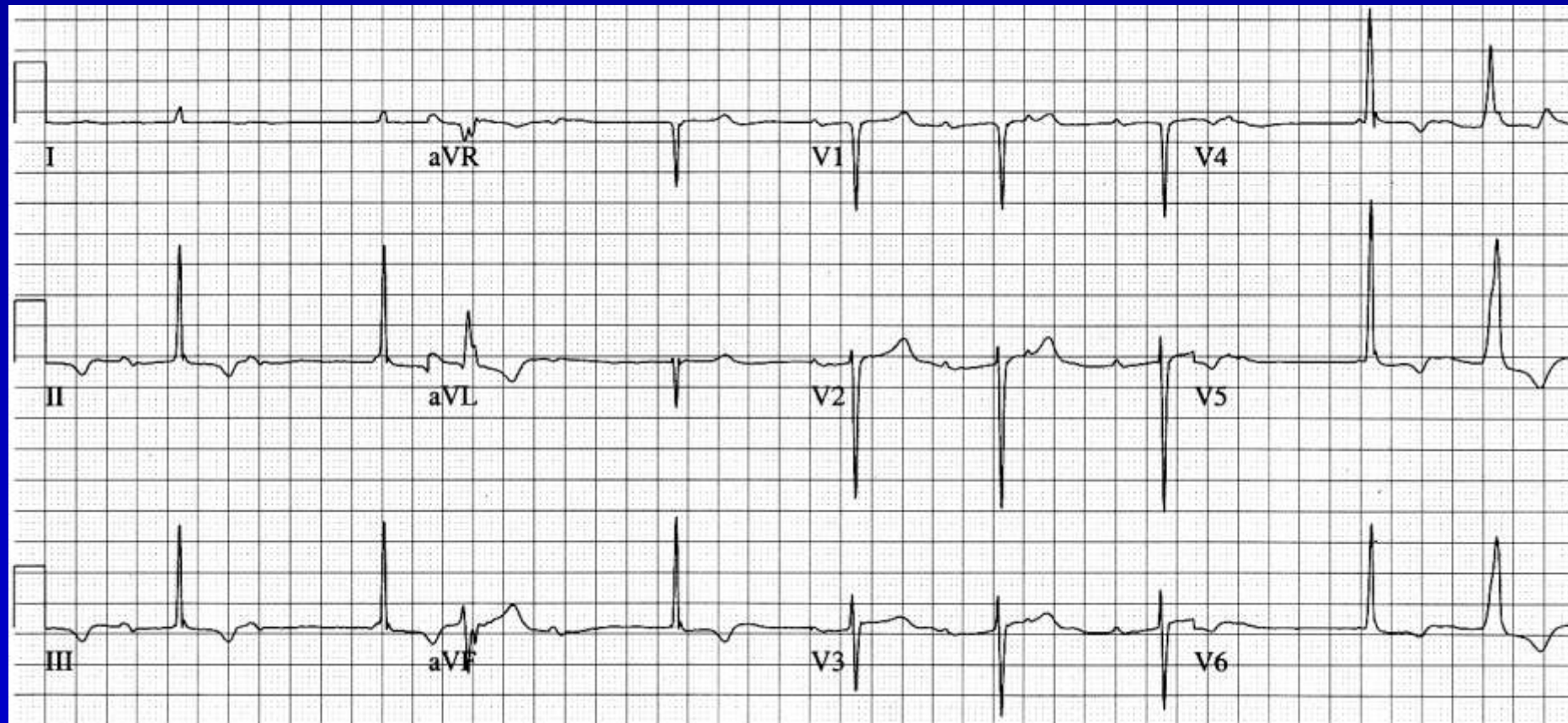


Sinus - NC PAC - Jesc

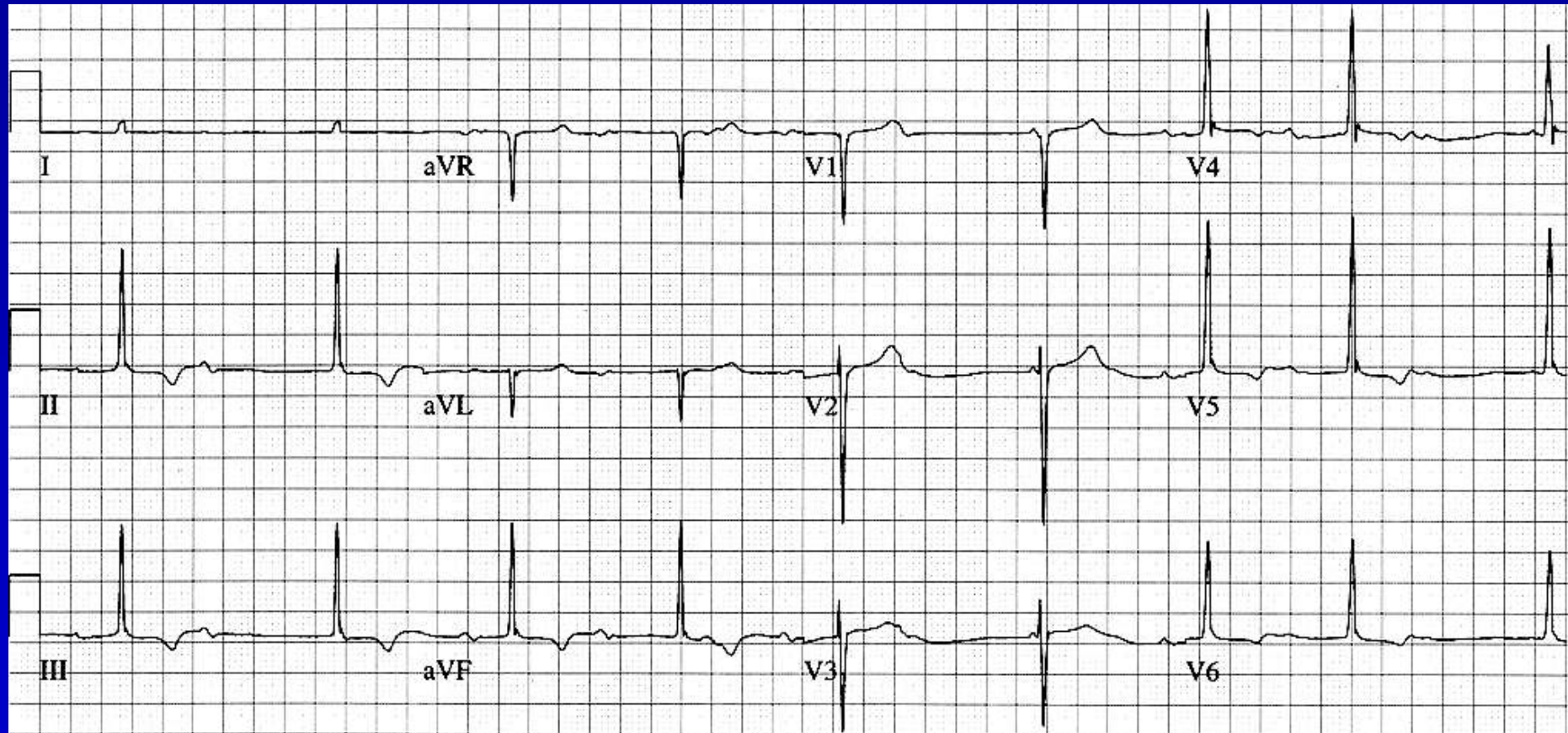
Accelerated Junctional Rhythm



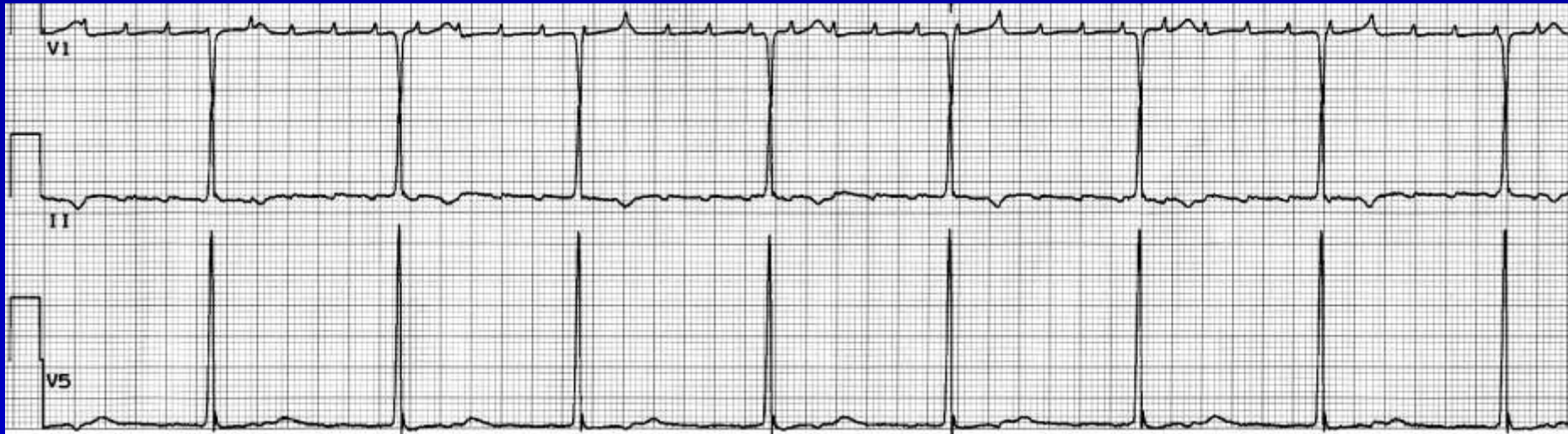
Unknown



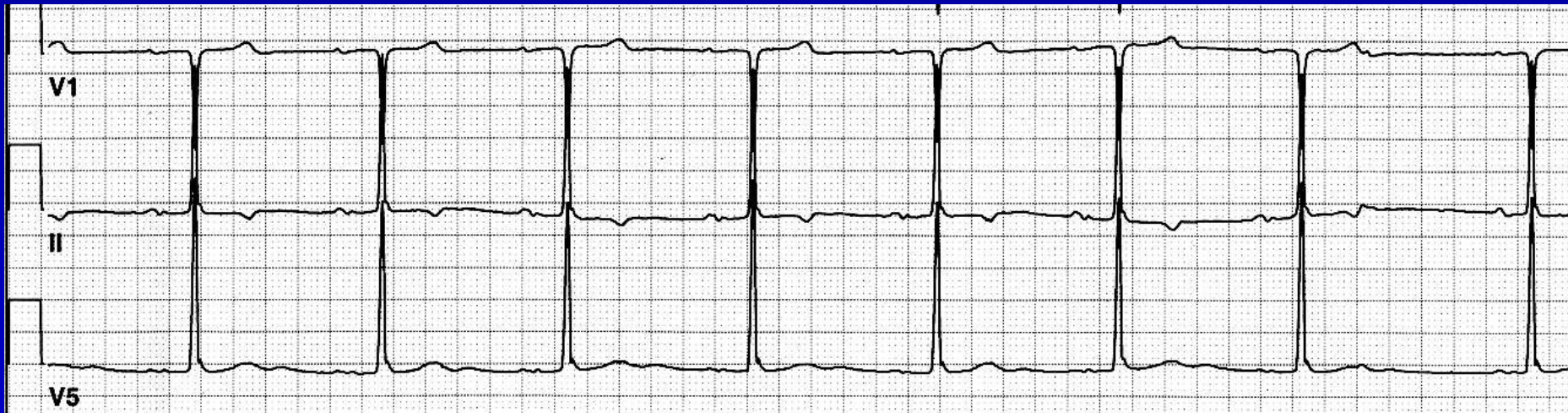
Unknown



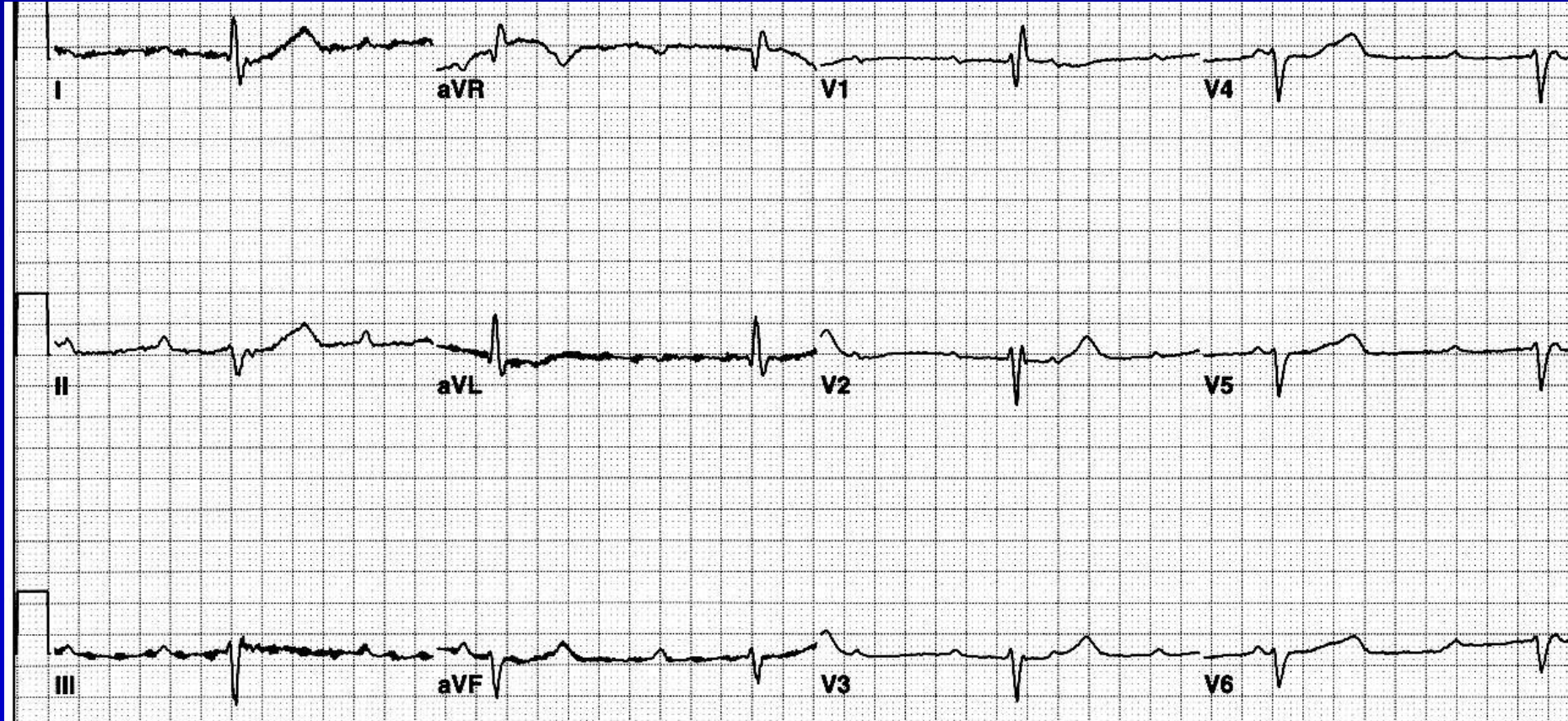
Unknown



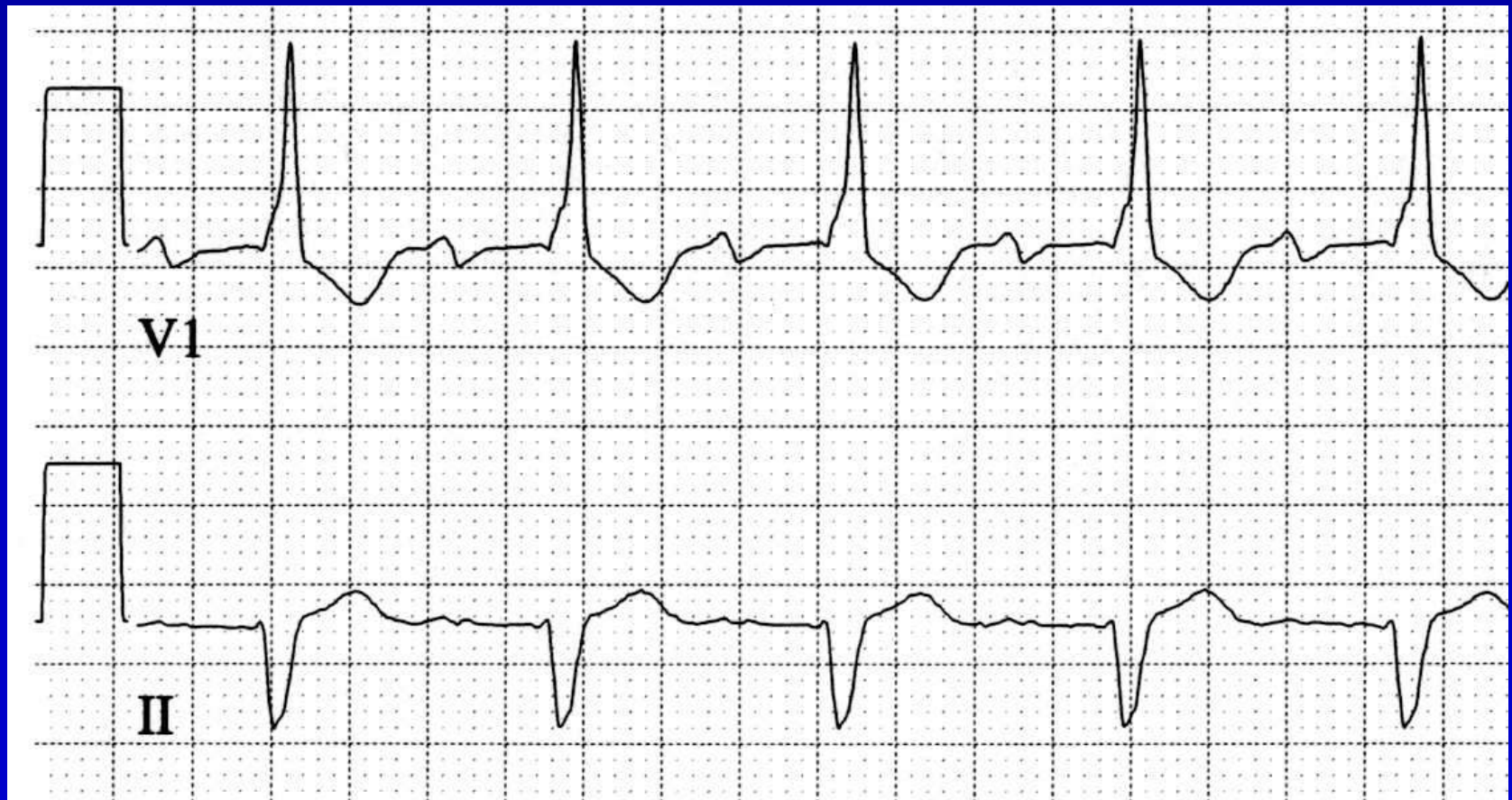Unknown



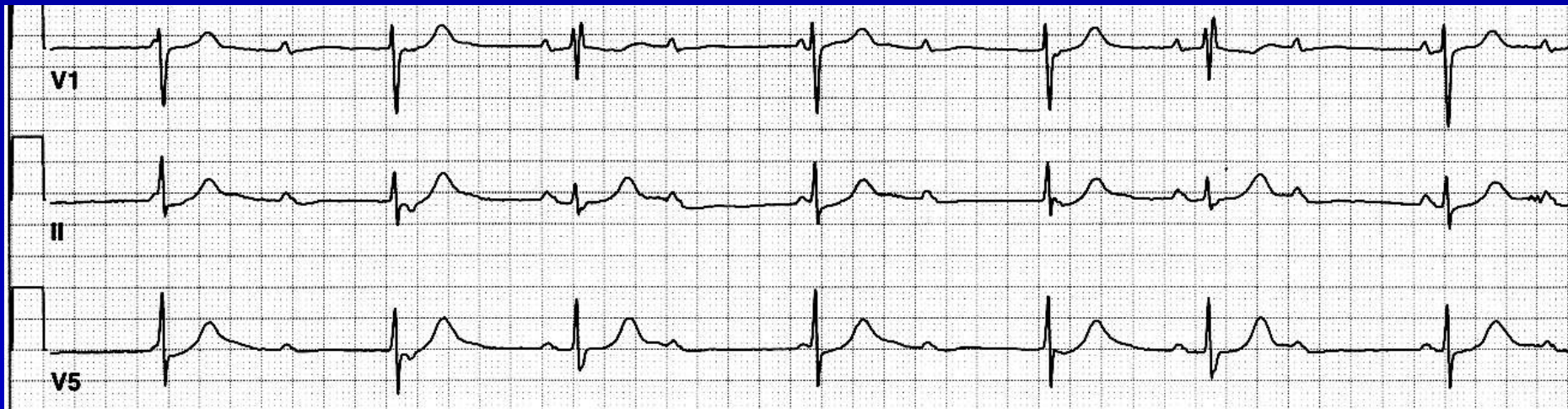
Unknown



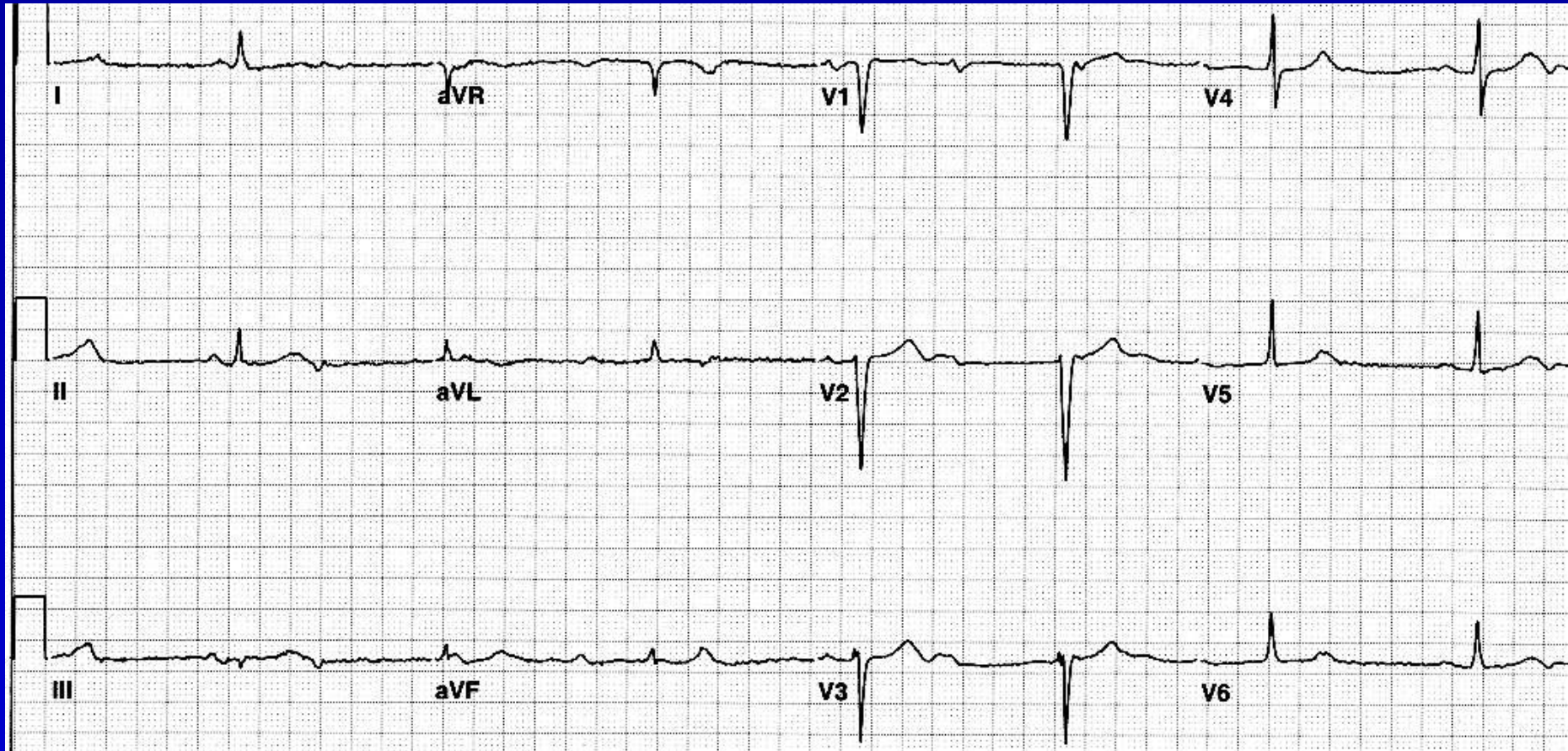
Unknown



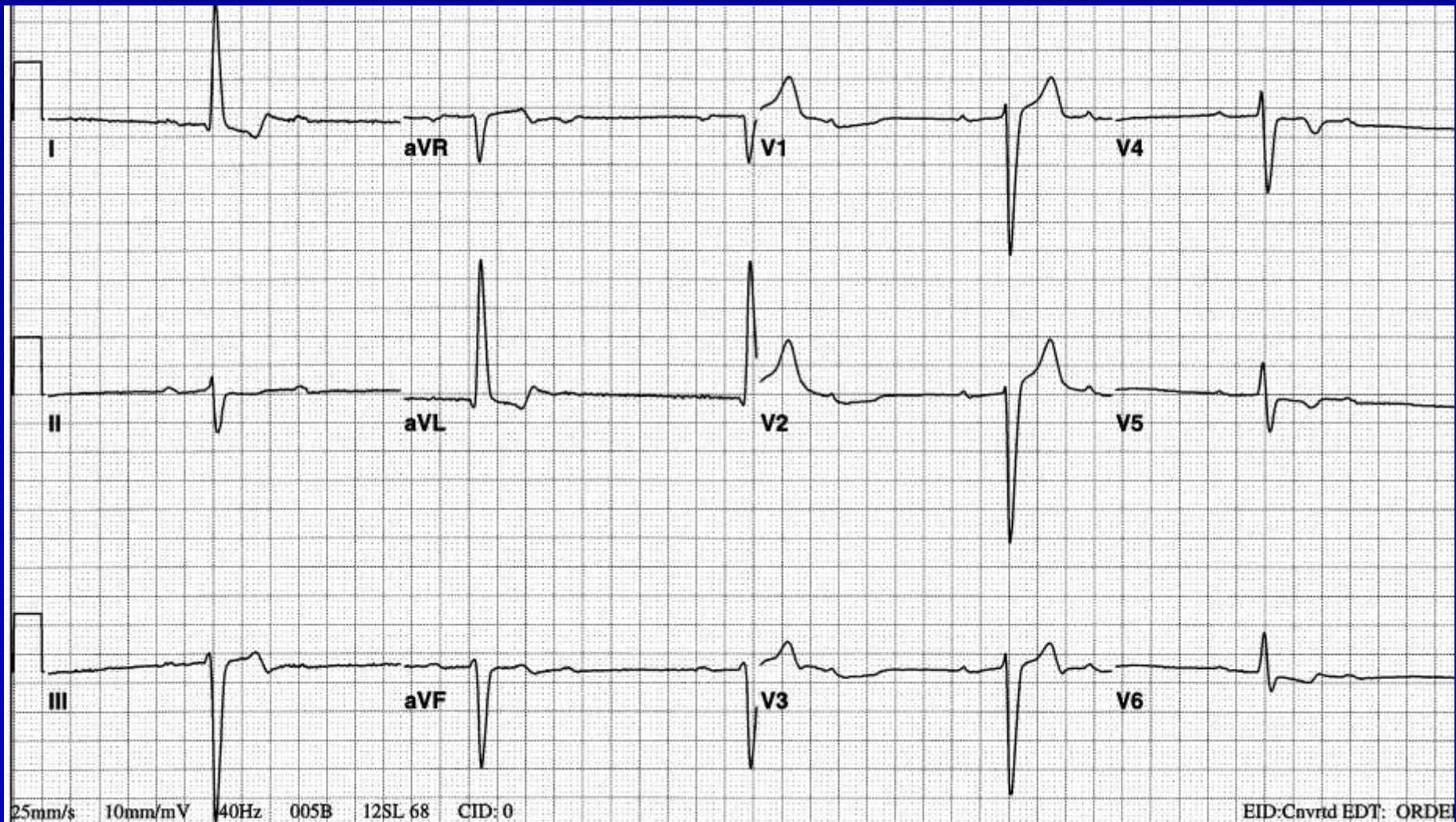
Unknown



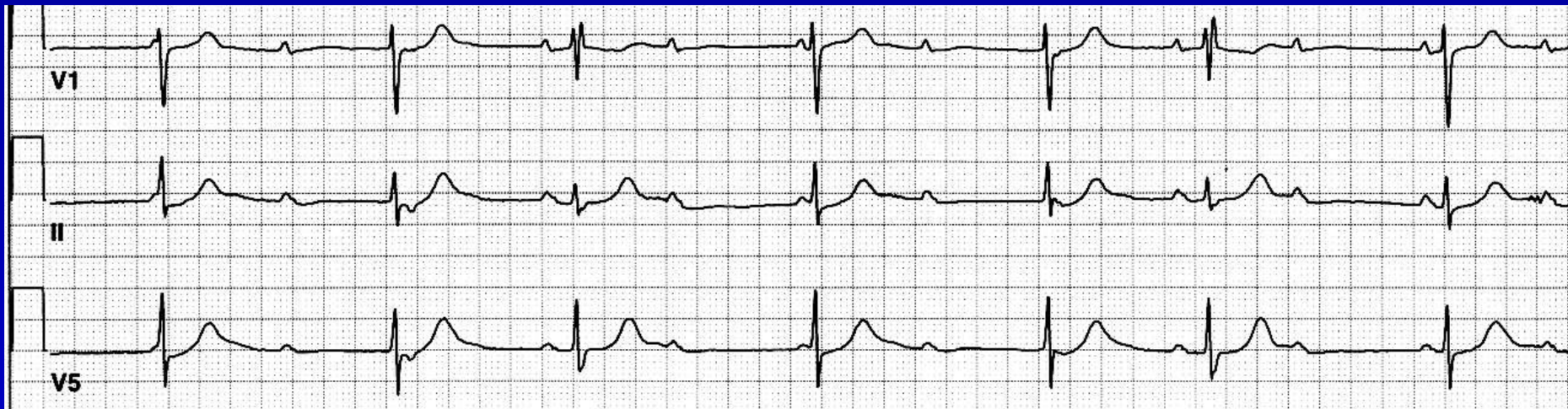Unknown



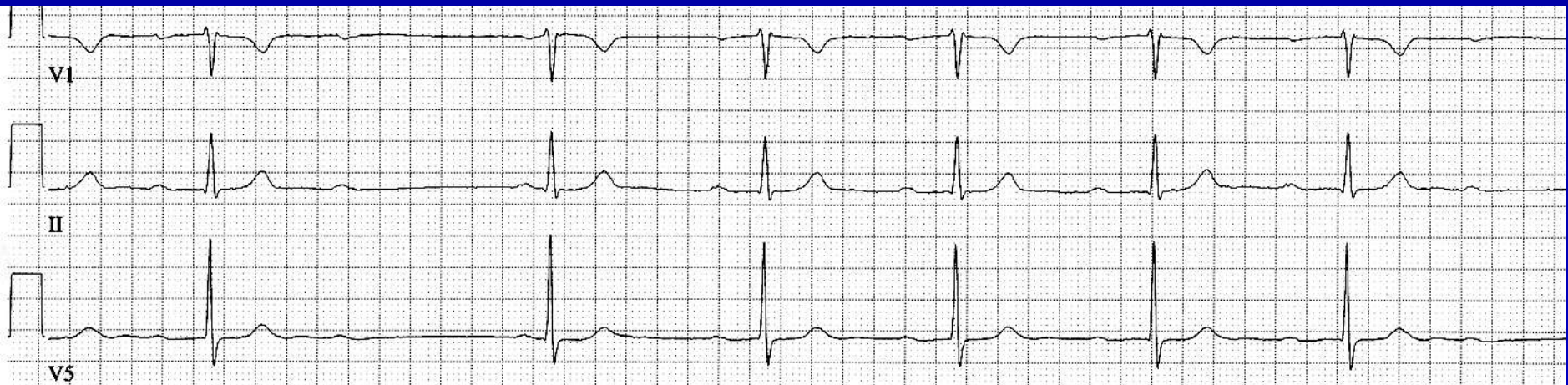Unknown



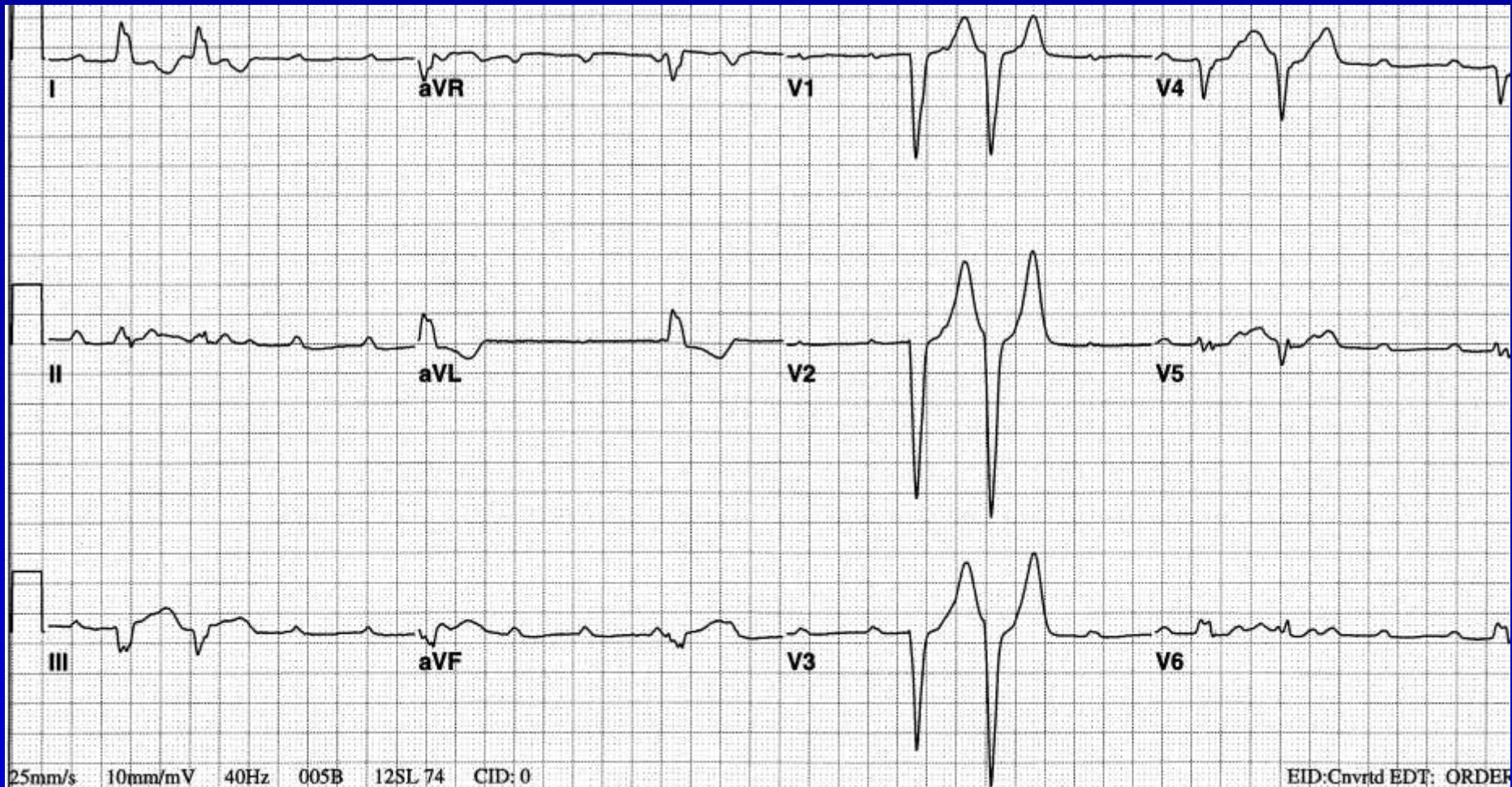
Unknown



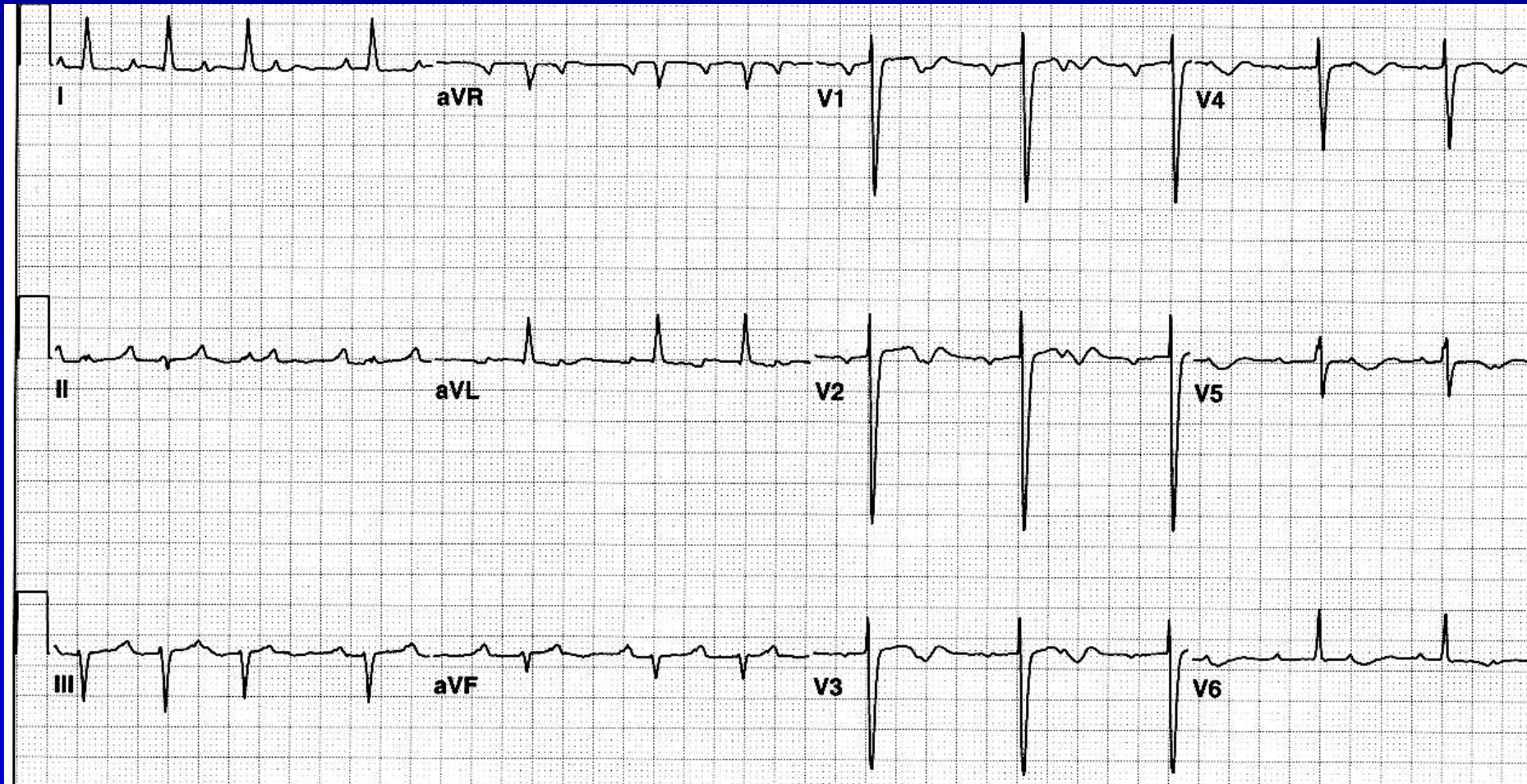
Unknown



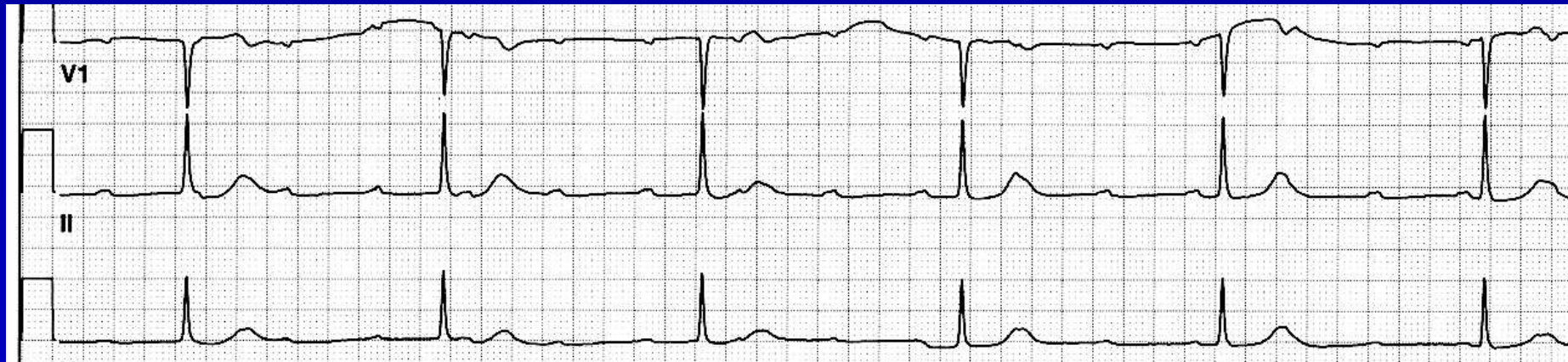
Unknown



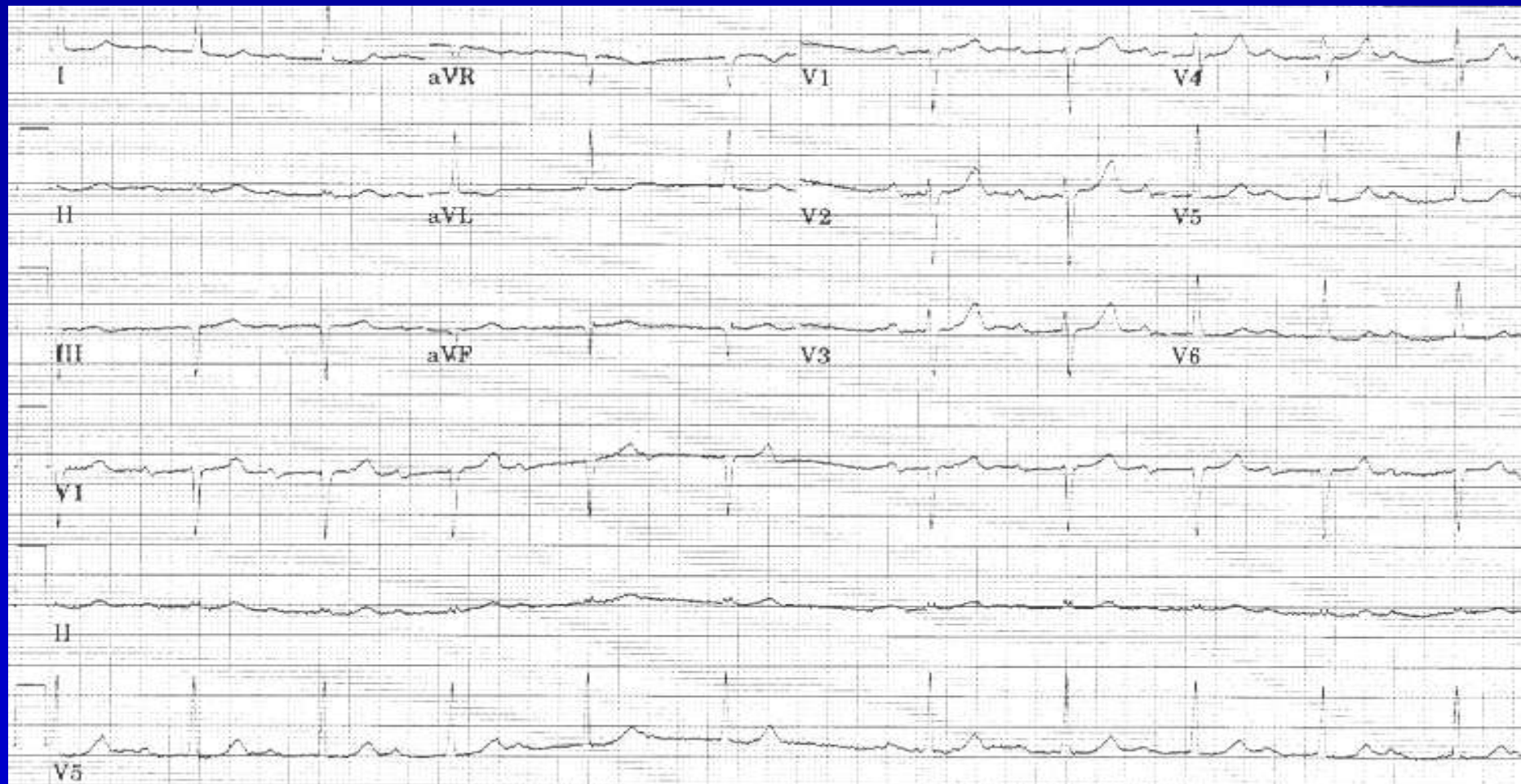Unknown



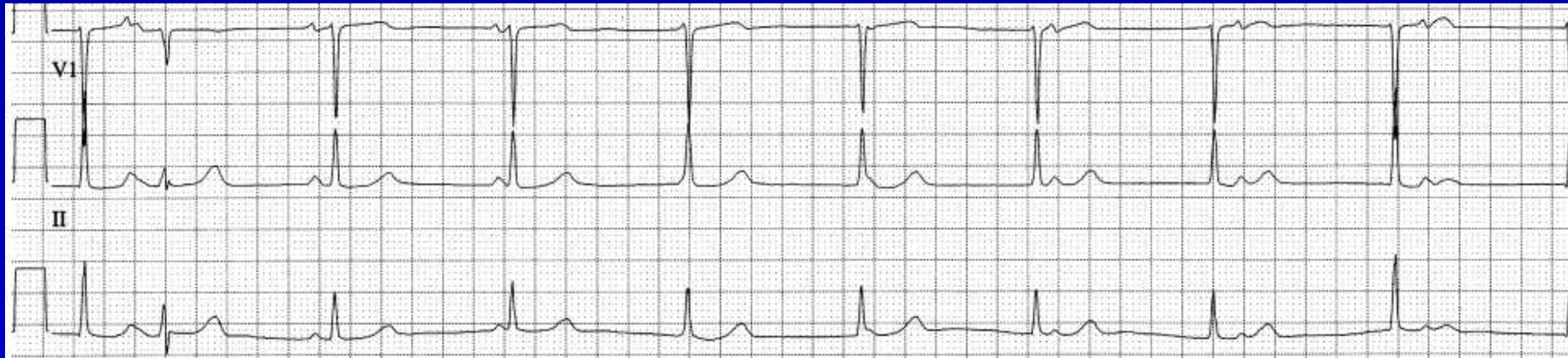Unknown



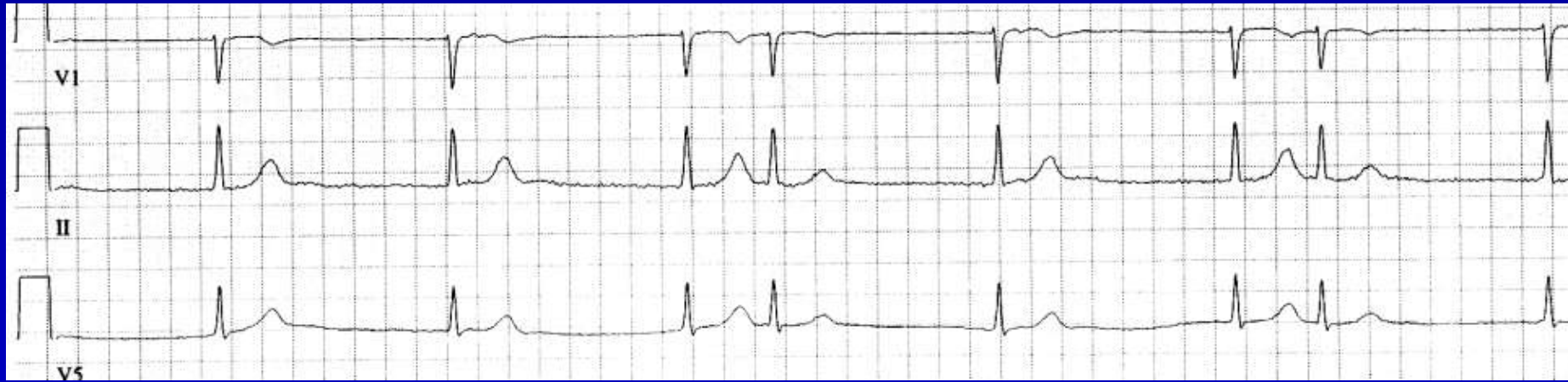
Unknown



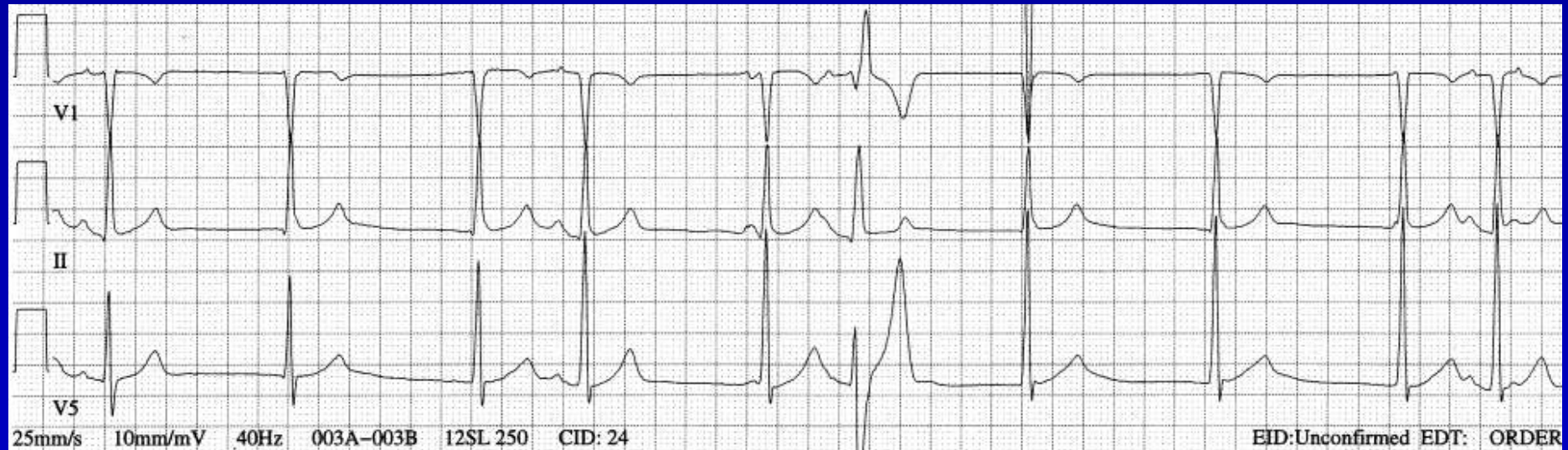
Unknown



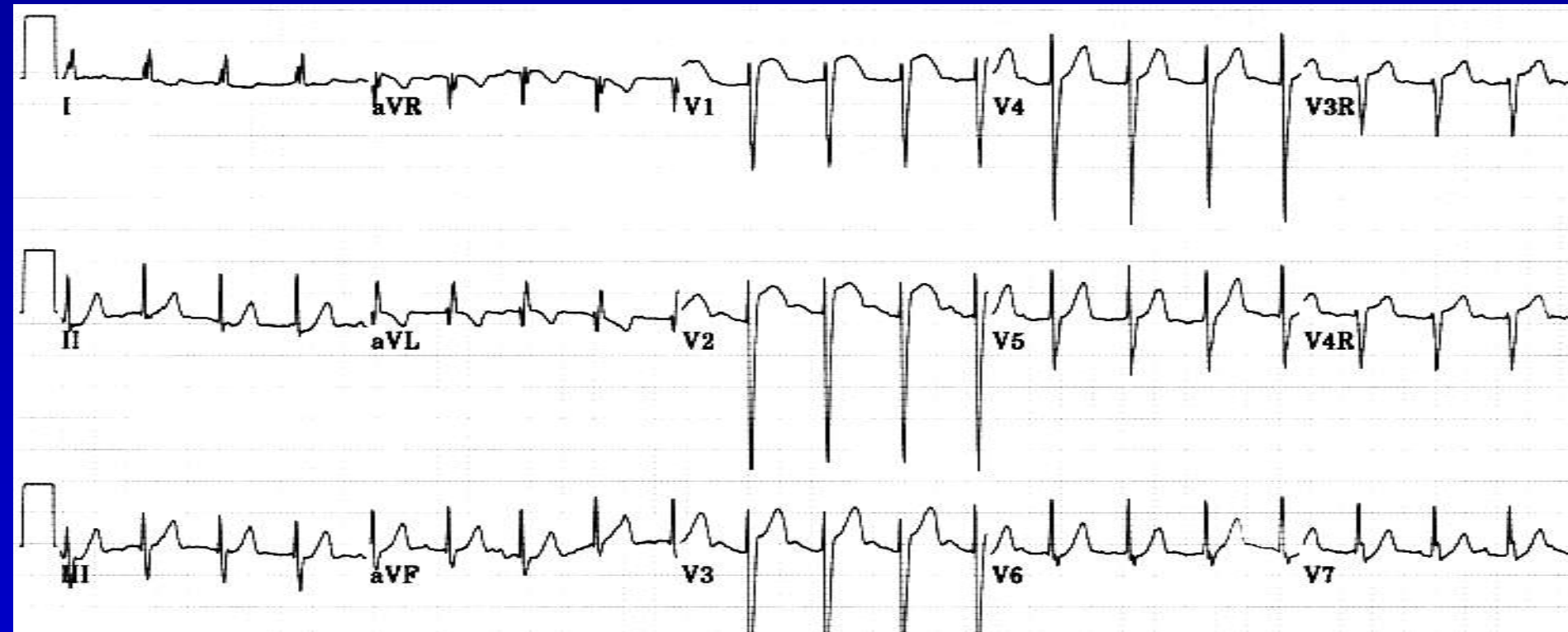
Unknown



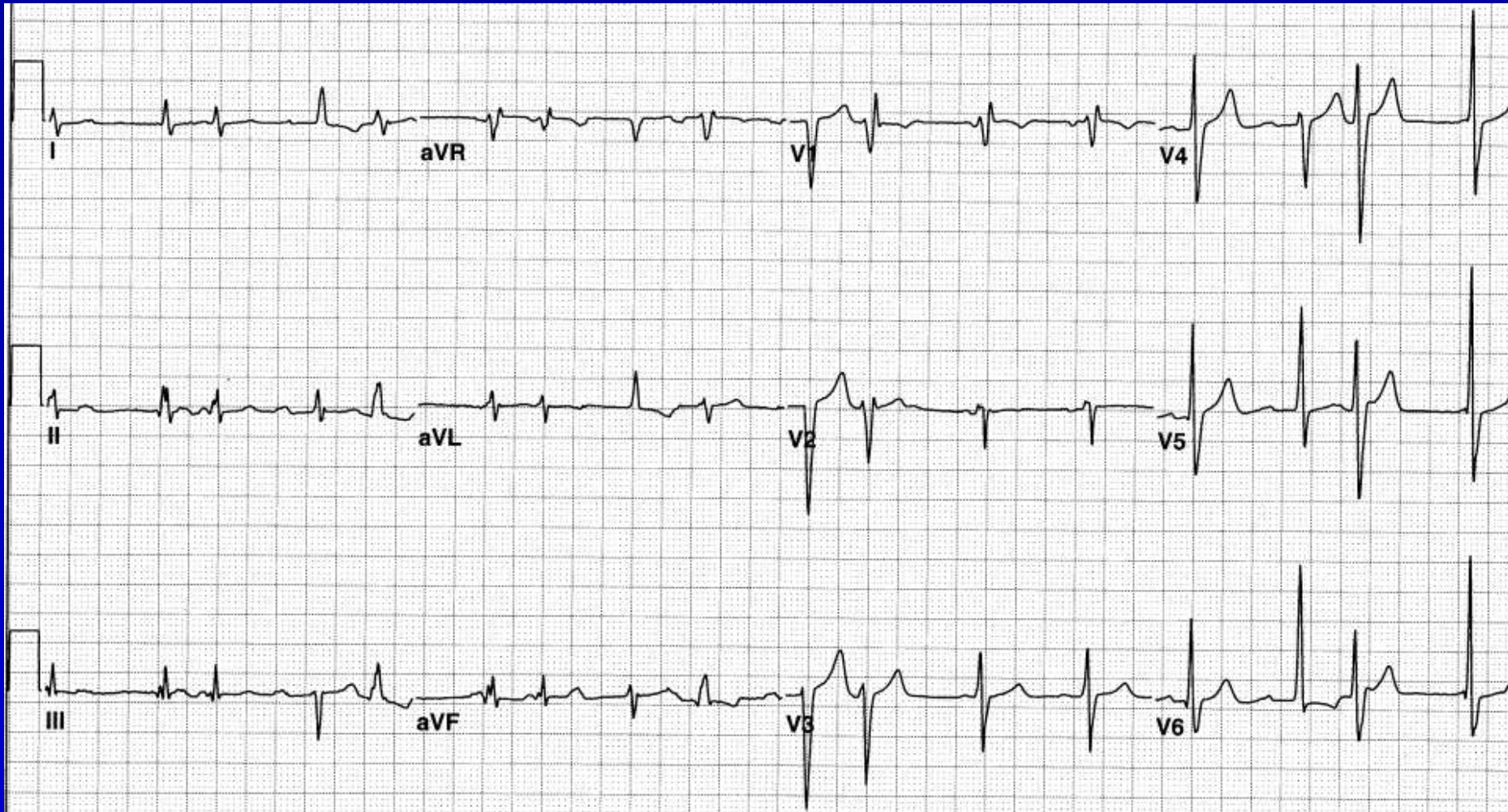
Unknown



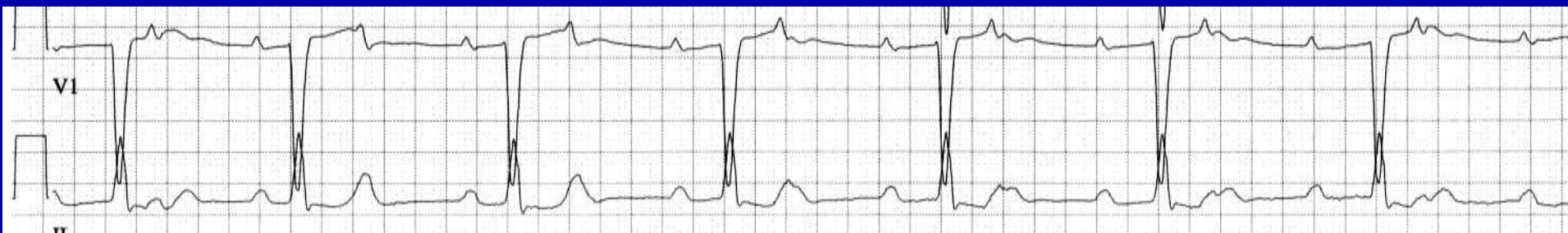Unknown



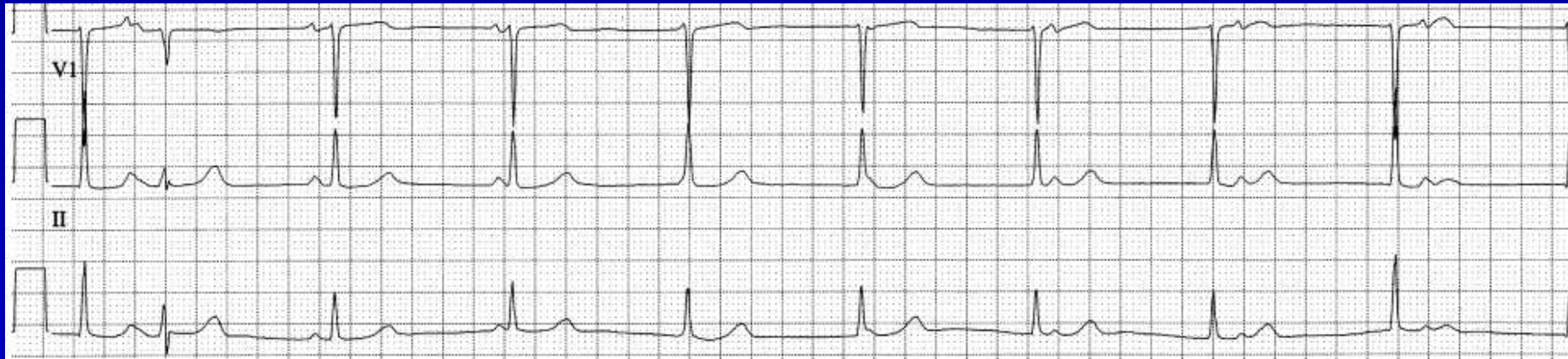Unknown



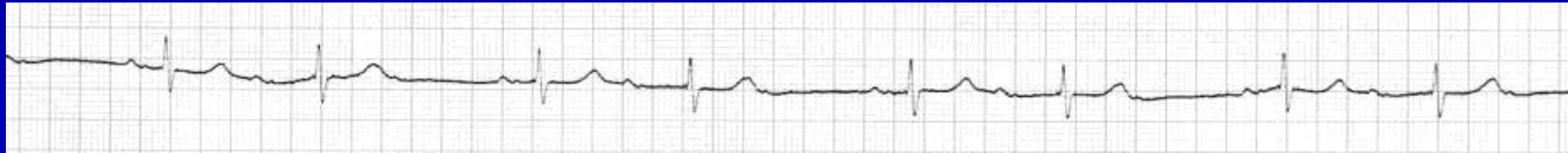
Unknown



Unknown



Unknown



Unknown

